



National Comprehensive  
Cancer Network®

NCCN Clinical Practice Guidelines in Oncology (NCCN Guidelines®)

# Ampullary Adenocarcinoma

Version 2.2024 — August 02, 2024

[NCCN.org](https://www.nccn.org)

**NCCN recognizes the importance of clinical trials and encourages participation when applicable and available.  
Trials should be designed to maximize inclusiveness and broad representative enrollment.**

[Continue](#)



**\*Margaret A. Tempero, MD/Chair † ‡**  
UCSF Helen Diller Family  
Comprehensive Cancer Center

**\*Mokenge P. Malafa, MD/Vice Chair ¶**  
Moffitt Cancer Center

**\*\*E. Gabriela Chiorean, MD/Lead †**  
Fred Hutchinson Cancer Center

**Marco Del Chiaro, MD, PhD/Co-Lead ¶**  
University of Colorado Cancer Center

**\*\*Al B. Benson III, MD †**  
Robert H. Lurie Comprehensive Cancer  
Center of Northwestern University

**Dana B. Cardin, MD †**  
Vanderbilt-Ingram Cancer Center

**Jared A. Christensen, MD ϕ**  
University of Michigan Rogel Cancer Center

**Vincent Chung, MD †**  
City of Hope National Medical Center

**\*\*Brian Czito, MD §**  
Duke Cancer Institute

**Mary Dillhoff, MD, MS ¶**  
The Ohio State University Comprehensive  
Cancer Center - James Cancer Hospital  
and Solove Research Institute

**Timothy R. Donahue, MD ¶**  
UCLA Jonsson Comprehensive Cancer Center

**Efrat Dotan, MD †**  
Fox Chase Cancer Center

**Christos Fountzilas, MD ‡ †**  
Roswell Park Comprehensive Cancer Center

**Evan S. Glazer, MD, PhD ¶**  
The University of Tennessee  
Health Science Center

**Jeffrey Hardacre, MD ¶**  
Case Comprehensive Cancer Center/  
University Hospitals Seidman Cancer Center  
and Cleveland Clinic Taussig Cancer Institute

**William G. Hawkins, MD ¶**  
Siteman Cancer Center at Barnes-Jewish Hospital  
and Washington University School of Medicine

**Kelsey Klute, MD †**  
Fred & Pamela Buffett Cancer Center

**Andrew H. Ko, MD †**  
UCSF Helen Diller Family  
Comprehensive Cancer Center

**John W. Kunstman, MD, MHS ¶**  
Yale Cancer Center/Smilow Cancer Hospital

**\*\*Noelle LoConte, MD †**  
University of Wisconsin Carbone Cancer Center

**\*\*Andrew M. Lowy, MD ¶**  
UC San Diego Moores Cancer Center

**Ashiq Masood, MD ‡**  
Indiana University Melvin and Bren Simon  
Comprehensive Cancer Center

**Cassadie Moravek, BS ¥**  
Pancreatic Cancer Action Network

**Eric K. Nakakura, MD ¶**  
UCSF Helen Diller Family  
Comprehensive Cancer Center

**Amol K. Narang, MD §**  
The Sidney Kimmel Comprehensive  
Cancer Center at Johns Hopkins

**Lorenzo Nardo, MD, PhD ϕ ϕ**  
UC Davis Comprehensive Cancer Center

**\*\*Jorge Obando, MD □**  
Duke Cancer Institute

**Patricio M. Polanco, MD ¶**  
UT Southwestern Simmons  
Comprehensive Cancer Center

**Sushanth Reddy, MD ¶**  
O'Neal Comprehensive Cancer Center at UAB

**Marsha Reingold, MD, PhD §**  
Memorial Sloan Kettering Cancer Center

**Courtney Scaife, MD ¶**  
Huntsman Cancer Institute  
at the University of Utah

**\*\*Jeanne Shen, MD ≠**  
Stanford Cancer Institute

**Ardaman Shergill, MD †**  
The UChicago Medicine Comprehensive Cancer  
Center

**Mark J. Truty, MD, MS ¶**  
Mayo Clinic Comprehensive Cancer Center

**Charles Vollmer Jr., MD ¶**  
Abramson Cancer Center at the  
University of Pennsylvania

**Robert A. Wolff, MD □ †**  
The University of Texas  
MD Anderson Cancer Center

**Brian M. Wolpin, MD, MPH †**  
Dana-Farber/Brigham and Women's  
Cancer Center

### NCCN

**Ajibola Awotiwon, MBBS, MSC**  
**Susan Darlow, PhD**  
**Beth McCullough RN, BS**  
**Swathi Ramakrishnan, PhD**

ϕ Diagnostic/Interventional radiology	¥ Patient advocacy
□ Gastroenterology	§ Radiotherapy/Radiation oncology
‡ Hematology/Hematology oncology	¶ Surgery/Surgical oncology
† Medical oncology	* Discussion section writing committee
ϕ Nuclear medicine	** Development/writing subcommittee
≠ Pathology	



[Ampullary Adenocarcinoma Panel Members](#)  
[Summary of the Guidelines Updates](#)

[Clinical Suspicion of Ampullary Neoplasm \(AMP-1\)](#)  
[Ampullary Adenoma \(AMP-2\)](#)  
[Adenocarcinoma \(AMP-3\)](#)  
[Localized Disease \(AMP-4\)](#)  
[Postoperative Adjuvant Treatment \(AMP-5\)](#)  
[Metastatic Disease \(AMP-6\)](#)  
[Disease Progression \(AMP-7\)](#)

[Principles of Diagnosis, Imaging, and Staging \(AMP-A\)](#)  
[Pancreatic Cancer Radiology Reporting Template \(AMP-A, 5 of 8\)](#)  
[Principles of Stent Management \(AMP-B\)](#)  
[Principles of Surgical Technique \(AMP-C\)](#)  
[Pathologic Analysis: Specimen Orientation, Histologic Sections, and Reporting \(AMP-D\)](#)  
[Principles of Systemic Therapy \(AMP-E\)](#)  
[Principles of Radiation Therapy \(AMP-F\)](#)  
[Principles of Palliation and Supportive Care \(AMP-G\)](#)

[Staging \(ST-1\)](#)

[Abbreviations \(ABBR-1\)](#)

Find an NCCN Member Institution:  
<https://www.nccn.org/home/member-institutions>.

**NCCN Categories of Evidence and Consensus:** All recommendations are category 2A unless otherwise indicated.

See [NCCN Categories of Evidence and Consensus](#).

**NCCN Categories of Preference:** All recommendations are considered appropriate.

See [NCCN Categories of Preference](#).

The NCCN Guidelines® are a statement of evidence and consensus of the authors regarding their views of currently accepted approaches to treatment. Any clinician seeking to apply or consult the NCCN Guidelines is expected to use independent medical judgment in the context of individual clinical circumstances to determine any patient's care or treatment. The National Comprehensive Cancer Network® (NCCN®) makes no representations or warranties of any kind regarding their content, use or application and disclaims any responsibility for their application or use in any way. The NCCN Guidelines are copyrighted by National Comprehensive Cancer Network®. All rights reserved. The NCCN Guidelines and the illustrations herein may not be reproduced in any form without the express written permission of NCCN. ©2024.



Terminologies in all NCCN Guidelines are being actively modified to advance the goals of equity, inclusion, and representation.

Updates in Version 2.2024 of the NCCN Guidelines for Ampullary Adenocarcinoma from Version 1.2024 include:

### [AMP-E 3 OF 9](#)

- Metastatic Disease (First-Line Therapy), Good PS
  - ▶ Targeted Systemic Therapies
    - ◇ Useful in Certain Circumstances:
      - Regimen added: Repotrectinib (if NTRK gene fusion-positive) (Also for Poor PS)

### [AMP-E 4 OF 9](#)

- Therapy for Disease Progression
  - ▶ Targeted Systemic Therapies
    - ◇ Useful in Certain Circumstances:
      - Regimen added: Repotrectinib (if NTRK gene fusion-positive) (Also for Poor PS on AMP-E 5 OF 9)

### [AMP-E 8 OF 9](#)

- New reference added: Solomon BJ, Drilon A, Lin JJ, et al. Repotrectinib in patients with NTRK fusion-positive advanced solid tumors, including non-small cell lung cancer: update from the phase 1/2 TRIDENT-1 trial. *Ann Oncol.* 2023;34:S787-S788.

Updates in Version 1.2024 of the NCCN Guidelines for Ampullary Adenocarcinoma from Version 2.2023 include:

### Global Changes

- References updated throughout the Guidelines

### [AMP-3](#)

- Footnote g modified: Tumor/somatic molecular profiling is recommended for patients with locally advanced/metastatic disease who are candidates for anti-cancer therapy to identify uncommon mutations. Consider specifically testing for potentially actionable somatic findings including, but not limited to: fusions (ALK, NRG1, NTRK, ROS1, FGFR2, and RET), mutations (BRAF, BRCA1/2, KRAS, and PALB2), amplifications (HER2), microsatellite instability (MSI), mismatch repair deficiency (dMMR), or tumor mutational burden (TMB) via an FDA-approved and/or validated next-generation sequencing (NGS)-based assay. *RNA sequencing assays are preferred for detecting RNA fusions because gene fusions are better detected by RNA-based NGS.* Testing on tumor tissue is preferred; however, cell-free DNA testing can be considered if tumor tissue testing is not feasible. See Discussion. (Also for AMP-6, AMP-7)

### [AMP-4](#)

- Footnote j modified: High-risk features include *equivocal or indeterminate* imaging findings, markedly elevated CA 19-9, markedly elevated CEA, large primary tumors, large regional lymph nodes, excessive weight loss, and extreme pain.

### [AMP-6](#)

- Treatment
  - ▶ Poor PS, 2nd bullet modified: *Consider* systemic therapy.

[CONTINUED](#)

**Updates in Version 1.2024 of the NCCN Guidelines for Ampullary Adenocarcinoma from Version 2.2023 include:****[AMP-7](#)**

- Footnote q modified: Serial imaging as indicated to assess disease response. ~~See Principles of Diagnosis, Imaging, and Staging (AMP-A).~~

**[AMP-A 1 OF 8](#)**

- 2nd bullet modified: .... Imaging should be done prior to stenting, when possible. *Imaging with contrast as appropriate for disease management (unless contraindicated).*

**[AMP-A 3 OF 8](#)**

- MDCT Pancreatic Adenocarcinoma Protocol
  - ▶ 2nd row modified: ~~Slice Section~~ thickness
  - ▶ 3rd row modified: Same as ~~section slice~~ thickness (no gap)

**[AMP-E 1 OF 9](#)**

- Principles of Systemic Therapy
  - ▶ Intestinal Type
    - ◇ Regimen removed: FOLFOXIRI (Also for AMP-E 3 OF 9)
    - ◇ Regimen added: FOLFIRINOX (Also for AMP-E 3 OF 9)

**[AMP-E 3 OF 9](#)**

- Metastatic Disease (First-Line Therapy)
  - ▶ Targeted Systemic Therapies
    - ◇ Good PS: Agent added: Selpercatinib (if RET gene fusion-positive) (Also for Poor PS)

**[AMP-E 4 OF 9](#)**

- Sub heading modified: ~~Subsequent~~ Therapy for Disease Progression (Also for AMP-E 5 OF 9)
  - ▶ Targeted Systemic Therapies
    - ◇ Dabrafenib + trametinib (if BRAF V600E mutation positive) moved from Other Recommended to Useful in Certain Circumstances
    - ◇ Agent added: Adagrasib (if KRAS G12C mutation positive) (Also for AMP-E 5 OF 9)
    - ◇ Agent added: Sotorasib (if KRAS G12C mutation positive) (Also for AMP-E 5 OF 9)
    - ◇ New sub heading added: If no prior immunotherapy (Also for AMP-E 5 OF 9)

**[AMP-F 3 OF 6](#)**

- Footnote a moved here from AMP-F 1 OF 6: It is not known whether one regimen is necessarily more effective than another in the four clinical scenarios mentioned above. Therefore, the following recommendations are given as examples of commonly used regimens. However, other recommendations based on similar principles are acceptable.

**[AMP-G](#)**

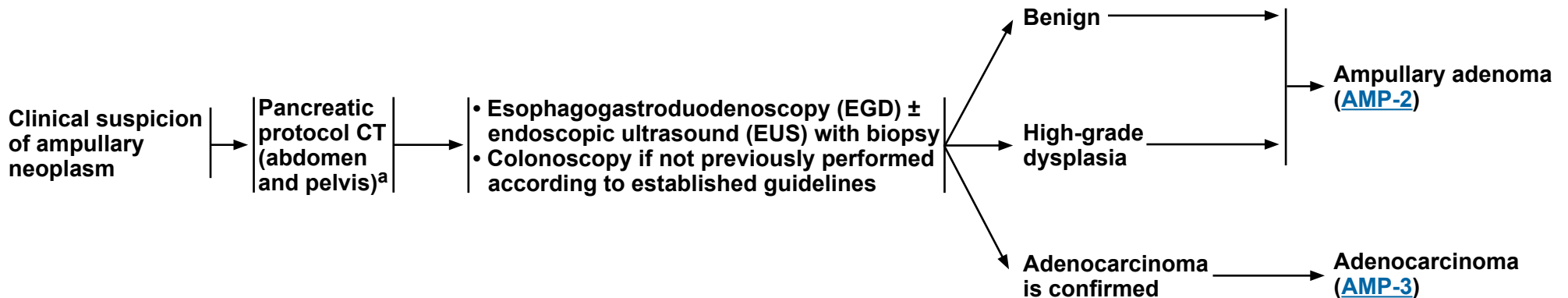
- Pain
  - ▶ 4th bullet added: Celiac plexus radiation/radiosurgery.
  - ▶ 5th bullet added: SBRT



### CLINICAL PRESENTATION

### WORKUP

### TREATMENT



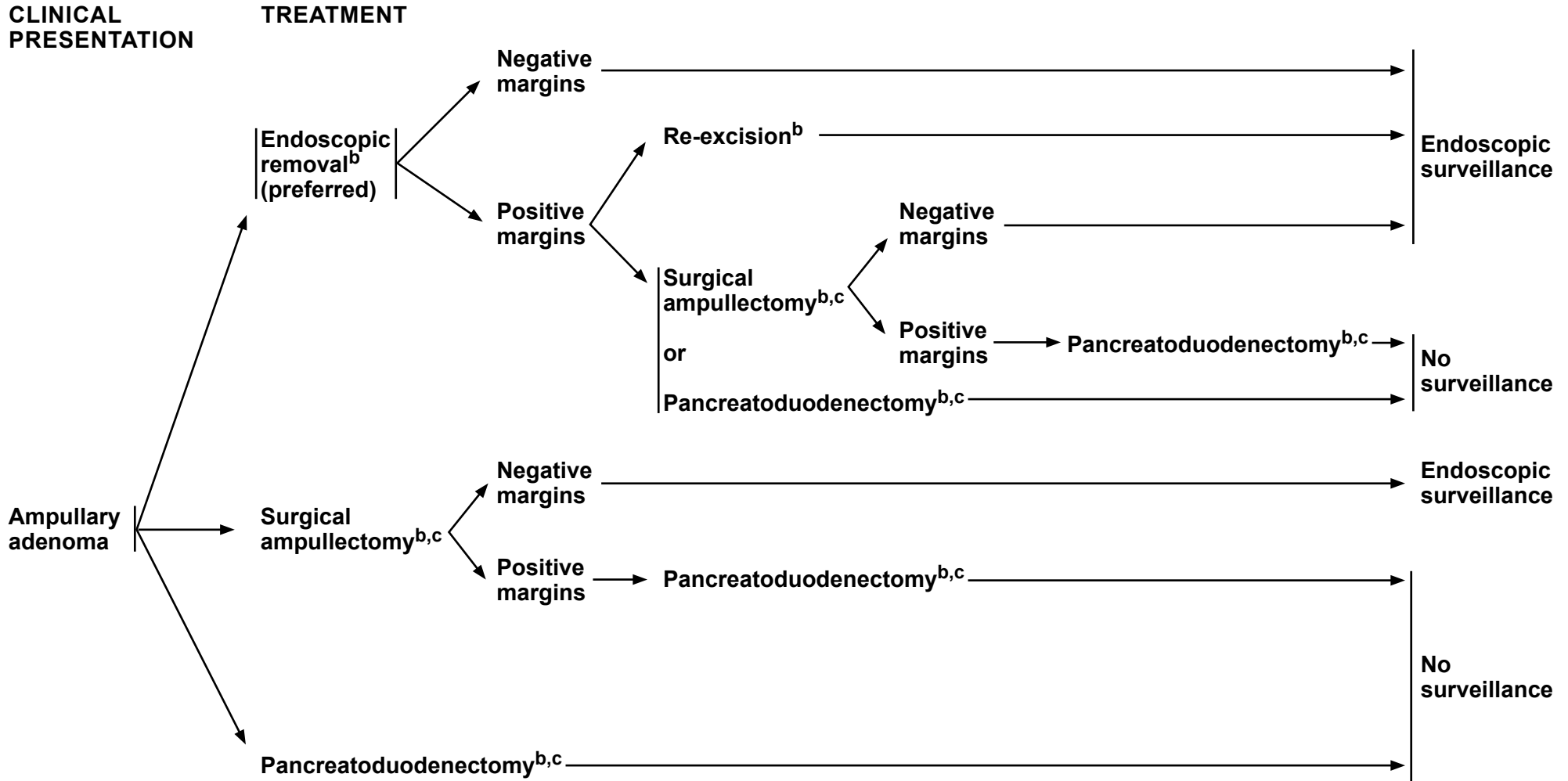
<sup>a</sup> [Principles of Diagnosis, Imaging, and Staging \(AMP-A\).](#)

**Note: All recommendations are category 2A unless otherwise indicated.**



# NCCN Guidelines Version 2.2024

## Ampullary Adenocarcinoma



<sup>b</sup> [Principles of Surgical Technique \(AMP-C\)](#).

<sup>c</sup> Should be performed at a high-volume tertiary center.

**Note: All recommendations are category 2A unless otherwise indicated.**





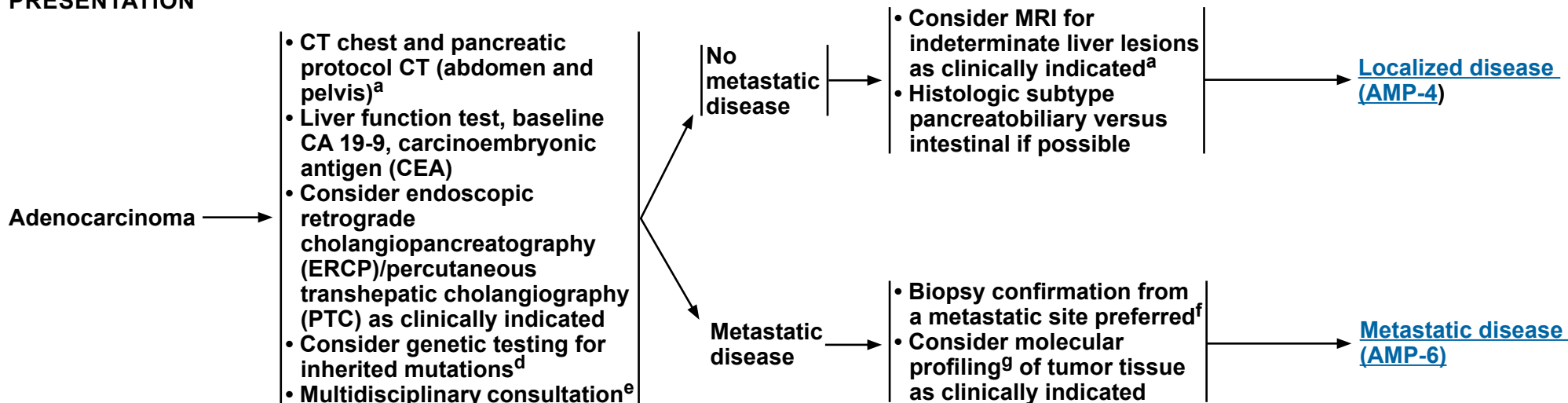
# NCCN Guidelines Version 2.2024

## Ampullary Adenocarcinoma

### CLINICAL PRESENTATION

### WORKUP

### TREATMENT



<sup>a</sup> [Principles of Diagnosis, Imaging, and Staging \(AMP-A\)](#).

<sup>d</sup> Genetic testing for inherited mutations is recommended for any patient with confirmed ampullary cancer, using comprehensive gene panels for hereditary cancer syndromes. Genetic counseling is recommended for patients who test positive for a pathogenic mutation (*ATM*, *BRCA1*, *BRCA2*, *CDKN2A*, *MLH1*, *MSH2*, *MSH6*, *PALB2*, *PMS2*, *STK11*, and *TP53*) or for patients with a positive family history of cancer, especially pancreatic/ampullary cancer, regardless of mutation status. See [NCCN Guidelines for Genetic/Familial High-Risk Assessment: Breast, Ovarian, and Pancreatic](#).

<sup>e</sup> Multidisciplinary review should consider involving expertise from diagnostic imaging, interventional endoscopy, medical oncology, radiation oncology, surgery, pathology, geriatric medicine, genetic counseling, and palliative care ([Principles of Palliation and Supportive Care \[AMP-G\]](#)). Consider consultation with a registered dietitian. See [NCCN Guidelines for Older Adult Oncology](#) and [NCCN Guidelines for Palliative Care](#).

<sup>f</sup> Core biopsy is recommended, if possible, to obtain adequate tissue for possible ancillary studies.

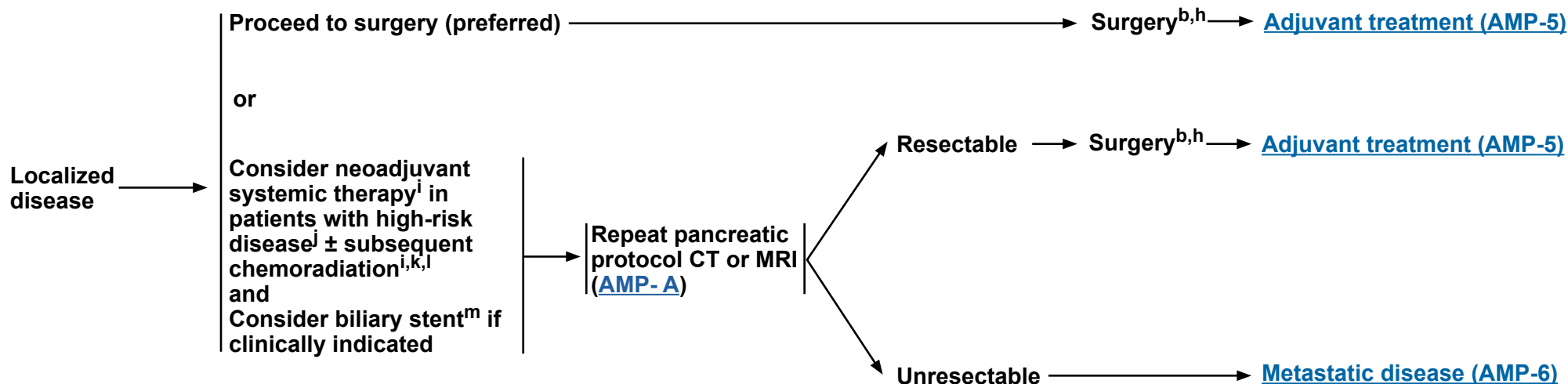
<sup>9</sup> Tumor/somatic molecular profiling is recommended for patients with locally advanced/metastatic disease who are candidates for anti-cancer therapy to identify uncommon mutations. Consider specifically testing for potentially actionable somatic findings including, but not limited to: fusions (*ALK*, *NRG1*, *NTRK*, *ROS1*, *FGFR2*, and *RET*), mutations (*BRAF*, *BRCA1/2*, *KRAS*, and *PALB2*), amplifications (*HER2*), microsatellite instability (MSI), mismatch repair deficiency (dMMR), or tumor mutational burden (TMB) via an FDA-approved and/or validated next-generation sequencing (NGS)-based assay. RNA sequencing assays are preferred for detecting RNA fusions because gene fusions are better detected by RNA-based NGS. Testing on tumor tissue is preferred; however, cell-free DNA testing can be considered if tumor tissue testing is not feasible. See [Discussion](#).

**Note: All recommendations are category 2A unless otherwise indicated.**



**CLINICAL  
PRESENTATION**

**TREATMENT**



<sup>b</sup> [Principles of Surgical Technique \(AMP-C\)](#)

<sup>h</sup> [Pathologic Analysis: Specimen Orientation, Histologic Sections, and Reporting \(AMP-D\)](#).

<sup>i</sup> [Principles of Systemic Therapy \(AMP-E\)](#).

<sup>j</sup> High-risk features include equivocal or indeterminate imaging findings, markedly elevated CA 19-9, markedly elevated CEA, large primary tumors, large regional lymph nodes, excessive weight loss, and extreme pain.

<sup>k</sup> There is limited evidence to recommend specific neoadjuvant regimens off-study, and practices vary with regard to the use of chemotherapy and chemoradiation.

<sup>l</sup> [Principles of Radiation Therapy \(AMP-F\)](#).

<sup>m</sup> [Principles of Stent Management \(AMP-B\)](#).

**Note: All recommendations are category 2A unless otherwise indicated.**



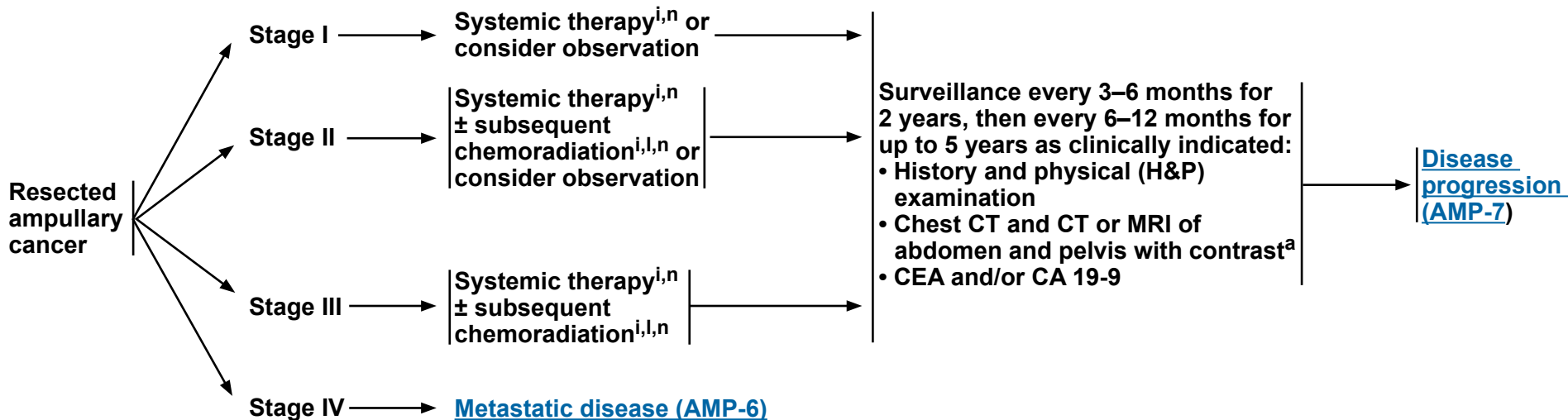
# NCCN Guidelines Version 2.2024

## Ampullary Adenocarcinoma

### POSTOPERATIVE ADJUVANT TREATMENT

### TREATMENT

### SURVEILLANCE



<sup>a</sup> [Principles of Diagnosis, Imaging, and Staging \(AMP-A\)](#).

<sup>i</sup> [Principles of Systemic Therapy \(AMP-E\)](#).

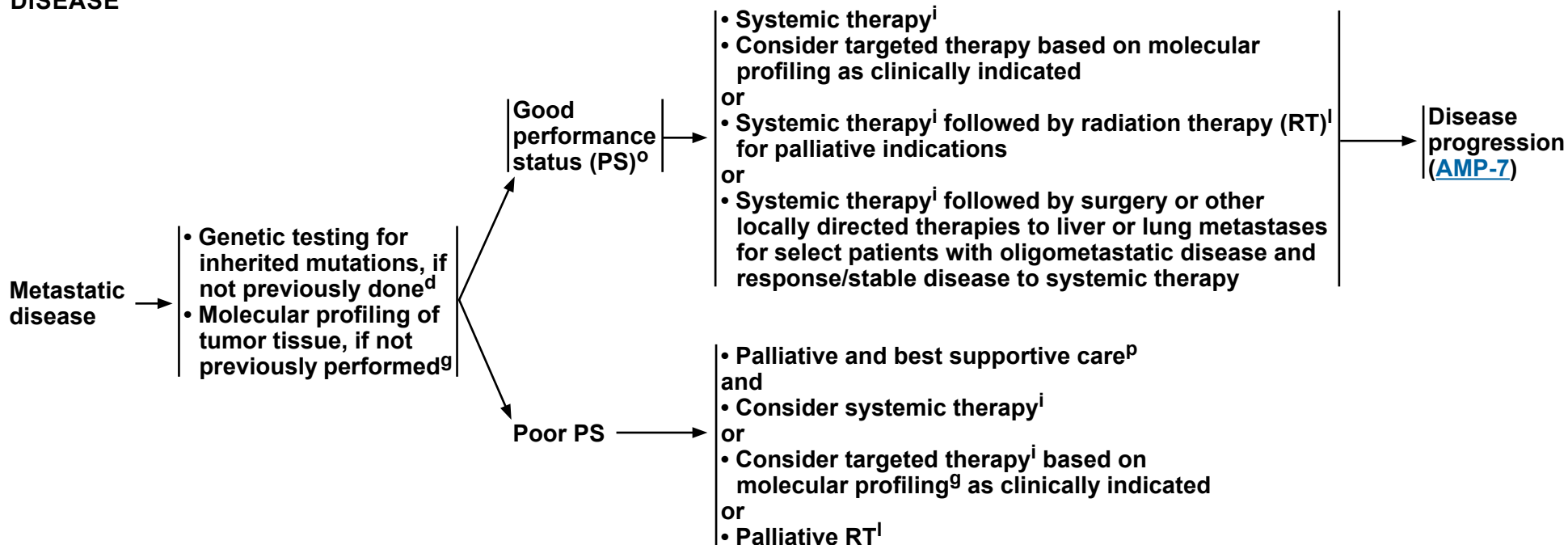
<sup>l</sup> [Principles of Radiation Therapy \(AMP-F\)](#).

<sup>n</sup> Initiation of adjuvant systemic therapy is recommended within 12 weeks of surgery if the patient is medically fit. The optimal duration of treatment is 4 to 6 months.

**Note: All recommendations are category 2A unless otherwise indicated.**

### METASTATIC DISEASE

### TREATMENT



<sup>d</sup> Genetic testing for inherited mutations is recommended for any patient with confirmed ampullary cancer, using comprehensive gene panels for hereditary cancer syndromes. Genetic counseling is recommended for patients who test positive for a pathogenic mutation (*ATM*, *BRCA1*, *BRCA2*, *CDKN2A*, *MLH1*, *MSH2*, *MSH6*, *PALB2*, *PMS2*, *STK11*, and *TP53*) or for patients with a positive family history of cancer, especially pancreatic/ampullary cancer, regardless of mutation status. See [NCCN Guidelines for Genetic/Familial High-Risk Assessment: Breast, Ovarian, and Pancreatic](#).

<sup>g</sup> Tumor/somatic molecular profiling is recommended for patients with locally advanced/metastatic disease who are candidates for anti-cancer therapy to identify uncommon mutations. Consider specifically testing for potentially actionable somatic findings including, but not limited to: fusions (ie, *ALK*, *NRG1*, *NTRK*, *ROS1*, *FGFR2*, and *RET*), mutations (ie, *BRAF*, *BRCA1/2*, *KRAS*, and *PALB2*), amplifications (*HER2*), MSI, dMMR, or TMB via an FDA-approved and/or validated NGS-based assay. RNA sequencing assays are preferred for detecting RNA fusions because gene fusions are better detected by RNA-based NGS. Testing on tumor tissue is preferred; however, cell-free DNA testing can be considered if tumor tissue testing is not feasible. See [Discussion](#).

<sup>i</sup> [Principles of Systemic Therapy \(AMP-E\)](#).

<sup>l</sup> [Principles of Radiation Therapy \(AMP-F\)](#).

<sup>o</sup> Defined as ECOG 0–1, with good biliary drainage and adequate nutritional intake.

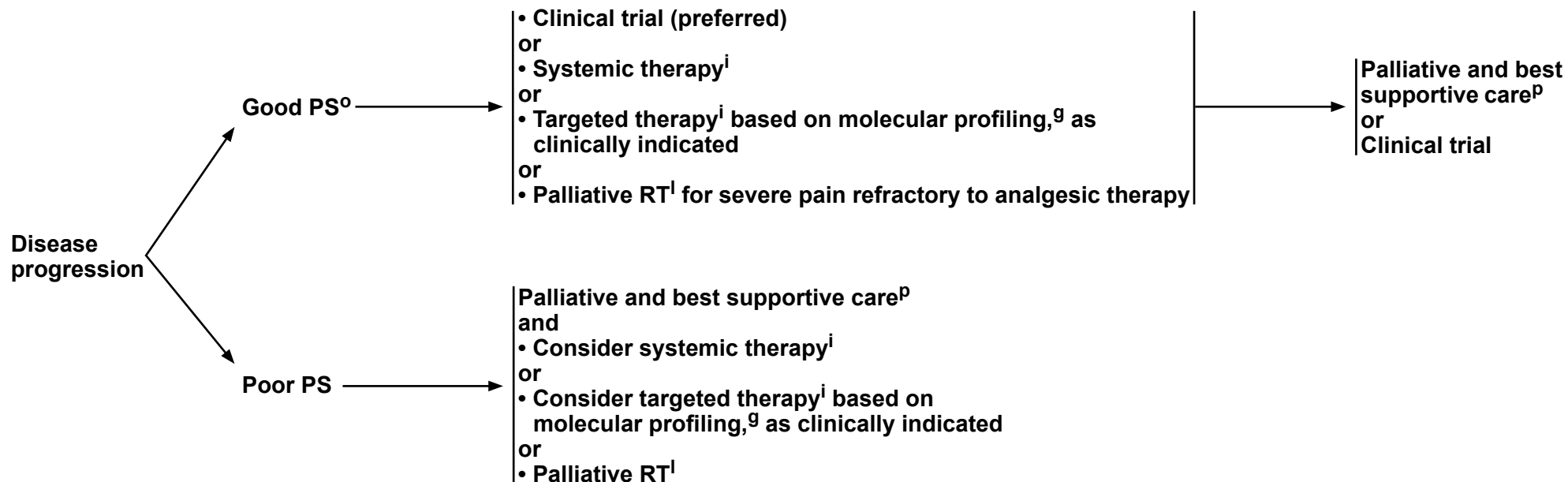
<sup>p</sup> [Principles of Palliation and Supportive Care \(AMP-G\)](#).

**Note: All recommendations are category 2A unless otherwise indicated.**



### DISEASE PROGRESSION

### SUBSEQUENT THERAPY<sup>a,q</sup>



<sup>a</sup> [Principles of Diagnosis, Imaging, and Staging \(AMP-A\)](#).

<sup>g</sup> Tumor/somatic molecular profiling is recommended for patients with locally advanced/metastatic disease who are candidates for anti-cancer therapy to identify uncommon mutations. Consider specifically testing for potentially actionable somatic findings including, but not limited to: fusions (ie, *ALK*, *NRG1*, *NTRK*, *ROS1*, *FGFR2*, and *RET*), mutations (ie, *BRAF*, *BRCA1/2*, *KRAS*, and *PALB2*), amplifications (*HER2*), MSI, dMMR, or TMB via an FDA-approved and/or validated NGS-based assay. RNA sequencing assays are preferred for detecting RNA fusions because gene fusions are better detected by RNA-based NGS. Testing on tumor tissue is preferred; however, cell-free DNA testing can be considered if tumor tissue testing is not feasible. See [Discussion](#).

<sup>i</sup> [Principles of Systemic Therapy \(AMP-E\)](#).

<sup>l</sup> [Principles of Radiation Therapy \(AMP-F\)](#).

<sup>o</sup> Defined as ECOG 0–1, with good biliary drainage and adequate nutritional intake.

<sup>p</sup> [Principles of Palliation and Supportive Care \(AMP-G\)](#).

<sup>q</sup> Serial imaging as indicated to assess disease response.

**Note: All recommendations are category 2A unless otherwise indicated.**

**PRINCIPLES OF DIAGNOSIS, IMAGING, AND STAGING**

- **Decisions about diagnostic management and resectability should involve multidisciplinary consultation at a high-volume center with reference to appropriate high-quality imaging studies to evaluate the extent of disease. Resections should be done at institutions that perform a large number (at least 15–20) of pancreatic resections and/or endoscopic and surgical ampullectomy annually.**
- **High-quality dedicated imaging of the ampullary region should be performed at presentation (even if standard CT imaging is already available), preferably within 4 weeks of surgery, and following neoadjuvant treatment to provide adequate staging and assessment of resectability status. Imaging should be done prior to stenting, when possible. Imaging with contrast as appropriate for disease management (unless contraindicated).**
- **Imaging should include dedicated pancreatic CT of abdomen (preferred) or MRI with contrast.**
  - ▶ **Multi-detector CT (MDCT) angiography, performed by acquiring thin, preferably sub-millimeter, axial sections using a dual-phase pancreatic protocol, with images obtained in the pancreatic and portal venous phase of contrast enhancement, is the preferred imaging tool for dedicated pancreatic imaging.<sup>a</sup> Scan coverage can be extended to cover the chest and pelvis for complete staging as per institutional preferences. Multiplanar reconstruction is preferred as it allows precise visualization of the relationship of the primary tumor to the mesenteric vasculature as well as detection of subcentimeter metastatic deposits. See [MDCT Pancreatic Adenocarcinoma Protocol, AMP-A \(3 of 8\)](#).**
  - ▶ **MRI is most commonly used as a problem-solving tool, particularly for characterization of CT-indeterminate liver lesions or when contrast-enhanced CT cannot be obtained (as in cases with severe allergy to iodinated intravenous [IV] contrast material). This preference for using MDCT as the main imaging tool in many hospitals and imaging centers is mainly due to the higher cost and lack of widespread availability of MRI compared to CT. See [MRI Pancreatic Adenocarcinoma Protocol, AMP-A \(4 of 8\)](#).**
- **The decision regarding resectability status should be made by consensus at multidisciplinary meetings/discussions following the acquisition of dedicated ampullary imaging including complete staging. Use of a radiology staging reporting template is preferred to ensure complete assessment and reporting of all imaging criteria essential for optimal staging, which will improve the decision-making process.<sup>a</sup> See [Pancreatic Cancer Radiology Reporting Template, AMP-A \(5 of 8\)](#). This template can also be used for ampullary tumors.**

<sup>a</sup> Al-Hawary MM, Francis IR, Chari ST, et al. Pancreatic ductal adenocarcinoma radiology reporting template: consensus statement of the Society of Abdominal Radiology and the American Pancreatic Association. *Radiology* 2014;270:248-260.

**Note: All recommendations are category 2A unless otherwise indicated.**



### PRINCIPLES OF DIAGNOSIS, IMAGING, AND STAGING

- **The role of PET/CT (without iodinated IV contrast) remains unclear. Diagnostic CT or MRI with IV contrast as discussed above in conjunction with functional PET imaging can be used per institutional preference. It is not a substitute for high-quality, contrast-enhanced CT.**
- **EUS is recommended as an adjunct to EGD for benign adenomas, high-grade dysplasia, and invasive carcinoma to assess resectability by an endoscopic approach or by surgical ampullectomy and to exclude pancreatic invasion, which would mandate pancreatoduodenectomy.**
- **Colonoscopy should be performed to exclude synchronous colonic polyps or neoplasms according to established guidelines.**
- **Consider diagnostic staging laparoscopy to rule out metastases not detected on imaging as an option prior to surgery or chemoradiation.**

**Note: All recommendations are category 2A unless otherwise indicated.**

**PRINCIPLES OF DIAGNOSIS, IMAGING, AND STAGING****MDCT Pancreatic Adenocarcinoma Protocol<sup>b,c</sup>**

Parameters	Details
Scan type	Helical (preferably 64-multidetector row scanner or more)
Slice thickness	Thinnest possible (<3 mm). Preferably submillimeter (0.5–1 mm) if available
Interval	Same as slice thickness (no gap)
Oral contrast agent	Neutral contrast (positive oral contrast may compromise the three-dimensional [3D] and maximum intensity projection [MIP] reformatted images)
IV contrast	Iodine-containing contrast agents (preferably high concentration [ $>300$ mg I/L]) at an injection rate of 3–5 mL/sec. Lower concentration contrast can be used if low Kv setting is applied.
Scan acquisition timing	Pancreatic parenchymal phase at 40–50 sec and portal venous phase at 65–70 sec, following the commencement of contrast injection
Image reconstruction and display	- Axial images and multiplanar reformats (in the coronal, and per institutional preference, sagittal plane) at 2- to 3-mm interval reconstruction - MIP or 3D volumetric thick section for vascular evaluation (arteries and veins)

<sup>b</sup> Adapted from: Al-Hawary MM, Francis IR, Chari ST, et al. Pancreatic ductal adenocarcinoma radiology reporting template: consensus statement of the Society of Abdominal Radiology and the American Pancreatic Association. *Radiology* 2014;270:248-260.

<sup>c</sup> This pancreatic template can also be used for ampullary tumors.

**Note: All recommendations are category 2A unless otherwise indicated.**



**PRINCIPLES OF DIAGNOSIS, IMAGING, AND STAGING****MRI Pancreatic Adenocarcinoma Protocol<sup>c,d</sup>**

Sequences	Plane	Slice Thickness
T2-weighted single-shot fast spin echo (SSFSE)	Coronal +/- axial	<6 mm
T1-weighted in-phase and opposed-phase gradient echo (GRE)	Axial	<6 mm
T2-weighted fat-suppressed fast spin echo (FSE)	Axial	<6 mm
Diffusion-weighted imaging (DWI)	Axial	<6 mm
Pre- and dynamic post-IV contrast administration (gadolinium <sup>e</sup> ) 3D T1-weighted fat-suppressed gradient echo (in pancreatic, portal venous, and equilibrium phases)	Axial	Thinnest possible 2–3 mm (4–6 mm if overlapping)
T2-weighted magnetic resonance cholangiopancreatography (MRCP) (preferably 3D, fast relaxation fast spin-echo sequence [FRFSE])	Coronal	<3 mm

<sup>c</sup> This pancreatic template can also be used for ampullary tumors.

<sup>d</sup> Sheridan MB, Ward J, Guthrie JA, et al. Dynamic contrast-enhanced MR imaging and dual-phase helical CT in the preoperative assessment of suspected pancreatic cancer: a comparative study with receiver operating characteristic analysis. *AJR Am J Roentgenol* 1999;173:583-590.

<sup>e</sup> Unenhanced MRI can be obtained in cases of renal failure or contraindication to gadolinium IV contrast if enhanced CT cannot be obtained due to severe iodinated contrast allergy.

**Note: All recommendations are category 2A unless otherwise indicated.**

**PRINCIPLES OF DIAGNOSIS, IMAGING, AND STAGING**  
**PANCREATIC ADENOCARCINOMA RADIOLOGY REPORTING TEMPLATE<sup>b,c</sup>**

<b>Morphologic Evaluation</b>			
Appearance (in the pancreatic parenchymal phase)	<input type="checkbox"/> Hypoattenuating	<input type="checkbox"/> Isoattenuating	<input type="checkbox"/> Hyperattenuating
Size (maximal axial dimension in centimeters)	<input type="checkbox"/> Measurable	<input type="checkbox"/> Nonmeasurable (isoattenuating tumors)	
Location <sup>f</sup>	<input type="checkbox"/> Head/uncinate (right of SMV)	<input type="checkbox"/> Neck (anterior to superior mesenteric vein [SMV]/portal vein [PV] confluence) <sup>g</sup>	<input type="checkbox"/> Body/tail (left of SMV)
Pancreatic duct narrowing/abrupt cutoff with or without upstream dilatation	<input type="checkbox"/> Present	<input type="checkbox"/> Absent	
Biliary tree abrupt cutoff with or without upstream dilatation	<input type="checkbox"/> Present	<input type="checkbox"/> Absent	

<sup>b</sup> Adapted from: Al-Hawary MM, Francis IR, Chari ST, et al. Pancreatic ductal adenocarcinoma radiology reporting template: consensus statement of the Society of Abdominal Radiology and the American Pancreatic Association. *Radiology* 2014;270:248-260.

<sup>c</sup> This pancreatic template can also be used for ampullary tumors.

<sup>f</sup> Location does not apply to ampullary tumors.

<sup>g</sup> For management of neck lesions, refer to the Principles of Surgical Technique in the [NCCN Guidelines for Pancreatic Adenocarcinoma](#).

**Note: All recommendations are category 2A unless otherwise indicated.**



# NCCN Guidelines Version 2.2024

## Ampullary Adenocarcinoma

### PRINCIPLES OF DIAGNOSIS, IMAGING, AND STAGING

#### PANCREATIC ADENOCARCINOMA CANCER RADIOLOGY REPORTING TEMPLATE<sup>b,c</sup>

Arterial Evaluation				
Superior mesenteric artery (SMA) Contact	<input type="checkbox"/> Present	<input type="checkbox"/> Absent		
Degree of solid soft-tissue contact	<input type="checkbox"/> ≤180	<input type="checkbox"/> >180		
Degree of increased hazy attenuation/stranding contact	<input type="checkbox"/> ≤180	<input type="checkbox"/> >180		
Focal vessel narrowing or contour irregularity	<input type="checkbox"/> Present	<input type="checkbox"/> Absent		
Extension to first SMA branch	<input type="checkbox"/> Present	<input type="checkbox"/> Absent		
<b>Celiac Axis Contact</b>				
Degree of solid soft-tissue contact	<input type="checkbox"/> ≤180	<input type="checkbox"/> >180		
Degree of increased hazy attenuation/stranding contact	<input type="checkbox"/> ≤180	<input type="checkbox"/> >180		
Focal vessel narrowing or contour irregularity	<input type="checkbox"/> Present	<input type="checkbox"/> Absent		
<b>CHA Contact</b>				
Degree of solid soft-tissue contact	<input type="checkbox"/> ≤180	<input type="checkbox"/> >180		
Degree of increased hazy attenuation/stranding contact	<input type="checkbox"/> ≤180	<input type="checkbox"/> >180		
Focal vessel narrowing or contour irregularity	<input type="checkbox"/> Present	<input type="checkbox"/> Absent		
Extension to celiac axis	<input type="checkbox"/> Present	<input type="checkbox"/> Absent		
Extension to bifurcation of right/left hepatic artery	<input type="checkbox"/> Present	<input type="checkbox"/> Absent		
<b>Arterial Variant</b>				
Variant anatomy	<input type="checkbox"/> Present	<input type="checkbox"/> Absent		
Variant vessel contact	<input type="checkbox"/> Accessory right hepatic artery	<input type="checkbox"/> Replaced right hepatic artery	<input type="checkbox"/> Replaced common hepatic artery	<input type="checkbox"/> Others (origin of replaced or accessory artery) _____
Degree of solid soft-tissue contact	<input type="checkbox"/> Present	<input type="checkbox"/> Absent		
Degree of increased hazy attenuation/stranding contact	<input type="checkbox"/> ≤180	<input type="checkbox"/> >180		
Focal vessel narrowing or contour irregularity	<input type="checkbox"/> ≤180	<input type="checkbox"/> >180		
	<input type="checkbox"/> Present	<input type="checkbox"/> Absent		

<sup>b</sup> Adapted from: Al-Hawary MM, Francis IR, Chari ST, et al. Pancreatic ductal adenocarcinoma radiology reporting template: consensus statement of the Society of Abdominal Radiology and the American Pancreatic Association. Radiology 2014;270:248-260.

<sup>c</sup> This pancreatic template can also be used for ampullary tumors.

**Note: All recommendations are category 2A unless otherwise indicated.**

### PRINCIPLES OF DIAGNOSIS, IMAGING, AND STAGING

#### PANCREATIC ADENOCARCINOMA CANCER RADIOLOGY REPORTING TEMPLATE<sup>b,c</sup>

<b>Venous Evaluation</b>			
<b>Main Portal Vein (MPV) Contact</b>	<input type="checkbox"/> Present	<input type="checkbox"/> Absent	<input type="checkbox"/> Complete occlusion
Degree of solid soft-tissue contact	<input type="checkbox"/> ≤180	<input type="checkbox"/> >180	
Degree of increased hazy attenuation/stranding contact	<input type="checkbox"/> ≤180	<input type="checkbox"/> >180	
Focal vessel narrowing or contour irregularity (tethering or tear drop)	<input type="checkbox"/> Present	<input type="checkbox"/> Absent	
<b>SMV Contact</b>			
<b>SMV Contact</b>	<input type="checkbox"/> Present	<input type="checkbox"/> Absent	<input type="checkbox"/> Complete occlusion
Degree of solid soft-tissue contact	<input type="checkbox"/> ≤180	<input type="checkbox"/> >180	
Degree of increased hazy attenuation/stranding contact	<input type="checkbox"/> ≤180	<input type="checkbox"/> >180	
Focal vessel narrowing or contour irregularity (tethering or tear drop)	<input type="checkbox"/> Present	<input type="checkbox"/> Absent	
Extension	<input type="checkbox"/> Present	<input type="checkbox"/> Absent	
<b>Other</b>			
Thrombus within vein (tumor, bland)	<input type="checkbox"/> Present <input type="checkbox"/> MPV <input type="checkbox"/> SMV <input type="checkbox"/> Splenic vein	<input type="checkbox"/> Absent	
Venous collaterals	<input type="checkbox"/> Present <input type="checkbox"/> Around pancreatic head <input type="checkbox"/> Porta hepatis <input type="checkbox"/> Root of the mesentery <input type="checkbox"/> Left upper quadrant	<input type="checkbox"/> Absent	

<sup>b</sup> Adapted from: Al-Hawary MM, Francis IR, Chari ST, et al. Pancreatic ductal adenocarcinoma radiology reporting template: consensus statement of the Society of Abdominal Radiology and the American Pancreatic Association. Radiology 2014;270:248-260.

<sup>c</sup> This pancreatic template can also be used for ampullary tumors.

**Note: All recommendations are category 2A unless otherwise indicated.**



### PRINCIPLES OF DIAGNOSIS, IMAGING, AND STAGING

#### PANCREATIC ADENOCARCINOMA CANCER RADIOLOGY REPORTING TEMPLATE<sup>b,c</sup>

<b>Extrapancreatic Evaluation</b>		
Liver lesions	<input type="checkbox"/> Present <input type="checkbox"/> Suspicious <input type="checkbox"/> Indeterminate <input type="checkbox"/> Likely benign	<input type="checkbox"/> Absent
Peritoneal or omental nodules	<input type="checkbox"/> Present	<input type="checkbox"/> Absent
Ascites	<input type="checkbox"/> Present	<input type="checkbox"/> Absent
Suspicious lymph nodes	<input type="checkbox"/> Present <input type="checkbox"/> Porta hepatis <input type="checkbox"/> Celiac <input type="checkbox"/> Splenic hilum <input type="checkbox"/> Paraaortic <input type="checkbox"/> Aortocaval <input type="checkbox"/> Other _____	<input type="checkbox"/> Absent
Other extrapancreatic disease (invasion of adjacent structures)	<input type="checkbox"/> Present • Organs involved: _____	<input type="checkbox"/> Absent
<b>Impression</b>		
	Tumor size: _____	Tumor location: _____
Vascular contact	<input type="checkbox"/> Present • Vessel involved: _____ • Extent: _____	<input type="checkbox"/> Absent
Metastasis	<input type="checkbox"/> Present (Location _____)	<input type="checkbox"/> Absent

<sup>b</sup> Adapted from: Al-Hawary MM, Francis IR, Chari ST, et al. Pancreatic ductal adenocarcinoma radiology reporting template: consensus statement of the Society of Abdominal Radiology and the American Pancreatic Association. Radiology 2014;270:248-260.

<sup>c</sup> This pancreatic template can also be used for ampullary tumors.

**Note: All recommendations are category 2A unless otherwise indicated.**



### PRINCIPLES OF STENT MANAGEMENT

- **Stent placement is not routinely recommended prior to planned surgery; however, a stent may be considered for symptoms of cholangitis/fever or severe symptomatic jaundice (intense pruritus), or if surgery is being delayed for any reason, including neoadjuvant therapy.**
- **ERCP-guided biliary drainage is preferred. If ERCP is not possible, a PTC approach may be used.**
- **Stents should be as short as feasible.**
- **Self-expanding metal stents (SEMS) should only be placed if tissue diagnosis is confirmed.**
- **For neoadjuvant therapy, fully covered SEMS are preferred since they can be removed/exchanged.**

**Note: All recommendations are category 2A unless otherwise indicated.**



## PRINCIPLES OF SURGICAL TECHNIQUE

Ampullary adenomas up to 20 mm in diameter may be safely removed endoscopically, including those with high-grade dysplasia. Local extent of the lesion may be assessed with endoscopy with image enhancement, and with EUS and MRI/MRCP for intraductal and submucosal invasion. EUS should be performed in all lesions being considered for endoscopic ampullectomy regardless of size. If deep invasion is suspected, EUS with biopsies may be pursued at that time. Endoscopic removal of ampullary adenomas should be performed at a high-volume center.<sup>1-3</sup>

The goals of surgical ampullectomy for benign adenomas and those with high-grade dysplasia include a wide excision of the lesion, meticulous reimplantation of the biliary and pancreatic ducts to the mucosa of the duodenum, and careful orientation of the specimen for pathologic analysis.

The goals of surgery for adenocarcinoma of the ampulla of Vater include an oncologic resection of the primary tumor and regional lymph nodes. Careful intraoperative staging should rule out peritoneal, liver, and distant lymph node metastases, and resection of the primary tumor should only be done in the absence of distant disease. Surgery should be done efficiently, minimizing blood loss, operative time, and cost. Management of a soft pancreatic remnant should be anticipated.

Consider frozen section analysis of the pancreatic neck and bile duct. To avoid cautery artifact that may confound the frozen section, assess the pancreatic neck and bile duct at time of surgery by frozen section approximately 5 mm from the transection margin. If tumor is located within 5 mm of margins, consider further excision of the pancreas and bile duct to ensure at least 5 mm of clearance.

### Pancreatoduodenectomy (Whipple technique)

The goals of surgical extirpation of carcinoma of the ampulla of Vater focus on the achievement of an R0 resection, as a margin-positive specimen is associated with poor long-term survival.<sup>4,5</sup> Achievement of a margin-negative dissection must focus on meticulous perivascular dissection of the lesion similar to pancreatic cancer, recognition of the need for vascular resection and/or reconstruction, and the potential need for extra-pancreatic organ resection. Medial dissection of pancreatic head lesions is best achieved by complete mobilization of the PV and SMV from the uncinate process (assuming no evidence of tumor infiltration). Skeletalization of the lateral, posterior, and anterior borders of the SMA down to the level of the adventitia will maximize uncinate yield and radial margin.<sup>6,7</sup>

- In the absence of frank venous occlusion noted on preoperative imaging, the need for lateral venorrhaphy or complete portal or SMV resection and reconstruction to achieve an R0 resection may be suggested but is often not known until division of the pancreatic neck has occurred. Tethering of the carcinoma to the lateral wall of the PV while uncommon, requires careful dissection to free the vein from the pancreatic head if it is possible to do so. Differentiation of tumor infiltration into the vein wall from tumor-related desmoplasia is frequently impossible to ascertain. Data support an aggressive approach to partial or complete vein excision if tumor infiltration is suspected.

## [References](#)

Note: All recommendations are category 2A unless otherwise indicated.





### PRINCIPLES OF SURGICAL TECHNIQUE REFERENCES

- <sup>1</sup> Bassan M, Bourke M. Endoscopic ampullectomy: a practical guide. *J Interv Gastroenterol* 2012;2:23-30.
- <sup>2</sup> Alvarez-Sánchez MV, Napoleon B. EUS and ampullary adenoma: Why? When?. *Endosc Int Open* 2016;4:E1319-E1321.
- <sup>3</sup> Patel V, Jowell P, Obando J, et al. Does ampullary adenoma size predict invasion on EUS? Does invasion on EUS predict presence of malignancy? *Endosc Int Open* 2016;4:E1313-E1318.
- <sup>4</sup> Bilimoria KY, Talamonti MS, Sener SF, et al. Effect of hospital volume on margin status after pancreaticoduodenectomy for cancer. *J Am Coll Surg* 2008;207:510-519.
- <sup>5</sup> Winter JM, Cameron JL, Campbell KA, et al. 1423 pancreaticoduodenectomies for pancreatic cancer: A single-institution experience. *J Gastrointest Surg* 2006;10:1199-1210; discussion 1210-1191.
- <sup>6</sup> Yeo TP, Hruban RH, Leach SD, et al. Pancreatic cancer. *Curr Probl Cancer* 2002;26:176-275.
- <sup>7</sup> Nakeeb A, Lillemoe KD, Grosfeld JL. Surgical techniques for pancreatic cancer. *Minerva Chir* 2004;59:151-163.

**Note: All recommendations are category 2A unless otherwise indicated.**



### **PATHOLOGIC ANALYSIS: SPECIMEN ORIENTATION, HISTOLOGIC SECTIONS, AND REPORTING**

The primary purpose of pathologic analysis of the ampullary specimen is to determine the pathologic stage of the tumor, completeness of resection, and other histopathologic features that impact prognosis and clinical management.

#### **Ampullectomy Specimen**

- **Specimen orientation:** Specimen orientation and inking involve both the pathologist and surgeon/endoscopist, as this will help to ensure accurate assessment of the size and extent of the tumor. There should be either direct communication between the surgeon/endoscopist and pathologist for proper orientation and margin identification, or the surgeon/endoscopist should identify the important margins with a clearly understood and documented method (eg, written on the pathology requisition); for example: the deep (radial), duodenal mucosal, and any other relevant margins should be marked.

#### **Pancreatoduodenectomy**

- **Specimen orientation:** Specimen orientation and inking involve both the pathologist and surgeon, as this will help to ensure accurate assessment of the size and extent of the tumor. There should be either direct communication between the surgeon and pathologist for proper orientation and margin identification, or the surgeon should identify the important margins with a clearly understood and documented method (eg, written on the pathology requisition); for example: the distal and proximal margins of the SMV and SMA and the bile duct margin should be marked.
- Every effort should be made to identify all regional lymph nodes within the pancreatoduodenectomy specimen. For optimal staging, a minimum of 17 lymph nodes in pancreatoduodenectomy specimens is recommended.<sup>1,2,3</sup>

**Note: All recommendations are category 2A unless otherwise indicated.**

#### **References**

**PATHOLOGIC ANALYSIS: SPECIMEN ORIENTATION, HISTOLOGIC SECTIONS, AND REPORTING****Pancreatoduodenectomy (continued)****• Margins**

- ▶ **Definitions of the margins and uniformity of nomenclature are critical to accurate reporting.**
  - ◇ **SMA (retroperitoneal/uncinate) Margin:** The most important margin is the soft tissue directly adjacent to the proximal 3 to 4 cm of the SMA.<sup>4</sup> This margin is often referred to as the “retroperitoneal margin” or “posterior margin,” but has also been referred to as the “uncinate margin” or “mesenteric margin.” More recently, this margin has been referred to as the “SMA margin” to correlate with its location on the specimen. Radial, rather than en face, sections of this margin will more clearly demonstrate how closely this margin is approached by tumor. The uncinata margin should be inked. Rather than being submitted en face, the uncinata margin tissue should be shaved/amputated, then the portion of tissue should be sectioned perpendicular to the ink and submitted entirely for histologic examination.
  - ◇ **PV Margins:** If an en bloc partial or complete vein resection is added to the surgical specimen, it should be marked separately. En face proximal and distal end margins of the vein should be separately submitted as “Proximal Portal Vein Margin” and “Distal Portal Vein Margin.” A section documenting tumor invasion into the vein wall should also be submitted.
  - ◇ **Pancreatic Neck (transection) Margin:** This is the en face section of the transected pancreatic neck. Care should be taken when placing the section into the cassette to document the orientation of the section with respect to the true margin (eg, facing down so that the initial section into the block represents the true margin, or facing up so that the initial section represents the surface opposite the true margin).
  - ◇ **Bile Duct Margin:** This is the en face section of the bile duct end. The section should be removed from the unopened duct and care should be taken when placing the section into the cassette to document the orientation of the section with respect to the true margin (eg, facing down so that the initial section into the block represents the true margin, or facing up so that the initial section represents the surface opposite the true margin).
- ▶ **Other margins analyzed in pancreatoduodenectomy specimens include the proximal (gastric or enteric) and distal enteric margins (en face sections).**
- ▶ **Collectively, these margins and pancreatic tissue surfaces constitute the circumferential surface of the specimen. Designating the various specific margins and surfaces with different colored inks will allow recognition on microscopy.**

<b>Note: All recommendations are category 2A unless otherwise indicated.</b>
--

[References](#)

**PATHOLOGIC ANALYSIS: SPECIMEN ORIENTATION, HISTOLOGIC SECTIONS, AND REPORTING****Pancreatoduodenectomy (continued)****• Other Circumferential Surfaces**

- ▶ **Posterior (non-SMA margin) Surface:** This surface consists of the posterior caudad aspect of the pancreatic head that is not part of the SMA margin and that appears to be covered by loose connective tissue. This surface is not a true margin, but identification and reporting of this surface when positive is recommended, but not currently required, for data collection purposes, so that the association with risk of recurrence and other prognostic indicators can be studied. Radial, rather than en face, sections of this surface will more clearly demonstrate whether it is involved by tumor. In some instances, this surface may already be included in sections of the SMA margin.
- ▶ **SMV Groove:** Also referred to as the vascular groove surface, this is the smooth-surfaced groove on the posterior-medial surface of the pancreatic head that rests over the SMV. This surface is not a true margin, but identification and reporting of this surface when positive is recommended, but not currently required, for data collection purposes, so that the association with risk of recurrence and other prognostic indicators can be studied. Radial, rather than en face, sections of this surface will more clearly demonstrate whether it is involved by tumor, and also will provide the distance of the tumor from the surface. As is true for the posterior (non-SMA margin) surface, in some instances, this surface may be included in the same sections as the SMA margin.
- ▶ **Anterior Surface:** The anterior surface is not a true margin, but identification and reporting of this surface when positive is recommended, but not currently required, for data collection purposes, so that the association with risk of recurrence and other prognostic indicators can be studied. In some cases where the anterior surface is adherent to other structures, from which it is surgically dissected or transected, it should be considered an additional circumferential margin, for which the closest distance from tumor should be reported.

**• Histologic Sectioning**

- ▶ The approach to histologic sectioning is determined by the unique characteristics of the tumor, but is also influenced by institutional preferences, expertise, and experience. For examination of ampullary carcinoma, it is recommended that the pancreas be bivalved along probes placed in the bile and pancreatic ducts, with sections submitted in a manner that allows for determination of the extent of invasion into the sphincter of Oddi, duodenal wall, and pancreas, as well as the relationship between invasive carcinoma and any precursor lesions from which it may be arising, and the relationship to the pancreatic circumferential tissue margins mentioned above.
- ▶ Tumor clearance should be reported with millimeter accuracy for all margins where tumor is close (within  $\leq 1.0$  cm of the tumor). This may be done using either mm (eg, "2 mm") or cm (eg, "0.2 cm"). For margins distant from tumor ( $>1.0$  cm from tumor), tumor clearance may be reported with centimeter accuracy.
- ▶ Attached organs resected with the specimen en bloc require serial sectioning to assess not only direct extension, but metastatic deposits as well. One section that demonstrates direct invasion of the organ and/or a separate metastatic deposit is required.

[References](#)**Note: All recommendations are category 2A unless otherwise indicated.**

**PATHOLOGIC ANALYSIS: SPECIMEN ORIENTATION, HISTOLOGIC SECTIONS, AND REPORTING****Histologic Subtyping**

- The NCCN Panel recommends histologic subtyping.
- Report the histologic subtype as intestinal, pancreatobiliary, or mixed.<sup>5-10</sup>
  - ▶ Intestinal-type tumors are characterized by the presence of large tubules lined by tall columnar cells with elongated, pseudostratified, hyperchromatic nuclei resembling colonic-type adenocarcinoma.<sup>5</sup> They may also exhibit an immunophenotypic staining profile similar to that of colonic-type adenocarcinomas (typically positive for CK20, CDX2, or MUC2 with negative MUC1, or positive for CK20, CDX2, and MUC2, irrespective of MUC1 staining).<sup>8-10</sup>
  - ▶ Pancreatobiliary-type tumors are characterized by variably differentiated glands lined by non-stratified cuboidal or low columnar eosinophilic epithelium exhibiting round to oval, irregular, hypochromatic, or hyperchromatic nuclei with vesicular chromatin and irregular nuclear contours and a high nuclear to cytoplasmic ratio. Abundant desmoplastic stroma may be present. They may exhibit an immunophenotypic staining profile (positive for MUC1 and negative for CDX2 and MUC2, irrespective of CK20 staining) similar to that of pancreatic/biliary carcinomas.<sup>8-10</sup> It should be noted that a significant proportion of ampullary adenocarcinomas may be of mixed or ambiguous phenotype.<sup>5,8,9</sup> These ambiguous cases should be classified as tubular adenocarcinoma with mixed features,<sup>9</sup> but we recommend that the predominant pattern be noted in the pathology report for data collection purposes and future analysis.
- Current data on the independent prognostic and predictive value of subtyping with regard to adjuvant therapy outcomes are conflicting, with some studies suggesting no significant independent association between histologic subtype and adjuvant therapy response or overall or disease-free survival (DFS).<sup>11-16</sup>
- Although immunohistochemistry may be helpful in aiding the determination of histologic subtype, it is not required, as there may be overlap in the immunohistochemical profiles of intestinal and pancreatobiliary-type adenocarcinomas,<sup>8,17,18</sup> which may make current immunohistochemical panels unreliable for definitive determination of subtype.

<b>Note: All recommendations are category 2A unless otherwise indicated.</b>
--

**References**

**PATHOLOGIC ANALYSIS: SPECIMEN ORIENTATION, HISTOLOGIC SECTIONS, AND REPORTING**

- The NCCN Ampullary Adenocarcinoma Panel currently supports pathology synoptic reports from the College of American Pathologists (CAP). The proposal included herein is an abbreviated minimum analysis of ampullary adenocarcinoma specimens from the CAP recommendations. For more information about pathologic analysis, please refer to the CAP Cancer Protocol Template for carcinoma of the Ampulla of Vater.<sup>19</sup> In addition to the standard tumor node metastasis (TNM) staging, other variables are included, all of which have established or emerging prognostic implications in the evolution of this disease.<sup>7,8</sup>
- Treatment effect should be assessed and reported by the pathologist, as tumor viability may impact postoperative therapy options.<sup>11,20</sup>

**Specimen Type**

- Tumor size (obtained from careful gross measurement of the largest dimension of the tumor in centimeters, and corroborated on microscopic examination)
  - Histologic type (H) and subtype (intestinal, pancreatobiliary, or mixed)
  - Histologic grade [G (x-3)]
  - Primary tumor stage [T (x-4)]
  - Regional lymph nodes [N (x-2)]<sup>a</sup>
    - ▶ # nodes recovered
    - ▶ # nodes involved
  - Metastases [M (0-1)]
  - Margins and other circumferential surfaces: Involvement should be defined and surgical clearance measured with millimeter accuracy for close (within 1.0 cm of tumor) margin
    - ▶ Pancreatoduodenectomy specimen:
      - ◇ SMA (retroperitoneal/uncinate) margin
      - ◇ Posterior surface
      - ◇ SMV groove
      - ◇ Pancreatic neck (transection) margin
      - ◇ Bile duct margin
      - ◇ Gastric/enteric margins
      - ◇ Anterior surface
    - ▶ Ampullectomy specimen:
      - ◇ Bile duct margin
      - ◇ Pancreatic duct margin
      - ◇ Duodenal mucosal margin
      - ◇ Deep (radial) margin
  - Lymphovascular invasion (L)
  - Additional pathologic findings
    - ▶ Dysplasia/adenoma (including intra-ampullary papillary tubular neoplasm [IAPN] or peri-ampullary duodenal adenoma)
  - Tumor regression score following prior chemotherapy and/or RT
- Final stage: T, N, M (per AJCC)

<sup>a</sup> Every effort should be made to identify all regional lymph nodes within the ampullary specimen ([Discussion](#)).

[References](#)

**Note: All recommendations are category 2A unless otherwise indicated.**

**PATHOLOGIC ANALYSIS: SPECIMEN ORIENTATION, HISTOLOGIC SECTIONS, AND REPORTING REFERENCES**

- <sup>1</sup> Partelli S, Crippa S, Capelli P, et al. Adequacy of lymph node retrieval for ampullary cancer and its association with improved staging and survival. *World J Surg* 2013;37:1397-1404.
- <sup>2</sup> Balci S, Basturk O, Saka B, et al. Substaging nodal status in ampullary carcinomas has significant prognostic value: proposed revised staging based on an analysis of 313 well-characterized cases. *Ann Surg Oncol* 2015;22:4392-4401.
- <sup>3</sup> Nassour I, Christie A, Choti MA, et al. Determining the adequate examined lymph node count in resected ampullary adenocarcinoma-A national cohort study. *J Gastrointest Surg* 2018;22:792-801.
- <sup>4</sup> Todoroki T, Koike N, Morishita Y, et al. Patterns and predictors of failure after curative resections of carcinoma of the ampulla of Vater. *Ann Surg Oncol* 2003;10:1176-1183.
- <sup>5</sup> Reid MD, Balci S, Ohike N, et al. Ampullary carcinoma is often of mixed or hybrid histologic type: an analysis of reproducibility and clinical relevance of classification as pancreatobiliary versus intestinal in 232 cases. *Mod Pathol* 2016;29:1575-1585.
- <sup>6</sup> Westgaard A, Tafjord S, Farstad IN, et al. Pancreatobiliary versus intestinal histologic type of differentiation is an independent prognostic factor in resected periampullary adenocarcinoma. *BMC Cancer* 2008;8:170.
- <sup>7</sup> Kumari N, Prabha K, Singh RK, et al. Intestinal and pancreatobiliary differentiation in periampullary carcinoma: the role of immunohistochemistry. *Hum Pathol* 2013;44:2213-2219.
- <sup>8</sup> Ang DC, Shia J, Tang LH, et al. The utility of immunohistochemistry in subtyping adenocarcinoma of the ampulla of vater. *Am J Surg Pathol* 2014;38:1371-1379.
- <sup>9</sup> Chang DK, Jamieson NB, Johns AL. Histomolecular phenotypes and outcome in adenocarcinoma of the ampulla of vater. *J Clin Oncol* 2013;31:1348-1356.
- <sup>10</sup> Schueneman A, Goggins M, Ensor J, et al. Validation of histomolecular classification utilizing histological subtype, MUC1, and CDX2 for prognostication of resected ampullary adenocarcinoma. *Br J Cancer* 2015;113:64-68.
- <sup>11</sup> Yamashita S, Overman MJ, Wang H, et al. Pathologic response to preoperative therapy as a novel prognosticator for ampullary and duodenal adenocarcinoma. *Ann Surg Oncol* 2017;24:3954-3963.
- <sup>12</sup> Neoptolemos JP, Stocken DD, Friess H, et al. A randomized trial of chemoradiotherapy and chemotherapy after resection of pancreatic cancer. *N Engl J Med* 2004;350:1200-1210. Erratum in: *N Engl J Med* 2004;351:726.
- <sup>13</sup> Neoptolemos JP, Moore MJ, Cox TF, et al. Effect of adjuvant chemotherapy with fluorouracil plus folinic acid or gemcitabine vs observation on survival in patients with resected periampullary adenocarcinoma: The ESPAC-3 Periampullary Cancer Randomized Trial. *JAMA* 2012;308:147-156.
- <sup>14</sup> Jin Z, Hartgers ML, Sanhueza CT, Shubert CR, et al. Prognostic factors and benefits of adjuvant therapy after pancreatoduodenectomy for ampullary adenocarcinoma: Mayo Clinic experience. *Eur J Surg Oncol* 2018;44:677-683.
- <sup>15</sup> Ecker BL, Vollmer CM Jr, Behrman SW, et al. Role of adjuvant multimodality therapy after curative-intent resection of ampullary carcinoma. *JAMA Surg* 2019;154:706-714.
- <sup>16</sup> Moekotte AL, Lof S, Van Roessel S, et al. Histopathologic predictors of survival and recurrence in resected ampullary adenocarcinoma. *Ann Surg* 2020;272:1086-1093.
- <sup>17</sup> Chu PG, Schwarz RE, Lau SK et al. Immunohistochemical staining in the diagnosis of pancreatobiliary and ampulla of Vater adenocarcinoma: application of CDX2, CK17, MUC1, and MUC2. *Am J Surg Pathol* 2005;29:359-367.
- <sup>18</sup> Werling RW, Yaziji H, Bacchi CE et al. CDX2, a highly sensitive and specific marker of adenocarcinomas of intestinal origin: an immunohistochemical survey of 476 primary and metastatic carcinomas. *Am J Surg Pathol* 2003;27:303-310.
- <sup>19</sup> Burgart LJ, Shi C, Adsay VN, et al. Protocol for the Examination of Specimens from Patients with Carcinoma of the Ampulla of Vater. College of American Pathologists. *Cancer Protocol Templates*; 2021. Available at: [https://documents.cap.org/protocols/Ampulla\\_4.2.0.0.REL\\_CAPCP.pdf](https://documents.cap.org/protocols/Ampulla_4.2.0.0.REL_CAPCP.pdf).
- <sup>20</sup> Palta M, Patel P, Broadwater G, et al. Carcinoma of the ampulla of Vater: patterns of failure following resection and benefit of chemoradiotherapy. *Ann Surg Oncol* 2012;19:1535-1540.

**Note: All recommendations are category 2A unless otherwise indicated.**



**PRINCIPLES OF SYSTEMIC THERAPY****General Principles:**

- Systemic therapy is used in all stages of ampullary cancer. This could include neoadjuvant and adjuvant therapy for localized, potentially resectable disease, and first-line or subsequent therapy for locally advanced, metastatic, and recurrent disease.
- Systemic therapy type may depend on the histologic subtype of ampullary cancer: intestinal versus pancreatobiliary or mixed.
- For full systemic therapy options for intestinal type ampullary cancer, please review the [NCCN Guidelines for Colon Cancer](#) as related to adjuvant systemic therapy and therapy for metastatic disease. Where neoadjuvant chemotherapy is recommended, the same regimens for advanced/metastatic disease may be used.
- For full systemic therapy options for pancreatobiliary type and mixed histology type ampullary cancer, please review the [NCCN Guidelines for Hepatocellular Carcinoma](#), [NCCN Guidelines for Biliary Tract Cancers](#), and [NCCN Guidelines for Pancreatic Adenocarcinoma](#), as related to adjuvant systemic therapy and therapy for metastatic disease. Where neoadjuvant chemotherapy is recommended, the same regimens used for advanced/metastatic disease may be used.
- Goals of systemic therapy should be discussed with patients prior to initiation of therapy, and enrollment in a clinical trial is strongly encouraged.
- Close follow-up of patients undergoing chemotherapy is indicated.
- For regimens where RT or chemoradiation is included, see [Principles of Radiation Therapy \(AMP-F\)](#) for more details related to radiation delivery, including recommended technique and dose.
- To optimize the care of older adults, see the [NCCN Guidelines for Older Adult Oncology](#).

**Neoadjuvant Therapy (Localized Disease)**

- There is limited evidence to recommend neoadjuvant regimens for ampullary cancers, and most localized ampullary cancers are treated with surgery first.<sup>1</sup>
- If recommended, neoadjuvant regimens vary with regard to the use of chemotherapy and/or radiation. When considering neoadjuvant therapy, consultation at a high-volume center is preferred. Participation in a clinical trial, if available, is encouraged.

**Pancreatobiliary and Mixed Type**

- Fluorouracil (5-FU) + leucovorin + irinotecan + oxaliplatin (FOLFIRINOX)<sup>a,2</sup> or modified FOLFIRINOX<sup>a</sup> ± subsequent chemoradiation<sup>b,c</sup>
- Gemcitabine + albumin-bound paclitaxel ± subsequent chemoradiation<sup>b,c,d</sup>
- Gemcitabine + capecitabine ± subsequent chemoradiation<sup>b,c</sup>
- Gemcitabine + cisplatin ± subsequent chemoradiation<sup>b,c</sup>

**Intestinal Type**

- Capecitabine + oxaliplatin (CapeOx) ± subsequent chemoradiation<sup>b,c</sup>
- 5-FU + leucovorin + oxaliplatin (FOLFOX)<sup>3</sup> ± subsequent chemoradiation<sup>b,c</sup>
- FOLFIRINOX<sup>a</sup> ± subsequent chemoradiation<sup>b,c</sup>

<sup>a</sup> FOLFIRINOX or modified FOLFIRINOX should be limited to those with ECOG 0–1.<sup>b</sup> [Chemoradiation \(AMP-E 6 of 9\)](#).<sup>c</sup> If considering chemoradiation due to positive margins, chemotherapy should be given prior to the administration of chemoradiation.<sup>d</sup> Gemcitabine + albumin-bound paclitaxel is reasonable for patients with ECOG 0–2.**Note: All recommendations are category 2A unless otherwise indicated.****References**

**PRINCIPLES OF SYSTEMIC THERAPY**

**Adjuvant Therapy<sup>e,4</sup>**

- The ESPAC-3 trial demonstrated significant improvements in DFS and overall survival (OS) with use of postoperative gemcitabine or 5-fluorouracil (5-FU) as adjuvant chemotherapy versus observation in resectable ampullary adenocarcinoma.<sup>5</sup>
- ESPAC-3 study results showed no significant difference in OS between 5-FU/leucovorin versus gemcitabine following surgery. When the groups receiving adjuvant 5-FU/leucovorin and adjuvant gemcitabine were compared, median survival was 23.0 months and 23.6 months, respectively.<sup>5</sup>
- All chemotherapy regimens, with the exception of gemcitabine and 5-FU/leucovorin, which were studied in the phase 3 ESPAC-3 clinical trial, are based on retrospective or institutional prospective studies, or are based on the [NCCN Guidelines for Pancreatic Adenocarcinoma](#) and [NCCN Guidelines for Colorectal Cancer](#).
- For patients who received prior neoadjuvant therapy, the adjuvant therapy options are dependent on the response to neoadjuvant therapy and other clinical considerations.

**Pancreatobiliary and Mixed Type**

- Capecitabine<sup>6</sup>
- 5-FU + leucovorin (category 1)<sup>7</sup>
- FOLFOX<sup>8</sup>/CapeOx<sup>9</sup>
- Gemcitabine (category 1)<sup>7,10</sup>
- Gemcitabine + capecitabine<sup>11</sup>
- Gemcitabine + cisplatin<sup>12</sup>
- Modified FOLFIRINOX<sup>f,13</sup>

**Intestinal Type**

- Capecitabine<sup>5</sup>
- 5-FU + leucovorin (category 1)<sup>7</sup>
- FOLFOX<sup>8</sup>/CapeOx<sup>9,14</sup>

<sup>e</sup> For stage II and stage III resected disease, chemotherapy may be followed by chemoradiation.

<sup>f</sup> Modified FOLFIRINOX should be limited to those with ECOG 0–1.

**Note: All recommendations are category 2A unless otherwise indicated.**

[References](#)

**PRINCIPLES OF SYSTEMIC THERAPY****Metastatic Disease (First-Line Therapy)**

- Patients who progress with metastatic disease are not candidates for radiation unless required for palliative purposes.

	<b>Pancreatobiliary/Mixed Type</b>	<b>Intestinal Type</b>	<b>Targeted Systemic Therapies</b>
<b>Good PS<sup>g</sup></b>	<ul style="list-style-type: none"> <li>• FOLFOX</li> <li>• FOLFIRINOX<sup>a,15</sup> or modified FOLFIRINOX<sup>a,h,16</sup></li> <li>• Gemcitabine + albumin-bound paclitaxel<sup>17</sup></li> <li>• Gemcitabine + capecitabine<sup>18</sup></li> <li>• Gemcitabine + cisplatin<sup>12</sup></li> <li>• Gemcitabine + cisplatin + durvalumab<sup>k,19</sup></li> </ul>	<ul style="list-style-type: none"> <li>• CapeOx<sup>9</sup> ± bevacizumab<sup>i,21,22</sup></li> <li>• 5-FU + leucovorin + irinotecan (FOLFIRI)<sup>23</sup> ± bevacizumab<sup>i,23</sup></li> <li>• FOLFOX<sup>24</sup> ± bevacizumab<sup>i,22,25</sup></li> <li>• FOLFIRINOX<sup>a</sup> ± bevacizumab<sup>i,15,26</sup></li> </ul>	<b>Useful in Certain Circumstances:</b> <ul style="list-style-type: none"> <li>• Dabrafenib + trametinib (if <i>BRAF</i> V600E mutation-positive) (category 3)<sup>29,30</sup></li> <li>• Entrectinib (if <i>NTRK</i> gene fusion-positive)<sup>31,32</sup></li> <li>• Larotrectinib (if <i>NTRK</i> gene fusion-positive)<sup>33</sup></li> <li>• Repotrectinib (if <i>NTRK</i> gene fusion-positive)<sup>34</sup></li> <li>• Nivolumab + ipilimumab (if MSI-H or dMMR, for intestinal type only)<sup>k,35</sup></li> <li>• Pembrolizumab (if MSI-H, dMMR, or TMB-H [≥10 mut/Mb])<sup>k,36,37</sup></li> <li>• Selpercatinib (if <i>RET</i> gene fusion-positive)</li> </ul>
<b>Poor PS</b>	<ul style="list-style-type: none"> <li>• Capecitabine<sup>20</sup></li> <li>• 5-FU + leucovorin</li> <li>• Gemcitabine</li> </ul> <p>For select patients with ECOG 2 consider multi-agent regimens<sup>j</sup>:</p> <ul style="list-style-type: none"> <li>• FOLFOX</li> <li>• Gemcitabine + albumin-bound paclitaxel<sup>17</sup></li> </ul>	<ul style="list-style-type: none"> <li>• 5-FU + leucovorin<sup>27</sup></li> </ul> <p>For select patients with ECOG 2 consider multi-agent regimens<sup>j</sup>:</p> <ul style="list-style-type: none"> <li>• Capecitabine<sup>27</sup> ± bevacizumab<sup>i,28</sup></li> <li>• CapeOx<sup>9</sup> ± bevacizumab<sup>i,21,22</sup></li> <li>• 5-FU + leucovorin ± bevacizumab<sup>i</sup></li> <li>• FOLFIRI<sup>23</sup> ± bevacizumab<sup>i,23</sup></li> <li>• FOLFOX<sup>24</sup> ± bevacizumab<sup>i,22,25</sup></li> </ul>	<b>Useful in Certain Circumstances:</b> <ul style="list-style-type: none"> <li>• Dabrafenib + trametinib (if <i>BRAF</i> V600E mutation-positive) (category 2B)<sup>29,30</sup></li> <li>• Entrectinib (if <i>NTRK</i> gene fusion-positive)<sup>31,32</sup></li> <li>• Larotrectinib (if <i>NTRK</i> gene fusion-positive)<sup>33</sup></li> <li>• Repotrectinib (if <i>NTRK</i> gene fusion-positive)<sup>34</sup></li> <li>• Nivolumab + ipilimumab (if MSI-H or dMMR, for intestinal type only)<sup>k,35</sup></li> <li>• Pembrolizumab (if MSI-H, dMMR, or TMB-H [≥10 mut/Mb])<sup>k,36,37</sup></li> <li>• Selpercatinib (if <i>RET</i> gene fusion-positive)</li> </ul>

<sup>a</sup> FOLFIRINOX or modified FOLFIRINOX should be limited to those with ECOG 0–1.

<sup>g</sup> Defined as ECOG 0–1, with good biliary drainage and adequate nutritional intake.

<sup>h</sup> Due to the high toxicity of this regimen, bolus 5-FU is often omitted.

<sup>i</sup> An FDA-approved biosimilar is an appropriate substitute for bevacizumab.

<sup>j</sup> Consider dose or schedule adjustments as clinically indicated.

<sup>k</sup> [NCCN Guidelines for Management of Immunotherapy-Related Toxicities](#).

**Note: All recommendations are category 2A unless otherwise indicated.**

**References**

### PRINCIPLES OF SYSTEMIC THERAPY

#### Therapy for Disease Progression

	Pancreatobiliary/Mixed Type	Intestinal Type	Targeted Systemic Therapies	
Good PS <sup>9</sup>	<p>If prior gemcitabine-based therapy:</p> <ul style="list-style-type: none"> <li>• Capecitabine<sup>38</sup></li> <li>• CapeOx<sup>39</sup></li> <li>• 5-FU + leucovorin<sup>40</sup></li> <li>• 5-FU + leucovorin + liposomal irinotecan<sup>41</sup></li> <li>• FOLFIRI<sup>42-44</sup></li> <li>• FOLFIRINOX<sup>a,15,45</sup> or modified FOLFIRINOX<sup>a,h</sup></li> <li>• FOLFOX<sup>46</sup></li> <li>• Oxaliplatin + 5-FU + leucovorin (OFF)<sup>47</sup></li> </ul>	<p>If prior fluoropyrimidine-based therapy:</p> <ul style="list-style-type: none"> <li>• FOLFIRI or 5-FU + leucovorin + liposomal irinotecan (if no prior irinotecan)<sup>41-44</sup></li> <li>• Gemcitabine<sup>7,10</sup></li> <li>• Gemcitabine + albumin-bound paclitaxel<sup>17</sup></li> <li>• Gemcitabine + capecitabine<sup>18</sup></li> </ul> <p>If prior oxaliplatin therapy:</p> <ul style="list-style-type: none"> <li>• FOLFIRI or 5-FU + leucovorin + liposomal irinotecan (if no prior irinotecan)<sup>41-44</sup></li> </ul>	<p>If prior oxaliplatin-based therapy:</p> <ul style="list-style-type: none"> <li>• FOLFIRI ± bevacizumab<sup>i,23</sup></li> </ul>	<p>Useful in Certain Circumstances:</p> <ul style="list-style-type: none"> <li>• Dabrafenib + trametinib (if <i>BRAF</i> V600E mutation-positive)<sup>29,30</sup></li> <li>• Gemcitabine + cisplatin (only for known <i>BRCA1/2</i> mutations)<sup>12</sup></li> <li>• Entrectinib (if <i>NTRK</i> gene fusion-positive)<sup>31,32</sup></li> <li>• Larotrectinib (if <i>NTRK</i> gene fusion-positive)<sup>33</sup></li> <li>• Repotrectinib (if <i>NTRK</i> gene fusion-positive)<sup>34</sup></li> <li>• Adagrasib (if <i>KRAS</i> G12C mutation-positive)<sup>48</sup></li> <li>• Sotorasib (if <i>KRAS</i> G12C mutation-positive)<sup>49,50</sup></li> <li>• Selpercatinib (if <i>RET</i> gene fusion-positive)<sup>51</sup></li> </ul> <p>If no prior immunotherapy:</p> <ul style="list-style-type: none"> <li>• Dostarlimab-gxly (if MSI-H or dMMR)<sup>k,1,52</sup></li> <li>• Nivolumab + ipilimumab (if MSI-H or dMMR)<sup>k,35</sup></li> <li>• Pembrolizumab (if MSI-H, dMMR, or TMB-H [≥10 mut/Mb])<sup>k,36,37</sup></li> </ul>

<sup>a</sup> FOLFIRINOX or modified FOLFIRINOX should be limited to those with ECOG 0–1.

<sup>9</sup> Defined as ECOG 0–1, with good biliary drainage and adequate nutritional intake.

<sup>h</sup> Due to the high toxicity of this regimen, bolus 5-FU is often omitted.

<sup>i</sup> An FDA-approved biosimilar is an appropriate substitute for bevacizumab.

<sup>k</sup> [NCCN Guidelines for Management of Immunotherapy-Related Toxicities](#).

<sup>l</sup> For patients with recurrent or advanced tumors that have progressed on or following prior treatment and who have no satisfactory alternative treatment options. Patients who had received prior immune checkpoint inhibitor therapy were excluded from the dostarlimab-gxly clinical trial.

**Note: All recommendations are category 2A unless otherwise indicated.**

#### References



### PRINCIPLES OF SYSTEMIC THERAPY

#### Therapy for Disease Progression

	<u>Pancreatobiliary/Mixed Type</u>	<u>Intestinal Type</u>	<u>Targeted Systemic Therapies</u>
<b>Poor PS</b>	<ul style="list-style-type: none"> <li>• Capecitabine (category 2B)<sup>38</sup></li> <li>• 5-FU + leucovorin (category 2B)<sup>40</sup></li> <li>• Gemcitabine<sup>7,10</sup></li> </ul> <p>For select patients with ECOG 2 consider multi-agent regimens<sup>l</sup>:</p> <ul style="list-style-type: none"> <li>• CapeOX<sup>39</sup></li> <li>• FOLFIRI<sup>41-44</sup></li> <li>• FOLFOX<sup>46</sup></li> <li>• Gemcitabine + albumin-bound paclitaxel<sup>17</sup></li> </ul>	<ul style="list-style-type: none"> <li>• 5-FU + leucovorin<sup>53</sup></li> </ul> <p>For select patients with ECOG 2 consider multi-agent regimens<sup>l</sup> depending on the regimen used in first line:</p> <ul style="list-style-type: none"> <li>• Capecitabine ± bevacizumab<sup>i,28</sup></li> <li>• CapeOx<sup>9</sup> ± bevacizumab<sup>i,22</sup></li> <li>• 5-FU + leucovorin ± bevacizumab<sup>i,54,55</sup></li> <li>• FOLFIRI<sup>50</sup> ± bevacizumab<sup>i,23</sup></li> <li>• FOLFOX<sup>24</sup> ± bevacizumab<sup>i,22,56</sup></li> </ul>	<p>Useful in Certain Circumstances:</p> <ul style="list-style-type: none"> <li>• Dabrafenib + trametinib (if <i>BRAF</i> V600E mutation-positive)<sup>29,30</sup></li> <li>• Entrectinib (if <i>NTRK</i> gene fusion-positive)<sup>31,32</sup></li> <li>• Larotrectinib (if <i>NTRK</i> gene fusion-positive)<sup>33</sup></li> <li>• Repotrectinib (if <i>NTRK</i> gene fusion-positive)<sup>34</sup></li> <li>• Adagrasib (if <i>KRAS</i> G12C mutation-positive)<sup>48</sup></li> <li>• Sotorasib (if <i>KRAS</i> G12C mutation-positive)<sup>49,50</sup></li> <li>• Selpercatinib (if <i>RET</i> gene fusion-positive)<sup>51</sup></li> </ul> <p>If no prior immunotherapy:</p> <ul style="list-style-type: none"> <li>• Dostarlimab-gxly (if MSI-H or dMMR)<sup>k,l,52</sup></li> <li>• Nivolumab + ipilimumab (if MSI-H or dMMR)<sup>k,35</sup></li> <li>• Pembrolizumab (if MSI-H, dMMR, or TMB-H [≥10 mut/Mb])<sup>k,36,37</sup></li> </ul>

<sup>i</sup> An FDA-approved biosimilar is an appropriate substitute for bevacizumab.

<sup>j</sup> Consider dose or schedule adjustments as clinically indicated.

<sup>k</sup> [NCCN Guidelines for Management of Immunotherapy-Related Toxicities](#).

<sup>l</sup> For patients with recurrent or advanced tumors that have progressed on or following prior treatment and who have no satisfactory alternative treatment options. Patients who had received prior immune checkpoint inhibitor therapy were excluded from the dostarlimab-gxly clinical trial.

**Note: All recommendations are category 2A unless otherwise indicated.**

#### [References](#)



### PRINCIPLES OF SYSTEMIC THERAPY

#### Chemoradiation

##### Preferred Regimens: (Pancreatobiliary, Mixed, and Intestinal Types)

- Capecitabine + concurrent RT<sup>57,58</sup>
- 5-FU + concurrent RT<sup>59,60</sup>

##### Other Recommended Regimens: (Pancreatobiliary only)

- Gemcitabine + concurrent RT<sup>57,58</sup>

#### [References](#)

**Note: All recommendations are category 2A unless otherwise indicated.**



**PRINCIPLES OF SYSTEMIC THERAPY**  
**REFERENCES**

- <sup>1</sup> Guo M, Beal EW, Miller ED, et al. Neoadjuvant therapy versus surgery first for ampullary carcinoma: A propensity score-matched analysis of the NCDB. *J Surg Oncol* 2021;123:1558-1567.
- <sup>2</sup> Ghaneh P, Palmer D, Cicconi S, et al. Immediate surgery compared with short-course neoadjuvant gemcitabine plus capecitabine, FOLFIRINOX, or chemoradiotherapy in patients with borderline resectable pancreatic cancer (ESPAC5): a four-arm, multicentre, randomised, phase 2 trial. *Lancet Gastroenterol Hepatol* 2023;8:157-168.
- <sup>3</sup> Morton D, Seymour M, Magill L, et al. Preoperative chemotherapy for operable colon cancer: Mature results of an international randomized controlled trial. *J Clin Oncol* 2023;41:1541-1552.
- <sup>4</sup> Nassour I, Hynan LS, Christie A, et al. Association of adjuvant therapy with improved survival in ampullary cancer: A national cohort study. *J Gastrointest Surg* 2018;22:695-702.
- <sup>5</sup> Twelves C, Wong A, Nowacki MP, et al. Capecitabine as adjuvant treatment for stage III colon cancer. *N Engl J Med* 2005;352:2696-2704.
- <sup>6</sup> Primrose JN, Fox RP, Palmer DH, et al. Capecitabine compared with observation in resected biliary tract cancer (BILCAP): a randomised, controlled, multicentre, phase 3 study [published correction appears in *Lancet Oncol* 2019;20:663-673]. *Lancet Oncol* 2019;20:663-673.
- <sup>7</sup> Neoptolemos JP, Moore MJ, Cox TF, et al. Effect of adjuvant chemotherapy with fluorouracil plus folinic acid or gemcitabine vs observation on survival in patients with resected periampullary adenocarcinoma: the ESPAC-3 periampullary cancer randomized trial [published correction appears in *JAMA* 2012;308:1861]. *JAMA* 2012;308:147-156.
- <sup>8</sup> André T, Boni C, Mounedji-Boudiaf L, et al. Oxaliplatin, fluorouracil, and leucovorin as adjuvant treatment for colon cancer. *N Engl J Med* 2004;350:2343-2351.
- <sup>9</sup> Overman MJ, Varadhachary GR, Kopetz S, et al. Phase II study of capecitabine and oxaliplatin for advanced adenocarcinoma of the small bowel and ampulla of Vater. *J Clin Oncol* 2009;27:2598-2603.
- <sup>10</sup> Oettle H, Neuhaus P, Hochhaus A, et al. Adjuvant chemotherapy with gemcitabine and long-term outcomes among patients with resected pancreatic cancer: the CONKO-001 randomized trial. *JAMA* 2013;310:1473-1481.
- <sup>11</sup> Neoptolemos JP, Palmer DH, Ghaneh P, et al. Comparison of adjuvant gemcitabine and capecitabine with gemcitabine monotherapy in patients with resected pancreatic cancer (ESPAC-4): a multicentre, open-label, randomised, phase 3 trial. *Lancet* 2017;389:1011-1024.
- <sup>12</sup> Valle J, Wasan H, Palmer DH, et al. Cisplatin plus gemcitabine versus gemcitabine for biliary tract cancer. *N Engl J Med* 2010;362:1273-1281.
- <sup>13</sup> Conroy T, Hammel P, Hebbar M, et al. FOLFIRINOX or gemcitabine as adjuvant therapy for pancreatic cancer. *N Engl J Med* 2018;379:2395-2406.
- <sup>14</sup> Haller DG, Tabernero J, Maroun J, et al. Capecitabine plus oxaliplatin compared with fluorouracil and folinic acid as adjuvant therapy for stage III colon cancer. *J Clin Oncol* 2011;29:1465-1471.
- <sup>15</sup> Conroy T, Desseigne F, Ychou M, et al. FOLFIRINOX versus gemcitabine for metastatic pancreatic cancer. *N Engl J Med* 2011;364:1817-1825.
- <sup>16</sup> Stein SM, James ES, Deng Y, et al. Final analysis of a phase II study of modified FOLFIRINOX in locally advanced and metastatic pancreatic cancer. *Br J Cancer* 2016;114:737-743.
- <sup>17</sup> Von Hoff DD, Ervin T, Arena FP, et al. Increased survival in pancreatic cancer with nab-paclitaxel plus gemcitabine. *N Engl J Med* 2013;369:1691-1703.
- <sup>18</sup> Cunningham D, Chau I, Stocken DD, et al. Phase III randomized comparison of gemcitabine versus gemcitabine plus capecitabine in patients with advanced pancreatic cancer. *J Clin Oncol* 2009;27:5513-5518.
- <sup>19</sup> Oh D-Y, Ruth He A, Qin S, et al. Durvalumab plus Gemcitabine and Cisplatin in Advanced Biliary Tract Cancer. *NEJM Evidence* 2022;1:EVIDoa2200015.
- <sup>20</sup> Cartwright TH, Cohn A, Varkey JA, et al. Phase II study of oral capecitabine in patients with advanced or metastatic pancreatic cancer. *J Clin Oncol* 2002;20:160-164.
- <sup>21</sup> Gulhati P, Raghav K, Shroff RT, et al. Bevacizumab combined with capecitabine and oxaliplatin in patients with advanced adenocarcinoma of the small bowel or ampulla of Vater: A single-center, open-label, phase 2 study. *Cancer* 2017;123:1011-1017.

**Note: All recommendations are category 2A unless otherwise indicated.**[Continued](#)



**PRINCIPLES OF SYSTEMIC THERAPY**  
**REFERENCES**

- <sup>22</sup> Saltz LB, Clarke S, Díaz-Rubio E, et al. Bevacizumab in combination with oxaliplatin-based chemotherapy as first-line therapy in metastatic colorectal cancer: a randomized phase III study [published correction appears in *J Clin Oncol* 2008;26:3110] [published correction appears in *J Clin Oncol* 2009;27:653]. *J Clin Oncol* 2008;26:2013-2019.
- <sup>23</sup> Fuchs CS, Marshall J, Mitchell E, et al. Randomized, controlled trial of irinotecan plus infusional, bolus, or oral fluoropyrimidines in first-line treatment of metastatic colorectal cancer: results from the BICC-C Study. *J Clin Oncol* 2007;25:4779-4786.
- <sup>24</sup> Cheeseman SL, Joel SP, Chester JD, et al. A 'modified de Gramont' regimen of fluorouracil, alone and with oxaliplatin, for advanced colorectal cancer. *Br J Cancer* 2002;87:393-399.
- <sup>25</sup> Venook AP, Niedzwiecki D, Lenz HJ, et al. Effect of first-line chemotherapy combined with cetuximab or bevacizumab on overall survival in patients with KRAS wild-type advanced or metastatic colorectal cancer: A randomized clinical trial. *JAMA* 2017;317:2392-2401.
- <sup>26</sup> Falcone A, Ricci S, Brunetti I, et al. Phase III trial of infusional fluorouracil, leucovorin, oxaliplatin, and irinotecan (FOLFOXIRI) compared with infusional fluorouracil, leucovorin, and irinotecan (FOLFIRI) as first-line treatment for metastatic colorectal cancer: the Gruppo Oncologico Nord Ovest. *J Clin Oncol* 2007;25:1670-1676.
- <sup>27</sup> Van Cutsem E, Twelves C, Cassidy J, et al. Oral capecitabine compared with intravenous fluorouracil plus leucovorin in patients with metastatic colorectal cancer: results of a large phase III study. *J Clin Oncol* 2001;19:4097-4106.
- <sup>28</sup> Cunningham D, Lang I, Marcuello E, et al. Bevacizumab plus capecitabine versus capecitabine alone in elderly patients with previously untreated metastatic colorectal cancer (AVEX): an open-label, randomised phase 3 trial. *Lancet Oncol* 2013;14:1077-1085.
- <sup>29</sup> Salama AKS, Li S, Macrae ER, et al. Dabrafenib and trametinib in patients with tumors with BRAF V600E mutations: Results of the NCI-MATCH trial subprotocol H. *J Clin Oncol* 2020;38:3895-3904.
- <sup>30</sup> Subbiah V, Lassen U, Élez E, et al. Dabrafenib plus trametinib in patients with BRAFV600E-mutated biliary tract cancer (ROAR): a phase 2, open-label, single-arm, multicentre basket trial. *Lancet Oncol* 2020;21:1234-1243.
- <sup>31</sup> Doebele RC, Drlon A, Paz-Ares L, et al. Entrectinib in patients with advanced or metastatic NTRK fusion-positive solid tumours: integrated analysis of three phase 1-2 trials. *Lancet Oncol* 2020;21:271-282.
- <sup>32</sup> Drlon A, Siena S, Ou SI, et al. Safety and antitumor activity of the multitargeted Pan-TRK, ROS1, and ALK inhibitor entrectinib: Combined results from two phase I trials (ALKA-372-001 and STARTRK-1). *Cancer Discov* 2017;7:400-409.
- <sup>33</sup> Drlon A, Laetsch TW, Kummar S, et al. Efficacy of larotrectinib in TRK fusion-positive cancers in adults and children. *N Engl J Med* 2018;378:731-739.
- <sup>34</sup> Solomon BJ, Drlon A, Lin JJ, et al. Repotrectinib in patients with NTRK fusion-positive advanced solid tumors, including non-small cell lung cancer: update from the phase 1/2 TRIDENT-1 trial. *Ann Oncol*. 2023;34:S787-S788.
- <sup>35</sup> Overman MJ, Lonardi S, Wong KYM, et al. Durable clinical benefit with nivolumab plus ipilimumab in DNA mismatch repair-deficient/microsatellite instability-high metastatic colorectal cancer. *J Clin Oncol* 2018;36:773-779.
- <sup>36</sup> Marabelle A, Le DT, Ascierto PA, et al. Efficacy of pembrolizumab in patients with noncolorectal high microsatellite instability/mismatch repair-deficient cancer: results from the phase 2 KEYNOTE-158 study. *J Clin Oncol* 2020;38:1-10.
- <sup>37</sup> Lala M, Li TR, de Alwis DP, et al. A six-weekly dosing schedule for pembrolizumab in patients with cancer based on evaluation using modelling and simulation [published correction appears in *Eur J Cancer* 2021;144:400]. *Eur J Cancer* 2020;131:68-75.
- <sup>38</sup> Patt YZ, Hassan MM, Aguayo A, et al. Oral capecitabine for the treatment of hepatocellular carcinoma, cholangiocarcinoma, and gallbladder carcinoma. *Cancer* 2004;101:578-586.
- <sup>39</sup> Xiong HQ, Varadhachary GR, Blais JC, Hess KR, Abbruzzese JL, Wolff RA. Phase 2 trial of oxaliplatin plus capecitabine (XELOX) as second-line therapy for patients with advanced pancreatic cancer. *Cancer* 2008;113:2046-2052.
- <sup>40</sup> Gill S, Ko YJ, Cripps C, et al. PANCREOX: A randomized phase III study of fluorouracil/leucovorin with or without oxaliplatin for second-line advanced pancreatic cancer in patients who have received gemcitabine-based chemotherapy. *J Clin Oncol* 2016;34:3914-3920.

**Note: All recommendations are category 2A unless otherwise indicated.**[Continued](#)

**PRINCIPLES OF SYSTEMIC THERAPY**  
**REFERENCES**

- 41 Wang-Gillam A, Li CP, Bodoky G, et al. Nanoliposomal irinotecan with fluorouracil and folinic acid in metastatic pancreatic cancer after previous gemcitabine-based therapy (NAPOLI-1): a global, randomised, open-label, phase 3 trial. *Lancet* 2016;387:545-557.
- 42 Neuzillet C, Hentic O, Rousseau B, et al. FOLFIRI regimen in metastatic pancreatic adenocarcinoma resistant to gemcitabine and platinum-salts. *World J Gastroenterol* 2012;18:4533-4541.
- 43 Zaniboni A, Aitini E, Barni S, et al. FOLFIRI as second-line chemotherapy for advanced pancreatic cancer: a GISCAD multicenter phase II study. *Cancer Chemother Pharmacol* 2012;69:1641-1645.
- 44 Chiorean EG, Guthrie KA, Philip PA, et al. Randomized phase II study of PARP inhibitor ABT-888 (veliparib) with modified FOLFIRI versus FOLFIRI as second-line treatment of metastatic pancreatic cancer: SWOG S1513. *Clin Cancer Res* 2021;27:6314-6322.
- 45 Chiorean EG, Von Hoff DD, Tabernero J, et al. Second-line therapy after nab-paclitaxel plus gemcitabine or after gemcitabine for patients with metastatic pancreatic cancer [published correction appears in *Br J Cancer* 2016;115:e13]. *Br J Cancer* 2016;115:188-194.
- 46 Lamarca A, Palmer DH, Wasan HS, et al. Second-line FOLFOX chemotherapy versus active symptom control for advanced biliary tract cancer (ABC-06): a phase 3, open-label, randomised, controlled trial. *Lancet Oncol* 2021;22:690-701.
- 47 Pelzer U, Schwaner I, Stieler J, et al. Best supportive care (BSC) versus oxaliplatin, folinic acid and 5-fluorouracil (OFF) plus BSC in patients for second-line advanced pancreatic cancer: a phase III-study from the German CONKO-study group. *Eur J Cancer* 2011;47:1676-1681.
- 48 Ou SI, Jänne PA, Leal TA, et al. First-in-Human Phase I/IB Dose-Finding Study of Adagrasib (MRTX849) in Patients With Advanced KRASG12C Solid Tumors (KRYSTAL-1). *J Clin Oncol*. 2022 Aug 10;40(23):2530-2538.
- 49 Hong DS, Fakih MG, Strickler JH, et al. KRASG12C Inhibition with Sotorasib in Advanced Solid Tumors. *N Engl J Med*. 2020 Sep 24;383(13):1207-1217.
- 50 Strickler JH, Satake H, George TJ, et al. Sotorasib in KRAS p.G12C-Mutated Advanced Pancreatic Cancer. *N Engl J Med*. 2023 Jan 5;388(1):33-43.
- 51 Subbiah V, Wolf J, Konda B, et al. Tumour-agnostic efficacy and safety of selpercatinib in patients with RET fusion-positive solid tumours other than lung or thyroid tumours (LIBRETTO-001): a phase 1/2, open-label, basket trial. *Lancet Oncol* 2022;23:1261-1273.
- 52 André T, Berton D, Curigliano G, et al. Antitumor activity and safety of dostarlimab monotherapy in patients with mismatch repair deficient solid tumors: A nonrandomized controlled trial. *JAMA Netw Open* 2023;6:e2341165.
- 53 Andre T, Louvet C, Maindrault-Goebel F, et al. CPT-11 (irinotecan) addition to bimonthly, high-dose leucovorin and bolus and continuous-infusion 5-fluorouracil (FOLFIRI) for pretreated metastatic colorectal cancer. GERCOR. *Eur J Cancer* 1999;35:1343-1347.
- 54 Rothenberg ML, Oza AM, Bigelow RH, et al. Superiority of oxaliplatin and fluorouracil-leucovorin compared with either therapy alone in patients with progressive colorectal cancer after irinotecan and fluorouracil-leucovorin: interim results of a phase III trial. *J Clin Oncol* 2003;21:2059-2069.
- 55 Rougier P, Van Cutsem E, Bajetta E, et al. Randomised trial of irinotecan versus fluorouracil by continuous infusion after fluorouracil failure in patients with metastatic colorectal cancer [published correction appears in *Lancet* 1998;352:1634]. *Lancet* 1998;352:1407-1412.
- 56 Takayoshi K, Kusaba H, Uenomachi M, et al. Suggestion of added value by bevacizumab to chemotherapy in patients with unresectable or recurrent small bowel cancer. *Cancer Chemother Pharmacol* 2017;80:333-342.
- 57 Hurt CN, Falk S, Crosby T, et al. Long-term results and recurrence patterns from SCALOP: a phase II randomised trial of gemcitabine- or capecitabine-based chemoradiation for locally advanced pancreatic cancer. *Br J Cancer* 2017;116:1264-1270.
- 58 Hurt CN, Mukherjee S, Bridgewater J, et al. Health-related quality of life in SCALOP, a randomized phase 2 trial comparing chemoradiation therapy regimens in locally advanced pancreatic cancer. *Int J Radiat Oncol Biol Phys* 2015;93:810-818.
- 59 Mehta VK, Fisher GA, Ford JM, et al. Adjuvant chemoradiotherapy for "unfavorable" carcinoma of the ampulla of Vater: preliminary report. *Arch Surg* 2001;136:65-69.
- 60 Bhatia S, Miller RC, Haddock MG, Donohue JH, Krishnan S. Adjuvant therapy for ampullary carcinomas: the Mayo Clinic experience. *Int J Radiat Oncol Biol Phys* 2006;66:514-519.

**Note: All recommendations are category 2A unless otherwise indicated.**



### PRINCIPLES OF RADIATION THERAPY

#### **General Principles:**

- Patients with ampullary cancer are best treated by a multidisciplinary team.
- Prior to initiation of RT, staging is optimally determined with a contrast-enhanced abdominal CT (3D conformal RT [3D-CRT]) and/or MRI.
- Recommendations for RT for patients with ampullary cancer are typically made based on four clinical scenarios:
  - ▶ Localized disease (neoadjuvant/adjuvant)
  - ▶ Locally advanced disease
  - ▶ Recurrent disease
  - ▶ Palliative care
- In these scenarios, the goal of delivering RT is to sterilize vessel margins, enhance the likelihood of a margin-negative resection, and/or provide adequate local control to prevent or delay progression or prevent local disease recurrence while minimizing the risk of RT exposure to surrounding organs at risk (OARs). Radiation can also be used to palliate pain and bleeding or relieve obstructive symptoms in patients who have progressed or recurred locally.

#### [References](#)

**Note: All recommendations are category 2A unless otherwise indicated.**



### PRINCIPLES OF RADIATION THERAPY TREATMENT PLANNING: RADIATION DELIVERY

#### Simulation:

- For ampullary cancer, placement of fiducial markers may be useful for targeting purposes. Placement of fiducial markers directly into the tumor and/or periphery under EUS is preferred. Stents can assist with targeting; however, they can shift and are therefore less reliable than fiducials. In the adjuvant setting strategically placed surgical clips may serve a similar purpose.
- Position patient supine with arms up in an immobilization device that will be custom-made for each patient. The simulation scan range should include the target structures and OARs.
- CT simulation (2- to 3-mm slices) is often performed with IV contrast (assuming adequate kidney function) and oral contrast may also be used. Multiphase IV contrast delivery may facilitate disease delineation. MRI may be complementary to CT in target delineation.
- Simulation and treatment of patient with nothing by mouth (NPO) may facilitate setup reproducibility. If the patient receives oral contrast, consider giving the same volume of water prior to treatment each day to mimic simulation anatomy.

#### Motion Management<sup>1</sup>:

- A motion management strategy should be considered.
- Respiratory motion should be accounted for in determining the internal target volume (ITV). These strategies may include using a four-dimensional computed tomography (4D-CT) scan, respiratory gating, breath-hold, respiratory tracking, or abdominal compression.

#### Planning, Dose, and Fractionation:

- 3D-CRT, intensity-modulated RT (IMRT), and stereotactic body RT (SBRT) can result in improved planning target volume (PTV) coverage with decreased dose to OARs.<sup>2,3</sup> The exact planning strategy used should be individualized to patient anatomy, clinical scenario, treatment goals, and dose goals.
- It is imperative to evaluate the dose-volume histogram (DVH) of the target structures and the critical OARs such as the duodenum, stomach, liver, kidneys, spinal cord, and bowel. See Table 1. Normal Tissue Dose Volume Recommendations for Chemoradiation Utilizing Conventional Fractionation ([AMP-F 5 of 6](#)). No definitive dose constraints for SBRT currently exist; however, they are emerging and are dependent on a variety of factors including dose per fraction and total dose.
- While these examples of limits are empirical they differ based on dose per fraction, total dose delivered, and disease status (adjuvant vs. unresectable).

#### References

Note: All recommendations are category 2A unless otherwise indicated.

**PRINCIPLES OF RADIATION THERAPY  
RECOMMENDATIONS BASED ON TREATMENT SETTING<sup>a</sup>****Localized Disease:**

- Data are limited to support specific treatment options for localized ampullary cancer; most data supporting the role of RT in this setting are in the adjuvant setting.
- Neoadjuvant therapy may facilitate margin-negative resection in more advanced cases and may improve OS, but ideally should be conducted as a clinical trial ([Principles of Systemic Therapy \[AMP-E\]](#)).
- The optimal timing for surgical resection following neoadjuvant RT has not been firmly established.
- RT Dosing/Planning:
  - ▶ For chemoradiation, the following RT doses have been reported: 45–54 Gy in 1.8–2.0 Gy fractions (in 25–30 total fractions) (doses higher than 54 Gy may be considered in a clinical trial).
  - ▶ Elective nodal irradiation (ENI) is usually recommended for localized/locally advanced disease.

**Neoadjuvant/Adjuvant<sup>b,4</sup>:**

- After resection, patients often receive adjuvant RT for one or more features that portend high risk for local recurrence (eg,  $\geq T3$ , positive nodes, positive margins, poor differentiation, perineural/perivascular invasion).
- If no prior neoadjuvant therapy and no evidence of recurrence or metastatic disease after resection, RT is included in the following adjuvant therapy option:
  - ▶ Adjuvant chemotherapy followed by chemoradiation  $\pm$  subsequent chemotherapy ([Principles of Systemic Therapy \[AMP-E\]](#)).

**Neoadjuvant/Adjuvant (continued)<sup>b,4</sup>:**

- RT Dosing/Planning:
  - ▶ For chemoradiation, RT dose generally consists of 45–50.4 Gy in 1.8–2.0 Gy fractions (in 25–28 total fractions) to the tumor bed, surgical anastomoses (hepaticojejunostomy and gastrojejunostomy may be omitted if clinically appropriate), and adjacent lymph node basins, with potential dose escalation to the high-risk regions, if clinically appropriate. Careful attention to the bowel and stomach dose is warranted and normal tissue dose constraints should always be considered.
  - ▶ Several pancreatic clinical trials (RTOG) now refer to atlases to assist with contouring and adjuvant RT planning: (<https://www.nrgoncology.org/About-Us/Center-for-Innovation-in-Radiation-Oncology>). Target design is similar in ampullary cancers.
  - ▶ Preoperative CT scans and strategically placed surgical clips may be used to determine the tumor bed, ideally with the surgeon's assistance.

**Locally Advanced:**

- ▶ Albeit rare, the goal of RT is to prevent or delay local progression (that may result in pain or local obstructive symptoms) and facilitate local disease control, and in some instances help facilitate R0 resection in patients considered for surgery.
- ▶ Data are limited to support specific RT recommendations for locally advanced disease. Options may include:
  - ◊ Chemoradiation if not a candidate for combination chemotherapy.
  - ◊ Induction chemotherapy followed by chemoradiation in select patients (locally advanced without systemic metastases).
- ▶ RT Dosing/Planning:
  - ◊ For chemoradiation, RT dose generally consists of 45–54 Gy in 1.8–2.0 Gy fractions (in 25–30 total fractions).

<sup>a</sup> It is not known whether one regimen is necessarily more effective than another in the four clinical scenarios mentioned above. Therefore, the following recommendations are given as examples of commonly used regimens. However, other recommendations based on similar principles are acceptable.

<sup>b</sup> Adjuvant options listed apply only to patients who did not receive prior neoadjuvant therapy. For those who received prior neoadjuvant therapy, the adjuvant therapy options are dependent on the response to neoadjuvant therapy and other clinical considerations.

**Note: All recommendations are category 2A unless otherwise indicated.**

**References**



### PRINCIPLES OF RADIATION THERAPY RECOMMENDATIONS BASED ON TREATMENT SETTING

#### **Recurrent Ampullary Cancer (resection bed):**

- **Data are limited to support specific RT recommendations for locally recurrent ampullary cancer; the options for patients with recurrent, unresectable disease may include:**
  - ▶ **Chemoradiation<sup>5</sup> in selected patients who are not candidates for induction chemotherapy.**
  - ▶ **Induction chemotherapy followed by chemoradiation or SBRT ([Principles of Systemic Therapy \[AMP-E\]](#)).**
- **RT Dosing/Planning:**
  - ▶ **For chemoradiation, RT dose generally consists of 45–54 Gy in 1.8–2.0 Gy fractions (in 25–30 total fractions).**
  - ▶ **There are limited data to support a specific RT dosing for SBRT<sup>c</sup>; therefore, for recurrent ampullary cancer, it should be used as part of a clinical trial or at an experienced, high-volume center.**
  - ▶ **However, caution is warranted when using higher doses and normal tissue constraints must be respected. This approach is optimally performed in the setting of a clinical trial.**

<sup>c</sup> SBRT should be delivered at an experienced, high-volume center with technology that allows for image-guided RT or in a clinical trial. SBRT should be avoided if direct invasion of the bowel or stomach is observed on CT, MRI, and/or endoscopy.

**Note: All recommendations are category 2A unless otherwise indicated.**

#### [References](#)



**PRINCIPLES OF RADIATION THERAPY****Palliative**

- The goal of palliative RT is often to relieve pain and bleeding and/or ameliorate local obstructive symptoms in patients with non-metastatic or metastatic disease. See [Principles of Palliation and Supportive Care \(AMP-G\)](#).
  - ▶ **Non-Metastatic Disease:** Palliative RT can be considered for patients who are older and/or not candidates for definitive therapy due to poor PS or comorbidities.
  - ▶ **Metastatic Disease:**
    - ◊ Metastatic sites causing pain (ie, osseous) may be palliated with a short course of RT. SBRT may be used in select cases for metastatic sites, including oligometastatic disease.
    - ◊ RT is reasonable for patients with metastatic disease who require local palliation for symptoms such as obstruction, pain refractory to analgesic therapy, or bleeding.
- RT Dosing/Planning:
  - ▶ Palliative RT is commonly used, although specific dose and fractionation recommendations should take into account burden of metastatic disease, normal tissue tolerance, and expected survival.

**Table 1: Normal Tissue Dose Volume Recommendations for Chemoradiation Utilizing Conventional Fractionation**

Organs at Risk (OARs)	Neoadjuvant/Definitive/Palliative and Recurrent Recommendations <sup>d</sup>	Adjuvant Recommendations <sup>e</sup>
Kidney (right and left)	Not more than 30% of the total volume can receive $\geq 18$ Gy. If only one kidney is functional, not more than 10% of the volume can receive $\geq 18$ Gy.	For 3D-CRT plans in patients with two normally functioning kidneys, at least 50% of the right kidney and at least 65% of the left kidney must receive $< 18$ Gy. For IMRT planning, mean dose to bilateral kidneys must be $< 18$ Gy. If only one kidney is present, not more than 15% of the volume of that kidney can receive $\geq 18$ Gy and not more than 30% can receive $\geq 14$ Gy.
Stomach, duodenum, and jejunum	Max dose 55 Gy.	Max dose $\leq 54$ Gy; $< 10\%$ of each organ volume can receive between 50 and 53.99 Gy; $< 15\%$ of the volume of each organ can receive between 45 and 49.99 Gy.
Liver	Mean dose cannot exceed 30 Gy.	Mean liver dose must be $\leq 25$ Gy.
Spinal cord	Max dose to a volume of at least 0.03 cc must be $\leq 45$ Gy.	Max dose $\leq 45$ Gy.

<sup>d</sup> Adapted from RTOG 1102 (IMRT, 2.2–54 Gy).<sup>e</sup> Adapted from RTOG 0848 (3D or IMRT).**Note: All recommendations are category 2A unless otherwise indicated.**[References](#)



### PRINCIPLES OF RADIATION THERAPY REFERENCES

- <sup>1</sup> Keall PJ, Mageras GS, Balter JM, et al. The management of respiratory motion in radiation oncology report of AAPM task group 76. *Med Phys* 2006;33:3874-3900.
- <sup>2</sup> Spalding AC, Jee KW, Vineberg K, et al. Potential for dose-escalation and reduction of risk in pancreatic cancer using IMRT optimization with lexicographic ordering and gEUD-based cost functions. *Med Phys* 2007;34:521-529.
- <sup>3</sup> Yovino S, Poppe M, Jabbour S, et al. Intensity-modulated radiation therapy significantly improves acute gastrointestinal toxicity in pancreatic and ampullary cancers. *Int J Radiat Oncol Biol Phys* 2011;79:158-162.
- <sup>4</sup> Jabbour SK, Mulvihill D. Defining the role of adjuvant therapy: ampullary and duodenal adenocarcinoma. *Semin Radiat Oncol* 2014;24:85-93.
- <sup>5</sup> Huguet F, Girard N, Guerche CS, et al. Chemoradiotherapy in the management of locally advanced pancreatic carcinoma: A qualitative systematic review. *J Clin Oncol* 2009;27:2269-2277.

**Note: All recommendations are category 2A unless otherwise indicated.**



**PRINCIPLES OF PALLIATION AND SUPPORTIVE CARE<sup>a</sup>****Objective:** Prevent and ameliorate suffering while ensuring optimal quality of life.

Symptom	Therapy
Biliary obstruction	<ul style="list-style-type: none"> <li>• Endoscopic biliary metal stent (preferred method)</li> <li>• Percutaneous biliary drainage with subsequent internalization</li> <li>• Open biliary-enteric bypass</li> </ul>
Gastric outlet/duodenal obstruction	<ul style="list-style-type: none"> <li>• Good PS <ul style="list-style-type: none"> <li>▶ Gastrojejunostomy (open or laparoscopic) ± G/J-tube</li> <li>▶ Consider enteral stent<sup>a</sup></li> </ul> </li> <li>• Poor PS <ul style="list-style-type: none"> <li>▶ Venting percutaneous endoscopic gastrostomy (PEG) tube for gastric decompression</li> <li>▶ Enteral stent<sup>a</sup></li> </ul> </li> </ul>
Thromboembolic disease <sup>b</sup>	<ul style="list-style-type: none"> <li>• Low-molecular-weight heparin preferred over warfarin<sup>c</sup></li> <li>• Consider direct oral anticoagulants for patients without luminal tumors</li> </ul>
Bleeding from the primary tumor site	<ul style="list-style-type: none"> <li>• Therapeutic endoscopy, if clinically indicated</li> <li>• RT, if not previously done</li> <li>• Angiography with embolization, if clinically indicated</li> </ul>
Pain ( <a href="#">NCCN Guidelines for Adult Cancer Pain</a> )	<ul style="list-style-type: none"> <li>• Early referral to pain or palliative care specialist to determine the best treatment option</li> <li>• Opioids with or without neurolysis</li> <li>• EUS-guided celiac plexus neurolysis (fluoroscopic- or CT-guided if unavailable)</li> <li>• Celiac plexus radiation/radiosurgery<sup>d</sup></li> <li>• SBRT</li> <li>• Severe tumor-associated abdominal pain unresponsive to optimal, around-the-clock analgesic administration, or if the patient experiences undesirable analgesic-associated side effects <ul style="list-style-type: none"> <li>▶ High-intensity focused ultrasound</li> <li>▶ Consider palliative radiation with or without chemotherapy if not already given as part of the primary therapy regimen. See <a href="#">Principles of Radiation Therapy (AMP-F)</a>.</li> <li>▶ Intrathecal drug delivery</li> </ul> </li> </ul>
Depression and malnutrition ( <a href="#">NCCN Guidelines for Supportive Care</a> )	<ul style="list-style-type: none"> <li>• Formal Palliative Medicine Service evaluation when available<sup>e,f</sup></li> <li>• Nutritional evaluation with a registered dietitian when available</li> <li>• Pancreatic enzyme replacement in the case of exocrine pancreatic insufficiency</li> </ul>

<sup>a</sup> Placement of an enteral stent is particularly important for patients with poor PS and should be done after biliary drainage is assured.<sup>b</sup> [NCCN Guidelines for Cancer-Associated Venous Thromboembolic Disease](#).<sup>c</sup> A randomized trial examining the effects of prophylactic low-molecular-weight heparin showed a decrease in venous thromboembolism but no effect on survival (Pelzer U, et al. J Clin Oncol 2015;33:2028-2034).<sup>d</sup> Yaacov RL, et al. J Clin Oncol 2023;41:(Suppl): Abstract 662; Jacobson G, et al. BMJ Open 2022;12:e050169.<sup>e</sup> Palliative surgical procedures are best reserved for patients with a longer life expectancy.<sup>f</sup> Consider encouraging advanced care planning.**Note: All recommendations are category 2A unless otherwise indicated.**



**Table 1. Definitions for T, N, M**  
**American Joint Committee on Cancer (AJCC) TNM Staging of Ampulla of Vater (8th ed., 2017)**

<b>T</b>	<b>Primary Tumor</b>
<b>TX</b>	Primary tumor cannot be assessed
<b>T0</b>	No evidence of primary tumor
<b>Tis</b>	Carcinoma <i>in situ</i>
<b>T1</b>	Tumor limited to ampulla of Vater or sphincter of Oddi or tumor invades beyond the sphincter of Oddi (perisphincteric invasion) and/or into the duodenal submucosa
T1a	Tumor limited to ampulla of Vater or sphincter of Oddi
T1b	Tumor invades beyond the sphincter of Oddi (perisphincteric invasion) and/or into the duodenal submucosa
<b>T2</b>	Tumor invades into the muscularis propria of the duodenum
<b>T3</b>	Tumor directly invades the pancreas (up to 0.5 cm) or tumor extends more than 0.5 cm into the pancreas, or extends into peripancreatic or periduodenal tissue or duodenal serosa without involvement of the celiac axis or superior mesenteric artery
T3a	Tumor directly invades pancreas (up to 0.5 cm)
T3b	Tumor extends more than 0.5 cm into the pancreas, or extends into peripancreatic tissue or periduodenal tissue or duodenal serosa without involvement of the celiac axis or superior mesenteric artery
<b>T4</b>	Tumor involves the celiac axis, superior mesenteric artery, and/or common hepatic artery, irrespective of size
<b>N</b>	<b>Regional Lymph Nodes</b>
<b>NX</b>	Regional lymph nodes cannot be assessed
<b>N0</b>	No regional lymph node metastasis
<b>N1</b>	Metastasis to one to three regional lymph nodes
<b>N2</b>	Metastasis to four or more regional lymph nodes

<b>M</b>	<b>Distant Metastasis</b>
<b>M0</b>	No distant metastasis
<b>M1</b>	Distant metastasis

**Table 2. AJCC Prognostic Groups**

	<b>T</b>	<b>N</b>	<b>M</b>
<b>Stage 0</b>	Tis	N0	M0
<b>Stage IA</b>	T1a	N0	M0
<b>Stage IB</b>	T1b, T2	N0	M0
<b>Stage IIA</b>	T3a	N0	M0
<b>Stage IIB</b>	T3b	N0	M0
<b>Stage IIIA</b>	T1a, T1b, T2, T3a, T3b	N1	M0
<b>Stage IIIB</b>	T4	Any N	M0
	Any T	N2	M0
<b>Stage IV</b>	Any T	Any N	M1

**Table 3. Histologic Grade**

<b>G</b>	<b>G Definition</b>
<b>GX</b>	Grade cannot be assessed
<b>G1</b>	Well differentiated
<b>G2</b>	Moderately differentiated
<b>G3</b>	Poorly differentiated

Used with permission of the American College of Surgeons, Chicago, Illinois. The original source for this information is the AJCC Cancer Staging Manual, Eighth Edition (2017) published by Springer International Publishing.

**Note: All recommendations are category 2A unless otherwise indicated.**

**ABBREVIATIONS**

<b>3D-CRT</b>	<b>three-dimensional conformal radiation therapy</b>	<b>H&amp;P</b>	<b>history and physical</b>	<b>PTC</b>	<b>percutaneous transhepatic cholangiography</b>
<b>4D-CT</b>	<b>four-dimensional computed tomography</b>	<b>IAPN</b>	<b>intra-ampullary papillary tubular neoplasm</b>	<b>PTV</b>	<b>planning target volume</b>
<b>CAP</b>	<b>College of American Pathologists</b>	<b>IMRT</b>	<b>intensity-modulated radiation therapy</b>	<b>PV</b>	<b>portal vein</b>
<b>CEA</b>	<b>carcinoembryonic antigen</b>	<b>ITV</b>	<b>internal target volume</b>	<b>SBRT</b>	<b>stereotactic body radiation therapy</b>
<b>DFS</b>	<b>disease-free survival</b>	<b>MDCT</b>	<b>multi-detector computed tomography</b>	<b>SEMS</b>	<b>self-expanding metal stent</b>
<b>dMMR</b>	<b>mismatch repair deficient</b>	<b>MIP</b>	<b>maximum intensity projection</b>	<b>SMA</b>	<b>superior mesenteric artery</b>
<b>DVH</b>	<b>dose-volume histogram</b>	<b>MPV</b>	<b>main portal vein</b>	<b>SMV</b>	<b>superior mesenteric vein</b>
<b>DWI</b>	<b>diffusion-weighted echo</b>	<b>MRCP</b>	<b>magnetic resonance cholangiopancreatography</b>	<b>SSFSE</b>	<b>single-shot fast spin echo</b>
<b>EGD</b>	<b>esophagogastroduodenoscopy</b>	<b>MSI</b>	<b>microsatellite instability</b>	<b>TMB</b>	<b>tumor mutational burden</b>
<b>ENI</b>	<b>elective nodal irradiation</b>	<b>MSI-H</b>	<b>microsatellite instability-high</b>	<b>TMB-H</b>	<b>tumor mutational burden-high</b>
<b>ERCP</b>	<b>endoscopic retrograde cholangiopancreatography</b>	<b>NGS</b>	<b>next-generation sequencing</b>	<b>TNM</b>	<b>tumor node metastasis</b>
<b>EUS</b>	<b>endoscopic ultrasound</b>	<b>NPO</b>	<b>nothing by mouth</b>		
<b>FRFSE</b>	<b>fast relaxation fast spin-echo sequence</b>	<b>OAR</b>	<b>organ at risk</b>		
<b>FSE</b>	<b>fast spin echo</b>	<b>OS</b>	<b>overall survival</b>		
<b>G/J-tube</b>	<b>gastrostomy/jejunostomy tube</b>	<b>PEG</b>	<b>percutaneous endoscopic gastrostomy</b>		
<b>GRE</b>	<b>gradient echo</b>	<b>PS</b>	<b>performance status</b>		



NCCN Categories of Evidence and Consensus	
<b>Category 1</b>	Based upon high-level evidence (≥1 randomized phase 3 trials or high-quality, robust meta-analyses), there is uniform NCCN consensus (≥85% support of the Panel) that the intervention is appropriate.
<b>Category 2A</b>	Based upon lower-level evidence, there is uniform NCCN consensus (≥85% support of the Panel) that the intervention is appropriate.
<b>Category 2B</b>	Based upon lower-level evidence, there is NCCN consensus (≥50%, but <85% support of the Panel) that the intervention is appropriate.
<b>Category 3</b>	Based upon any level of evidence, there is major NCCN disagreement that the intervention is appropriate.

All recommendations are category 2A unless otherwise indicated.

NCCN Categories of Preference	
<b>Preferred intervention</b>	Interventions that are based on superior efficacy, safety, and evidence; and, when appropriate, affordability.
<b>Other recommended intervention</b>	Other interventions that may be somewhat less efficacious, more toxic, or based on less mature data; or significantly less affordable for similar outcomes.
<b>Useful in certain circumstances</b>	Other interventions that may be used for selected patient populations (defined with recommendation).

All recommendations are considered appropriate.

**Note: All recommendations are category 2A unless otherwise indicated.**

## Discussion

This discussion corresponds to the NCCN Guidelines for Ampullary Adenocarcinoma. Last updated: April 27, 2023.

## Table of Contents

<b>Overview</b> .....	<b>MS-2</b>
<b>Literature Search Criteria and Guidelines Update Methodology</b> .....	<b>MS-3</b>
<b>Sensitive/Inclusive Language Usage</b> .....	<b>MS-3</b>
<b>Genetics of Ampullary Cancer</b> .....	<b>MS-4</b>
<b>Clinical Presentation and Workup</b> .....	<b>MS-4</b>
Ampullary Adenocarcinoma .....	MS-5
<b>Treatment of Ampullary Adenoma</b> .....	<b>MS-6</b>
<b>Treatment of Ampullary Adenocarcinoma</b> .....	<b>MS-7</b>
Treatment of Localized Disease .....	MS-7
Surgical Techniques .....	MS-7
Neoadjuvant Therapy .....	MS-9
Adjuvant Therapy .....	MS-10
Chemoradiation .....	MS-12
Treatment of Metastatic Disease .....	MS-13
First-Line Systemic Therapy .....	MS-13
Treatment for Disease Progression .....	MS-15
Subsequent-Line Systemic Therapy .....	MS-15
<b>References</b> .....	<b>MS-17</b>



# NCCN Guidelines Version 2.2024

## Ampullary Adenocarcinoma

### Overview

Ampullary cancers are defined as tumors originating from the ampulla of Vater (formed by 3 anatomical components: the ampulla, the intraduodenal portion of the bile duct, and the intraduodenal portion of the pancreatic duct), while periampullary cancers may arise from locations encompassing the head of the pancreas, distal bile duct, duodenum, or ampulla of Vater.<sup>1,2</sup> Although relatively rare, accounting for only 0.2% of gastrointestinal malignancies and 6% of all periampullary cancers, ampullary adenocarcinoma is an important entity given the pathologic variations and associated prognosis.<sup>3</sup> The 5-year overall survival (OS) for ampullary cancer is between 35% and 50%; however, prognosis can vary greatly based on a variety of factors such as patient age, TNM (tumor, node, metastasis) classification, differentiation grade, and treatment modality received.<sup>4-16</sup> For example, the 5-year OS for AJCC 7<sup>th</sup> Edition stage I, stage II, and stage III + IV ampullary cancers is 64%, 27%, and 17%, respectively.<sup>11</sup> Similar to other malignancies, distant metastatic disease bodes a particularly poor prognosis for ampullary cancer.<sup>4,7</sup> Regardless, ampullary tumors generally have a more favorable outcome when compared to other periampullary malignancies.<sup>1,6,10-12,17-26</sup> In a single-institutional review of 2564 periampullary cancers, the median survival for ampullary cancer was 47 months compared to 19, 23, and 54 months for pancreatic, biliary, and duodenal cancer, respectively.<sup>17</sup> Early detection might partially contribute to this prognostic pattern.

The ampulla of Vater is an anatomically complex region, and distinction of periampullary tumors based on site of origin is particularly challenging, especially for large tumors that have invaded surrounding organs at presentation.<sup>27,28</sup> The ampulla of Vater is comprised of two mucosal tissue types: pancreatobiliary ductal mucosa and intestinal mucosa. Therefore, ampullary cancer can be divided into two histologic subtypes: pancreatobiliary subtype and intestinal subtype, a classification system initially developed by Kimura et al.<sup>29</sup> The proportion of each subtype varies

widely between study populations.<sup>3,23,27,30-33</sup> CDX2 and MUC1 are useful biomarkers to distinguish the two subtypes (pancreatobiliary subtype: CDX2 negative, MUC1 positive; intestinal subtype: CDX2 positive, MUC1 negative) and have been shown to be independent prognostic factors in multiple studies.<sup>30-33</sup> Other biomarkers that have been proven useful in making this distinction are MUC2 and CK20.<sup>32-34</sup> The utility of these biomarkers, however, is limited by staining method (hematoxylin and eosin [H&E] vs. immunohistochemistry [IHC]), staining positivity threshold, and subjective pathologists' assessment. It should be noted that a significant proportion of ampullary adenocarcinomas may be of mixed phenotype.<sup>34,35</sup> Thus, the NCCN Panel recommends reporting of histologic subtypes as pancreatobiliary, intestinal, or mixed, with the predominant pattern noted in the pathology report for the mixed subtype (See *Pathologic Analysis: Specimen Orientation, Histologic Sections, and Reporting* in the algorithm). It has been postulated for all periampullary cancers that histologic subtype is at least as important of a prognostic factor as tissue of origin.<sup>3,23</sup> Each ampullary cancer subtype seems to resemble its periampullary counterpart in terms of biological behavior and prognosis, with the pancreatobiliary subtype demonstrating higher lymph node involvement and worse survival than the intestinal subtype.<sup>16,23,27,29-31,35-37</sup> In a retrospective study of 95 ampullary cancers and 206 matching periampullary cancers, the OS of pancreatobiliary subtype was comparable to that of pancreatic cancer (25 vs. 14 months;  $P = .123$ ), but worse than that for intestinal subtype (25 vs. 98 months;  $P < .001$ ).<sup>36</sup>

Systemic therapy is used in all stages of ampullary cancer. This includes neoadjuvant therapy for resectable or borderline resectable disease (albeit used more rarely compared to pancreatic cancer), adjuvant therapy, and first-line or subsequent-line therapy for locally advanced, metastatic, and recurrent disease. Data for systemic therapy in ampullary cancer are very limited; the only phase III randomized trial to date that enrolled a relatively large number of patients with ampullary cancer was ESPAC-3, which





# NCCN Guidelines Version 2.2024

## Ampullary Adenocarcinoma

tested 5-fluorouracil (5-FU) + leucovorin versus gemcitabine in the adjuvant setting.<sup>38</sup> Thus, the NCCN recommendations for systemic therapy options in ampullary cancer are frequently extrapolated from data in the setting of pancreatic cancer, colorectal cancer, and biliary tract cancer, as well as panel members' clinical experience. Often, systemic therapy recommendations for pancreatobiliary/mixed type are derived from pancreatic or biliary tract cancer, while those for intestinal type are derived from colorectal cancer (See [NCCN Guidelines for Colon Cancer](#) and [NCCN Guidelines for Small Bowel Adenocarcinoma](#)). Many regimens are put forth as likely options; however, their potential utility in individual patients must be carefully evaluated by the treating physicians based on interpretation of original trial data and drug risk/benefit profile (See *Principles of Systemic Therapy* in the algorithm).

Radiation therapy (RT) is another treatment modality that can be utilized in localized ampullary cancer, sometimes in combination with chemotherapy, but there is no high level evidence to support its utility.<sup>39-42</sup> The goal of RT is to sterilize vessel margins, enhance the likelihood of a margin-negative resection, and/or provide adequate local control to prevent or delay progression or prevent local disease recurrence while minimizing the risk of RT exposure to surrounding organs at risk (See *Principles of Radiation Therapy* in the algorithm). Lastly, palliation and supportive care are warranted to prevent and ameliorate suffering while ensuring optimal quality of life for patients with end-stage disease who have run out of options (See *Principles of Palliation and Supportive Care* in the algorithm). For both of these modalities, recommendations are derived from the NCCN Clinical Practice Guidelines in Oncology (NCCN Guidelines®) for Pancreatic Adenocarcinoma, which can serve as an additional source of reference. Briefly, opioids with or without neurolysis or endoscopic ultrasound (EUS)-guided celiac plexus neurolysis can be utilized for pain management in ampullary cancer. Palliative RT with or without chemotherapy or high-intensity focused ultrasound (HIFU) can also be

utilized for severe pain refractory to analgesic therapy, although the recommendation for HIFU is only supported by a small number of observational studies.<sup>43</sup>

### Literature Search Criteria and Guidelines Update Methodology

Prior to the update of this version of the NCCN Guidelines for Head and Neck Cancers, an electronic search of the PubMed database was performed to obtain key literature in H&N cancers published since the previous Guidelines update, using the following search term: ampullary cancer. The PubMed database was chosen because it remains the most widely used resource for medical literature and indexes peer-reviewed biomedical literature.

The search results were narrowed by selecting studies in humans published in English. Results were confined to the following article types: Clinical Trial; Guideline; Meta-Analysis; Randomized Controlled Trial; Systematic Reviews; and Validation Studies. The data from key PubMed articles as well as articles from additional sources deemed as relevant to these guidelines as discussed by the panel during the Guidelines update have been included in this version of the Discussion section. Recommendations for which high-level evidence is lacking are based on the panel's review of lower-level evidence and expert opinion.

### Sensitive/Inclusive Language Usage

NCCN Guidelines strive to use language that advances the goals of equity, inclusion, and representation. NCCN Guidelines endeavor to use language that is person-first; not stigmatizing; anti-racist, anti-classist, anti-misogynist, anti-ageist, anti-ableist, and anti-weight-biased; and inclusive of individuals of all sexual orientations and gender identities. NCCN Guidelines incorporate non-gendered language, instead focusing on organ-specific recommendations. This language is both more accurate



# NCCN Guidelines Version 2.2024

## Ampullary Adenocarcinoma

and more inclusive and can help fully address the needs of individuals of all sexual orientations and gender identities. NCCN Guidelines will continue to use the terms *men*, *women*, *female*, and *male* when citing statistics, recommendations, or data from organizations or sources that do not use inclusive terms. Most studies do not report how sex and gender data are collected and use these terms interchangeably or inconsistently. If sources do not differentiate gender from sex assigned at birth or organs present, the information is presumed to predominantly represent cisgender individuals. NCCN encourages researchers to collect more specific data in future studies and organizations to use more inclusive and accurate language in their future analyses.

### Genetics of Ampullary Cancer

At the genomic level, important similarities and differences between ampullary cancer and other periampullary cancers exist. For example, the frequency of *KRAS* mutations seems to be comparable between ampullary cancer<sup>44,45</sup> and duodenal cancer,<sup>46,47</sup> but much lower in either cancer than in pancreatic cancer (~30% to 40% vs. ~90%<sup>48</sup>). *KRAS* mutations have been suggested to be predictive of outcomes in ampullary cancer; however, their prognostic value over histologic subtype is questionable.<sup>44,45,49</sup> The distribution of *KRAS* mutations across ampullary cancer subtypes is also unclear, as present studies include very small numbers of patients, but they appear more frequent in pancreatobiliary subtypes.<sup>50-52</sup>

Other somatic alterations that have been reported in ampullary cancer include mutations in *APC*, *TP53*, *CDKN2A*, *DPC4*, *ELF3*, *PIK3CA*, and *SMAD4*, *HER2* amplifications, and microsatellite instability (MSI).<sup>51,53-60</sup> Pathogenic mutations reported include *BRCA1/2*, *ATM*, *RAD50*, and *MUTYH*.<sup>57,61</sup> A recent genomic classification study using a large data set of 3411 patients with periampullary cancers found high concordance between histologic ampullary cancer subtypes and their respective

genomic categories. Specifically, the pancreatobiliary subtype corresponds to pancreatic adenocarcinoma genomic signature, which is characterized by a high incidence of *KRAS* mutations. The intestinal subtype corresponds to colorectal adenocarcinoma genomic signature, which is characterized by mutations in *APC* and *PI3KCA*, higher tumor mutational burden (TMB), and DNA mismatch repair (MMR) deficiency (dMMR). However, there was significant genomic heterogeneity within each histologic subtype.<sup>52</sup>

There are many targeted agents currently approved by the U.S. Food and Drug Administration (FDA) for a variety of cancers or that are under clinical development and testing. Future investigations into the genomic landscape of ampullary cancer might have great implication in the selection of appropriate candidates for targeted therapy.

### Clinical Presentation and Workup

The workup for patients presenting with clinical suspicion of ampullary neoplasm consists of pancreatic protocol CT (abdomen and pelvis – See *Principles of Diagnosis, Imaging, and Staging* in the algorithm), followed by esophagogastroduodenoscopy (EGD) with or without EUS with biopsy and colonoscopy (if not previously performed according to established guidelines). The workup for patients diagnosed with noninvasive ampullary neoplasms, with or without high-grade dysplasia, should be similar to those with periampullary duodenal adenomas.

Endoscopic biopsies of ampullary adenocarcinoma have shown poor diagnostic accuracy, with high false-negative rates reported in the literature (~20% to 40%). The presence of adenocarcinoma within an adenoma can be missed by endoscopic biopsies, as adenocarcinoma foci have been reported in the final pathologic analysis of what was initially diagnosed as ampullary adenomas.<sup>62-69 63,65-67,70-72</sup> EUS and CT are commonly used imaging techniques in the initial diagnosis and





# NCCN Guidelines Version 2.2024

## Ampullary Adenocarcinoma

subsequent staging of ampullary neoplasms, with EUS noted as the more specific and sensitive modality in several small, single-institution, prospective studies.<sup>63,70,72-82</sup>

### Ampullary Adenocarcinoma

Patients presenting with ampullary adenocarcinoma should receive further workup consisting of chest CT, pancreas protocol CT of abdomen/pelvis, liver function tests, and detection of baseline CA 19-9 and carcinoembryonic antigen (CEA). Endoscopic retrograde cholangiopancreatography (ERCP)/percutaneous transhepatic cholangiography (PTC) can be considered as clinically indicated. The NCCN Guidelines for Ampullary Adenocarcinoma derive their pancreatic cancer radiology reporting template from the [NCCN Guidelines for Pancreatic Adenocarcinoma](#).

ERCP/PTC has been used frequently in the further evaluation of ampullary neoplasms and can provide additional diagnostic capability, albeit with increased morbidity and even mortality, beyond what EGD/EUS and CT can offer.<sup>63,67,68,72,76,83</sup> An elevated CA 19-9 level may be indicative of ampullary adenocarcinoma, although normal levels have been reported in 37% of patients.<sup>22,84</sup>

Genetic testing for inherited mutations can be considered, with the same recommendations as those found in the [NCCN Guidelines for Pancreatic Adenocarcinoma](#). Specifically, genetic testing for inherited mutations is recommended for any patient with confirmed ampullary cancer, using comprehensive gene panels for hereditary cancer syndromes. Genetic counseling is recommended for patients who test positive for a pathogenic mutation (*ATM*, *BRCA1*, *BRCA2*, *CDKN2A*, *MLH1*, *MSH2*, *MSH6*, *PALB2*, *PMS2*, *STK11*, and *TP53*) or for patients with a positive family history of cancer, especially pancreatic/ampullary cancer, regardless of mutation status (See [NCCN Guidelines for Genetic/Familial High-Risk Assessment:](#)

[Breast, Ovarian, and Pancreatic](#)). Multidisciplinary consultation is also warranted, with the same considerations as those found in the [NCCN Guidelines for Pancreatic Adenocarcinoma](#). Specifically, multidisciplinary review should consider involving expertise from diagnostic imaging, interventional endoscopy, medical oncology, radiation oncology, surgery, pathology, geriatric medicine, genetic counseling, and palliative care (see *Principles of Palliation and Supportive Care* in the algorithm). Consultation with a registered dietitian should be considered (See [NCCN Guidelines for Older Adult Oncology](#) and [NCCN Guidelines for Palliative Care](#)).

Following the workup above, patients with no metastatic disease should receive MRI to evaluate indeterminate liver lesions as clinically indicated. PET/CT may be used when MRI cannot be performed (eg, pacemaker-dependent patient). Histologic subtyping of the tumor as pancreatobiliary, intestinal, or mixed should also be carried out, if possible. Patients with metastatic disease should receive biopsy confirmation, preferably from a metastatic site. Core biopsy is recommended, if possible, to obtain adequate tissue for molecular testing.

Molecular profiling of tumor tissue should be performed with the same considerations as those found in the [NCCN Guidelines for Pancreatic Adenocarcinoma](#). Specifically, tumor/somatic molecular profiling is recommended for patients with locally advanced/metastatic disease who are candidates for anti-cancer therapy to identify uncommon mutations. Specifically testing for potentially actionable somatic findings including, but not limited to fusions (ie, *ALK*, *NRG1*, *NTRK*, *ROS1*, *FGFR2*, *RET*), mutations (ie, *BRAF*, *BRCA1/2*, *KRAS*, *PALB2*), amplifications (*HER2*), MSI, dMMR, or TMB via an FDA-approved and/or validated next-generation sequencing-based assay is recommended. Testing on tumor tissue is preferred; however, circulating tumor DNA testing can be considered if tumor tissue testing is not feasible.



## Treatment of Ampullary Adenoma

Ampullary adenomas are benign tumors that can arise sporadically or in the setting of hereditary polyposis syndromes such as familial adenomatous polyposis. Ampullary adenomas can undergo malignant transformation and result in ampullary adenocarcinomas; however, the exact course and rate of transformation are still unclear.<sup>85-87</sup>

Patients presenting with ampullary adenoma can be treated with endoscopic removal (preferred), surgical ampullectomy, or pancreatoduodenectomy (See *Principles of Surgical Technique* in the algorithm). Patients with negative margins following endoscopic removal or surgical ampullectomy should undergo endoscopic surveillance, whereas after pancreatoduodenectomy, patients do not need to undergo surveillance. Patients with positive margins after endoscopic removal can be re-excised or undergo ampullectomy or pancreatoduodenectomy. Patients with positive margins after ampullectomy can undergo pancreatoduodenectomy.

Since foci of occult adenocarcinoma have been found in ampullary adenoma, and the exact timeline and rate of malignant transformation from adenoma to adenocarcinoma is not known, there is some debate regarding the optimal management of these lesions. A few studies have attempted to put forth criteria for endoscopic removal of benign ampullary neoplasms.<sup>88,89</sup> The NCCN Panel recommends that ampullary adenomas up to 20 mm in diameter be safely removed endoscopically, including those with high-grade dysplasia. Depending on the size and extent of invasion, ampullary adenomas might require multiple rounds of resection and more than one surgical technique for complete removal.<sup>72,90,91</sup> All three techniques—endoscopic resection,<sup>62-64</sup> surgical ampullectomy,<sup>65,69,92</sup> and pancreaticoduodenectomy—<sup>65,69,84</sup> have been shown to be effective in removing ampullary adenomas in retrospective, heterogeneous studies. In particular, endoscopic resection, also interchangeably referred to as

endoscopic papillectomy or endoscopic ampullectomy in the literature, has been shown to be effective and safe in patients with ampullary adenomas. The reported recurrence rates are between 6% and 40% with varying lengths of follow-up; most recurrences are successfully resected endoscopically.<sup>64,72,89,93-97</sup> Commonly reported complications include hemorrhage, perforation, and pancreatitis.<sup>72,93,94,96,98</sup> Endoscopic resection is the NCCN-preferred treatment modality for ampullary adenomas. The NCCN Panel recommends endoscopic removal of ampullary adenomas to be performed at a high-volume center.

Studies directly comparing the three resection techniques are scant and of retrospective nature.<sup>90,91,98</sup> A study (n = 137) comparing all three modalities with surveillance found that endoscopic resection was associated with higher residual and recurrent tumor rates than pancreatoduodenectomy (27.6% vs. 0% and 17.2% vs. 0%, respectively) but fewer adverse events (AEs) (10.2% vs. 29%). This study contained too few surgical ampullectomies (n = 4) to be able to draw any meaningful conclusions regarding this modality.<sup>98</sup> Another study directly comparing endoscopic resection and surgical ampullectomy (n = 109) reported no difference in mortality, margin positivity, and reoperation between the two procedures. Endoscopic resection, however, was associated with significantly lower morbidity (18% vs. 42%;  $P = .006$ ) and readmission rates (16% vs. 34%;  $P = .03$ ).<sup>91</sup> Overall, endoscopic resection seems to lead to more recurrences, but is generally safer than surgical procedures. In a study including 180 patients with ampullary adenomas, endoscopic resection was associated with a greater risk of recurrence than operative resection (32% vs. 3%;  $P = .006$ ) but a lower rate of complication (58% vs. 29%;  $P < .001$ ).<sup>90</sup> A meta-analysis, which includes five studies and a total of 466 patients with ampullary adenomas concurred that surgical treatment had lower recurrence rate (risk difference [RD], 0.10; 95% CI, –0.01 to 0.19) than endoscopic resection; however, no difference in complication rates was found (RD, –0.15; 95% CI, –0.53 to 0.23).<sup>99</sup>



## Treatment of Ampullary Adenocarcinoma

### Treatment of Localized Disease

The first line of treatment for localized ampullary adenocarcinoma usually involves surgery, primarily pancreatoduodenectomy. Specimens are obtained at this point for pathologic analysis to determine the pathologic stage of the tumor, completeness of resection, and other histopathologic features that impact prognosis and clinical management. Decisions about diagnostic management and resectability should involve multidisciplinary consultation at a high-volume center with reference to appropriate high-quality imaging studies to evaluate the extent of disease (See *Principles of Surgical Technique and Pathologic Analysis: Specimen Orientation, Histologic Sections, and Reporting* in the algorithm). Biliary stent placement is not routinely recommended prior to planned surgery; however, a stent may be considered for symptoms of cholangitis/fever or severe symptomatic jaundice (intense pruritus), or if surgery is being delayed for any reason, including neoadjuvant therapy (See *Principles of Stent Management* in the algorithm).

Neoadjuvant systemic therapy can be considered, particularly in patients at high risk, with or without subsequent chemoradiation. High-risk features include imaging findings, markedly elevated CA 19-9, markedly elevated CEA, large primary tumors, large regional lymph nodes, excessive weight loss, and extreme pain. There is limited evidence to recommend specific neoadjuvant regimens off-study, and practices vary with regard to the use of chemotherapy and chemoradiation. After neoadjuvant therapy and stent placement, pancreatic protocol CT or MRI is recommended, followed by surgery in case of resectable disease. Unresectable disease should be managed with the same systemic therapy regimens as metastatic disease.

All resected ampullary cancers can receive postoperative adjuvant treatment. The initiation of adjuvant systemic therapy is recommended within 12 weeks of surgery if the patient is medically fit. The optimal

duration of treatment is 4 to 6 months. The NCCN recommendations for each disease stage are as follows: 1) stage I disease, systemic therapy or observation; 2) stage II disease, systemic therapy with or without chemoradiation or observation; and 3) stage III disease, systemic therapy with or without chemoradiation.

After adjuvant therapy, patients should undergo surveillance every 3 to 6 months for 2 years, then every 6 to 12 months for up to 5 years or as clinically indicated. During surveillance, history and physical examination should take place, as should chest CT and CT or MRI of the abdomen and pelvis with contrast. CEA and/or CA 19-9 levels should also be measured.

### Surgical Techniques

Pancreatoduodenectomy is the primary surgical technique for the removal of primary ampullary adenocarcinoma with reported postoperative 5-year survival of 32% to 78%.<sup>6-8,10,13,19,24,25,100-102</sup> The reported morbidity and mortality for this procedure are 27% to 59% and 2% to 10%, respectively.<sup>6-9,12-15,69,73,84,100-102</sup> It should be noted that most studies are small, retrospective, contain heterogeneous populations, and combine results for benign and malignant ampullary neoplasms or combine results for ampullary cancers and other periampullary cancers. Reported prognostic factors for survival and recurrence outcomes include lymphovascular invasion, perineural invasion, tumor size and stage, ulceration, differentiation, presence and extent of lymph node metastasis, resection margin status, as well as CEA and CA 19-9 levels.<sup>6,7,10,13,15,22,84,101,103-105</sup> However, data vary widely across studies on each of these parameters. For example, perineural invasion is not always documented on the pathology report and thus is not included in many analyses. Many studies that included perineural invasion, however, found that it has a significant impact on recurrence and/or survival, at least on univariate analyses if not multivariate analyses.<sup>6,12,22,84,104,106,107</sup> Bettschart et al (n = 70) reported a median survival of 18.7 vs. 51.9 months for cancers with and without





# NCCN Guidelines Version 2.2024

## Ampullary Adenocarcinoma

perineural invasion, respectively ( $P = .001$ ).<sup>12</sup> Regarding 5-year survival, Song et al ( $n = 89$ ) reported rates of 36.8% versus 72.1% in those with and without perineural invasion, respectively ( $P < .001$ ).<sup>107</sup> CEA and CA 19-9 levels are two other features that have not been consistently measured and documented for ampullary cancer. Studies have reported an inverse association between CA 19-9 level and recurrence/survival,<sup>13,108,109</sup> an association for CEA but not CA 19-9,<sup>103</sup> an association for CA 19-9 on univariate but not multivariate analyses,<sup>22</sup> or no association between either marker with recurrence and/or survival.<sup>104</sup> Therefore, the prognostic utility of these markers remains controversial.

The impact of histologic subtype on surgical outcome is, perhaps, even more understudied. According to Park et al ( $n = 93$ ), among patients who developed early recurrence (defined as within 6 months of surgery; disease-free survival [DFS] = 4.2 months), the pancreatobiliary subtype recurred early compared to the intestinal subtype (71.4% vs. 28.6% early recurrences;  $P = .001$ ); however, this might be due to more advanced T stage and lymph node metastases in the pancreatobiliary subtype.<sup>106</sup> A multivariate analysis from this study also showed that pancreatobiliary subtype was associated with very early recurrence following surgery. Bolm et al reported median OS after pancreatoduodenectomy to be 118 months versus 156 months for pancreatobiliary/mixed subtype versus intestinal subtype, respectively, with statistical significance on univariate ( $P = .003$ ) but not multivariate analysis.<sup>108</sup> Evidence thus far is not definitive on whether histologic subtypes are independent prognostic factors for outcomes.

Studies have reported lymph node positivity in 30% to 67% of patients with ampullary adenocarcinomas undergoing pancreatoduodenectomy.<sup>7,9,10,13,14,22,69,70,84,104,107,108,110-112</sup> For optimal staging, a minimum of 17 lymph nodes in pancreatoduodenectomy specimens is recommended.<sup>113-115</sup> As mentioned earlier, the presence and

extent of lymph node involvement is predictive of outcome in ampullary cancer. Except for the results from two small single-institution studies, each including fewer than 100 patients,<sup>100,101</sup> it was uniformly demonstrated that survival was significantly better for node-negative versus node-positive disease.<sup>7-9,13,14,69,70,84,104,107,108,111</sup> In particular, a large population-based study that included 1301 patients who underwent resection for ampullary cancer reported significantly higher 5- and 10-year disease-specific survival (DSS) for node-negative versus node-positive disease (59.4% vs. 28.4%;  $P < .001$  and 54.1% vs. 21.9%;  $P < .001$ , respectively).<sup>9</sup> Furthermore, increased number of positive lymph nodes diminishes survival, as the cumulative 5-year survival rates were reported in a small study ( $n = 34$ ) to be 85% with 0 positive node, 63% with 1 to 3 positive nodes, and 0% for  $\geq 4$  positive nodes ( $P < .0001$ ).<sup>112</sup> Factors such as tumor size, histologic grade, perineural invasion, microscopic vessel invasion, depth of invasion, and morphology have been associated with lymph node invasion.<sup>84,107</sup> In particular, one study ( $n = 450$ ) noted that the risk of lymph node invasion increased with T stage (T1, 28.0%; T2, 50.9%; T3, 71.7%; T4, 77.3%;  $P < .001$ ).<sup>84</sup> Another study ( $n = 259$ ) reported similar results, with lymph node positivity rates at 11.3%, 28.4%, 43.8%, and 100% for T1, T2, T3, and T4 tumors, respectively.<sup>110</sup>

There are very few studies directly comparing pancreatoduodenectomy and surgical ampullectomy. One larger study ( $n = 450$ , pancreatoduodenectomy = 435, ampullectomy = 15), which did not separate results for ampullary adenomas and ampullary adenocarcinomas, reported no statistical difference in morbidity (52.2% vs. 33.3%) or mortality (2.1% vs. 0%) between the two procedures.<sup>84</sup> The number of ampullectomies in this study, however, was too small to make any meaningful conclusion. A more recent, albeit smaller, study (63 pancreatoduodenectomies, 26 ampullectomies) demonstrated that pancreatoduodenectomy led to more postoperative complications, specifically significantly higher mean blood loss, longer operative time, and



# NCCN Guidelines Version 2.2024

## Ampullary Adenocarcinoma

more pancreatic fistula. There were also three deaths with pancreatoduodenectomy versus no deaths with ampullectomy. It was noted that patients treated with pancreatoduodenectomy in this study tended to present more frequently with jaundice, gross morphology, and large tumor size. There was no difference in 5-year OS (65.6% vs. 64.6%), but pancreatoduodenectomy resulted in longer DFS (median ~85 vs. 40 months—estimated from Kaplan-Meier curves;  $P = .025$ ).<sup>107</sup> Overall and as expected, ampullectomy seems to result in lower morbidity and mortality, but is associated with a higher recurrence rate.<sup>69,70</sup> A few studies have attempted to establish standard indications for ampullectomy in patients with ampullary cancer; however, the specific criteria remain to be determined.<sup>80,116</sup>

Recently, laparoscopic and robotic pancreatoduodenectomies have become more widespread due to their potential for quicker recovery and shorter hospital stays; however, how they compare to open pancreatoduodenectomy remains a question under investigation.<sup>25,102,117-120</sup>

Postoperatively, the rates of recurrence and time to recurrence vary widely across studies. Recurrences have been reported as early as less than 6 months and as late as 22.5 months after surgery.<sup>7,22,103,106,110,121</sup> The rates of recurrence range between 28% and 55%, with distant recurrences making up the majority or about 80% in many studies. For distant recurrences, the most common site of metastasis is the liver (38%–65% of distant recurrences). Other sites of metastasis are the peritoneum, lung, and bones. Overall, the liver is the most common site of all recurrences, locoregional or distant.<sup>7,22,103,106,110,121</sup> One study noted that while pancreatic invasion and tumor size were predictive of locoregional recurrence, lymph node involvement was the sole predictor for liver metastasis.<sup>7</sup> More data are needed to better characterize distant

metastases in ampullary cancer and understand the implications such findings might have on treatment decisions.

### **Neoadjuvant Therapy**

Very few studies have investigated the use of neoadjuvant therapy in ampullary cancer. Overall, the use of neoadjuvant therapy is low, varying between 1% and 4% of patients undergoing surgery across studies.<sup>122,123</sup> In the biggest and most recent study on this topic with a total of 8688 patients with ampullary cancer, 175 of whom received neoadjuvant therapy, no difference in OS was found between the neoadjuvant and the surgery-first groups (43 vs. 33 months, respectively;  $P = .401$  on univariate and  $.416$  on multivariate analysis). It was noted in this study that patients who received neoadjuvant therapy tend to be younger and more likely to have nodal metastases.<sup>122</sup> This result was recapitulated by two other studies, one that included 3762 patients, 94 of whom received neoadjuvant therapy, and another smaller study with 142 patients, 43 of whom received neoadjuvant therapy.<sup>123,124</sup> Despite little proven advantage in improving survival, neoadjuvant therapy led to downstaging (15%–67% of tumors across studies) and was associated with decreased use of adjuvant chemotherapy or chemoradiation.<sup>123-125</sup> These studies emphasize the need for careful selection of patients who might benefit from neoadjuvant therapy.

The NCCN-recommended neoadjuvant therapy options for pancreatobiliary/mixed type ampullary cancer include FOLFIRINOX/modified FOLFIRINOX (mFOLFIRINOX), gemcitabine + cisplatin, gemcitabine + capecitabine, and gemcitabine + albumin-bound paclitaxel. The NCCN-recommended neoadjuvant therapy options for intestinal type ampullary cancer include FOLFOXIRI, FOLFOX, and capecitabine + oxaliplatin (CapeOx). All of these regimens can be potentially followed by chemoradiation based on multidisciplinary tumor board recommendation.



# NCCN Guidelines Version 2.2024

## Ampullary Adenocarcinoma

For pancreatobiliary/mixed type ampullary cancer, the recommendations for FOLFIRINOX/mFOLFIRINOX, gemcitabine + cisplatin, and gemcitabine + albumin-bound paclitaxel are derived from the NCCN Guidelines for Pancreatic Adenocarcinoma and NCCN Guidelines for Biliary Tract Cancers, with the addition of gemcitabine + capecitabine based on panel members' clinical experience. It should be noted that there are no prospective randomized phase III data supporting these recommendations. The available evidence is derived from prospective phase II or randomized phase II studies as well as from retrospective studies.<sup>126-131</sup> For more information on these studies, see the discussion sections of the [NCCN Guidelines for Pancreatic Adenocarcinoma](#) and the [NCCN Guidelines for Biliary Tract Cancers](#).

For intestinal type ampullary cancer, all three recommendations are derived from the [NCCN Guidelines for Colon Cancer](#) and the [NCCN Guidelines for Small Bowel Adenocarcinoma](#). These recommendations are based on high-level evidence, phase III randomized data from the neoadjuvant FOxTROT trial (FOLFOX, CapeOx) in localized colon cancer,<sup>132</sup> data from the TRIBE and TRIBE2 trials (FOLFOXIRI) for metastatic disease, and data from one phase II study with neoadjuvant FOLFOXIRI for localized colon cancer.<sup>133-135</sup> For more information on these studies, see the discussion section of the [NCCN Guidelines for Colon Cancer](#).

### Adjuvant Therapy

Adjuvant therapy is frequently utilized after curative resection in ampullary cancer, most often in the form of chemotherapy. Radiotherapy can also be used in the adjuvant setting, often in combination with chemotherapy.<sup>111</sup> Most of the literature on adjuvant therapy in ampullary cancer is retrospective in nature. In a recent large analysis of National Cancer Database (NCDB) data (n = 4190), both adjuvant chemotherapy (n = 880) and adjuvant chemoradiation (n = 670) were found to be associated with

improved OS compared to observation (n = 2640). In the first analysis, median OS for the adjuvant chemotherapy group and the observation group were 47.2 and 35.5 months, respectively (hazard ratio [HR], 0.82;  $P < .01$ ). In the second analysis, median OS for the adjuvant chemoradiation group and the observation group were 38.1 months and 31.0 months, respectively (HR, 0.84;  $P = .02$ ). Patients who are at high risk, such as those with higher T- and N-stage disease, seemed to benefit more from both adjuvant chemotherapy and adjuvant chemoradiation.<sup>136</sup> Two large meta-analyses, one that included 71 studies and 8280 patients,<sup>16</sup> and the other that included 10 studies and 3361 patients,<sup>137</sup> together with many smaller retrospective studies agree with the benefit of adjuvant therapy, whether chemotherapy, radiotherapy, or chemoradiation for resected ampullary cancers.<sup>108-110,125,138-140</sup> Some studies have also documented the usefulness of adjuvant therapy specifically for patients with lymph node involvement.<sup>111,139,140</sup> Narang et al (n = 186) demonstrated that, for patients who were node positive, adjuvant chemoradiation compared to observation led to longer OS (median OS, 32.1 vs. 15.7 months; 5-year OS, 27.5% vs. 5.9%; HR, 0.47;  $P = .004$ ). In this study, adjuvant therapy was more likely used for higher T-stage, lymph node involvement, and close or positive margins.<sup>111</sup> Kamarajah et al (n = 1106) showed the benefit of adjuvant radiotherapy for N2 disease in improving both DSS (median, 27 vs. 19 months;  $P = .0044$ ) and OS (median, 23 vs. 17 months;  $P = .0091$ ).<sup>139</sup> An interesting finding was reported by Bolm et al (n = 214), in which adjuvant therapy (gemcitabine, gemcitabine + oxaliplatin, capecitabine, FOLFOX, chemoradiation, or unknown regimen) was beneficial for the pancreatobiliary subtype (improved median OS, 85 vs. 65 months for observation;  $P = .005$ ) but not the intestinal subtype.<sup>108</sup> According to the NCCN Panel, chemotherapy should be given prior to the administration of chemoradiation, if chemoradiation is being considered due to positive or close margins.





# NCCN Guidelines Version 2.2024

## Ampullary Adenocarcinoma

Despite many positive reports on the benefit of adjuvant therapy, there exists an equal amount of literature demonstrating no effect of adjuvant therapy on recurrence and survival outcomes.<sup>6,7,14,22,84,101,141-148</sup> It was shown in almost all of these studies that adjuvant therapy was more commonly used in patients with more advanced disease (poorly differentiated, higher T/N stage). In a recent retrospective study by Kang et al (n = 475), no benefit was noted with adjuvant 5-FU + leucovorin-based chemotherapy over observation in terms of both OS or recurrence-free survival (RFS), even after stratification by TNM stage. However, there seemed to be a particular benefit of this regimen versus observation for the intestinal subtype (5-year OS, 83.7% vs. 33.2% ;  $P = .015$ ; and RFS 46.5% vs. 24.9%;  $P = .035$ ), but not for the pancreatobiliary/mixed type.<sup>144</sup> Winter et al reported no benefit of adjuvant chemoradiation (5-FU plus 50.4 Gy) versus observation overall, but found a slight improvement in survival for patients with cancers with perineural invasion (30.4 vs. 12.5 months;  $P = .08$ ).<sup>84</sup>

The NCCN-recommended adjuvant therapy options for pancreatobiliary/mixed type ampullary cancer are gemcitabine (category 1), 5-FU + leucovorin (category 1), gemcitabine + capecitabine, gemcitabine + cisplatin, FOLFOX/CapeOx, capecitabine, and mFOLFIRINOX. Based on the same data, the NCCN-recommended adjuvant therapy options for intestinal type ampullary cancer include 5-FU + leucovorin (category 1), FOLFOX/CapeOx, and capecitabine.

The recommendations for 5-FU + leucovorin and gemcitabine are based on results of the ESPAC-3 trial.<sup>38</sup> In this phase III, randomized, open-label trial, patients with ampullary, bile duct, or other periampullary cancers were randomized to 5-FU + leucovorin, gemcitabine, or observation; a total of 297 patients with ampullary cancer were randomized; 100, 92, and 105 patients in each arm, respectively. The median survival for each arm was 57.8, 70.8, and 40.6 months, respectively. Statistical comparisons

between treatment arms were not reported for individual cancer types. When data for all 3 cancer types were combined, there was no significant difference in survival between treatment arms, but the HR for chemotherapy compared to observation was significant ( $P = .03$ ). The authors mentioned that there was no significant difference in survival between the pancreatobiliary subtype and the intestinal subtype in response to treatment; however, these data were not reported. The rate of treatment-related serious AEs was higher in those receiving 5-FU + leucovorin than in those receiving gemcitabine (49% vs. 30%;  $P = .002$ ). Based on the high level of evidence presented in this study, the NCCN Panel assigned a category 1 designation to gemcitabine and 5-FU + leucovorin for the adjuvant treatment of resected ampullary cancers. Gemcitabine is also used in the adjuvant setting in pancreatic cancer, based on data from CONKO-001.<sup>149</sup>

The recommendation for gemcitabine + capecitabine is based on extrapolation of data from ESPAC-4.<sup>150</sup> ESPAC-4 was a phase III, randomized, open-label trial that tested gemcitabine monotherapy or gemcitabine in combination with capecitabine for the adjuvant treatment of resected pancreatic cancer. A total of 730 patients were included in the final analysis, 366 in the gemcitabine arm and 364 in the gemcitabine + capecitabine arm. The median OS was 25.5 months and 28 months in the gemcitabine and gemcitabine + capecitabine arm, respectively ( $P = .032$ ). While 54% of patients in the monotherapy group experienced any grade 3–4 AEs, this rate was 63% in the combination arm.

The recommendation for gemcitabine + cisplatin is extrapolated from data of a phase II randomized trial that enrolled 410 patients with advanced biliary tract cancer.<sup>151</sup> Ampullary cancers were included, but the exact number was not reported. Patients with locally advanced or metastatic disease were randomly assigned to receive either gemcitabine + cisplatin (n = 204) or gemcitabine alone (n = 206). The median OS and median



# NCCN Guidelines Version 2.2024

## Ampullary Adenocarcinoma

progression-free survival (PFS) were significantly longer in the combination group versus the single-agent group: OS, 11.7 vs. 8.1 months;  $P < .001$  and PFS, 8.0 vs. 5.0 months;  $P < .001$ , respectively. The rates of any grade 3–4 AEs were similar between the 2 arms (70.7% vs. 68.8% for combination and single agent, respectively). Gemcitabine + cisplatin was not tested in the adjuvant setting in this trial, but other smaller trials tested adjuvant gemcitabine + cisplatin after surgery for biliary cancers.<sup>152,153</sup>

The recommendation for CapeOx is extrapolated from data of a phase II trial that enrolled a total of 31 patients with advanced small bowel and ampullary cancers, 12 of whom had ampullary cancer.<sup>154</sup> All patients had metastatic or unresectable tumors and no prior systemic chemotherapy. Everyone received CapeOx. The overall response rate was 50%, and the median OS was 20.4 months. The NCCN Panel deems FOLFOX a reasonable alternative to CapeOx based on clinical experience with these agents in periampullary cancers. CapeOx was not tested in the adjuvant setting in this trial. In addition, the recommendation of FOLFOX/CapeOx adjuvant therapy for intestinal type ampullary cancers is also derived from adjuvant FOLFOX/CapeOx chemotherapy trials in colon cancer.<sup>155,156</sup>

The recommendation for capecitabine is based on extrapolation of data from BILCAP, a phase III randomized trial that enrolled 447 patients with biliary tract cancer (cholangiocarcinoma or muscle-invasive gallbladder cancer).<sup>157</sup> In this study, patients were randomly assigned to capecitabine ( $n = 223$ ) or observation ( $n = 224$ ) after surgery. After a median follow-up of 60 months, the median OS was statistically similar between the two arms (51.1 vs. 36.4 months in the capecitabine vs. observation groups, respectively;  $P = .097$ ). Serious AEs were observed in 21% of patients in the capecitabine group and 10% of patients in the observation group. In addition, the recommendation for capecitabine adjuvant therapy for

intestinal type ampullary cancers is derived from the X-ACT study in colon cancer.<sup>158</sup>

The recommendation for mFOLFIRINOX is based on extrapolation of data from the PRODIGE 24/CCTG PA.6 phase III randomized trial in resected pancreatic cancer.<sup>159</sup> In this study, 493 patients with pancreatic cancer were randomly assigned to receive mFOLFIRINOX ( $n = 247$ ) or gemcitabine ( $n = 246$ ) postoperatively. The median PFS and median OS were significantly longer in the mFOLFIRINOX group compared to the gemcitabine group (21.6 vs. 12.8 months;  $P < .001$ ; and 54.4 vs. 35.0 months;  $P = .003$ , respectively). The rate of grade 3–4 AEs was higher in the mFOLFIRINOX group (75.9% vs. 52.9%).

### **Chemoradiation**

The NCCN recommendations for chemoradiation in ampullary cancer are similar to those in the [NCCN Guidelines for Pancreatic Adenocarcinoma](#), [NCCN Guidelines for Biliary Tract Cancers](#) for pancreatobiliary ampullary cancers, and [NCCN Guidelines for Small Bowel Adenocarcinoma](#) for intestinal type ampullary cancers. The preferred options for pancreatobiliary, mixed, and intestinal types are capecitabine + concurrent RT and 5-FU + concurrent RT, while gemcitabine + concurrent RT is recommended for pancreatobiliary type only. All three regimens have been reported in the literature, mostly in the adjuvant setting; however, these studies are usually small, retrospective, single-institutional, and heterogenous.<sup>16,109,111,125,136,137,140,148</sup> The most commonly used chemoradiation regimen in these studies is 5-FU–based. In a large analysis of data from the NCDB, in which 870 patients received adjuvant chemotherapy and 669 patients received adjuvant chemoradiation, it was observed that adjuvant chemotherapy use increased (9%–32% between 2004–2005 and 2012–2013) during the same time that adjuvant chemoradiation use decreased (20%–12% during the same time period).<sup>136</sup> As described in the previous section on adjuvant therapy, the





# NCCN Guidelines Version 2.2024

## Ampullary Adenocarcinoma

literature is split regarding the usefulness of adjuvant chemoradiation in patients with ampullary cancer.<sup>16,109,111,125,136,137,140,148</sup> A systematic review and meta-analysis of large databases was conducted using 10 retrospective studies including 3361 patients with ampullary cancer. Adjuvant RT was delivered with concurrent chemotherapy, mostly 5-FU, in all institutional studies. The results demonstrated that adjuvant chemoradiation significantly reduced the risk of death (HR, 0.75;  $P = .01$ ).<sup>137</sup> Several studies are in agreement that adjuvant chemoradiation seems to particularly benefit patients who are node positive, as mentioned in the previous section on adjuvant therapy.<sup>111,137,140</sup> A phase III, randomized EORTC trial tested adjuvant chemoradiation with 5-FU versus observation alone after surgery in patients with pancreatic head and periampullary cancers. Of the 103 patients assigned to the observation arm, 57 had pancreatic cancer, 44 had periampullary cancer, and 2 were unknown; of the 104 patients assigned to the treatment arm, 55 had pancreatic cancer, 48 had periampullary cancer, and 1 was unknown. However, it was not specified how many patients had ampullary cancer in this study. Regardless, the final results were not in favor of chemoradiation, showing no significant difference in median duration survival or 2-year survival rates between the two arms.<sup>160</sup> There is more high-level evidence on chemoradiation in the setting of pancreatic cancer, such as data from ESPAC-1, which can be extrapolated to ampullary cancer.<sup>161</sup> For more information on these studies, see the discussion section of the [NCCN Guidelines for Pancreatic Adenocarcinoma](#).

### Treatment of Metastatic Disease

Patients diagnosed with metastatic ampullary adenocarcinomas should receive genetic testing for hereditary mutations and molecular profiling of tumor tissue, if not previously done. Those with good performance status (PS; defined as ECOG 0–1 with good biliary drainage and adequate nutritional intake) can receive systemic therapy. Chemoradiation may be used for palliative indications. For select patients with oligometastatic

disease and response/stable disease to systemic therapy, local-directed therapy to liver or lung metastases may be considered after review in a multidisciplinary tumor board. Patients with poor PS should receive palliative and best supportive care and be considered for systemic chemotherapy, targeted therapy based on molecular profiling as clinically indicated, or for palliative RT (See *Principles of Radiation Therapy* and *Principles of Palliation and Supportive Care* in the algorithm). For specific systemic therapy regimen recommendations, see *Principles of Systemic Therapy* in the algorithm.

### First-Line Systemic Therapy

For pancreatobiliary/mixed type ampullary cancer with good PS, the recommendations for FOLFIRINOX/mFOLFIRINOX, gemcitabine + albumin-bound paclitaxel, gemcitabine + cisplatin, gemcitabine + cisplatin + durvalumab, and gemcitabine + capecitabine are derived from the [NCCN Guidelines for Pancreatic Adenocarcinoma](#) and the [NCCN Guidelines for Biliary Tract Cancers](#), with the addition of FOLFOX based on panel members' clinical experience. Most of these recommendations are based on phase II/III randomized data (FOLFIRINOX/mFOLFIRINOX,<sup>162,163</sup> gemcitabine + albumin-bound paclitaxel,<sup>164</sup> gemcitabine + cisplatin,<sup>151</sup> gemcitabine + cisplatin + durvalumab,<sup>165</sup> and gemcitabine + capecitabine<sup>166</sup>). For more information on these studies, see the discussion section of the [NCCN Guidelines for Pancreatic Adenocarcinoma](#) and [NCCN Guidelines for Biliary Tract Cancers](#). For pancreatobiliary/mixed type ampullary cancer with poor PS, simplified formulations of the same regimens for patients with good PS are recommended, with the goal of reducing toxicity. While gemcitabine, capecitabine, and 5-FU + leucovorin are appropriate for these patients, those with ECOG PS 2 can receive multi-agent regimens such as FOLFOX or gemcitabine + albumin-bound paclitaxel.



# NCCN Guidelines Version 2.2024

## Ampullary Adenocarcinoma

For intestinal type ampullary cancer, all recommendations are derived from the [NCCN Guidelines for Colon Cancer](#). Most of the recommendations are based on phase II/III, randomized data (FOLFOXIRI ± bevacizumab,<sup>167</sup> FOLFOX ± bevacizumab,<sup>168,169</sup> FOLFIRI ± bevacizumab,<sup>170</sup> and CapeOx ± bevacizumab<sup>168</sup>). While all of these options are appropriate for patients with good PS, 5-FU + leucovorin and capecitabine are considered appropriate options for those with poor PS, with the same rationale of reducing toxicity.<sup>169,171</sup> With the exception of FOLFOXIRI ± bevacizumab, all other regimens for good PS can also be used in select patients with ECOG PS 2. These patients can additionally receive 5-FU ± bevacizumab and capecitabine ± bevacizumab.<sup>171,172</sup> For more information on these studies, see the discussion section of the [NCCN Guidelines for Colon Cancer](#).

Due to the controversial role of anti-EGFR therapies in *KRAS* wild-type small bowel cancers or for right-sided colon cancers, the panel members do not recommend using anti-EGFR therapies for *KRAS* wild-type ampullary adenocarcinomas of intestinal subtype. Data with anti-EGFR-targeted therapies in ampullary adenocarcinomas are scant. Due to no data with tipiracil/tipifarnib ± bevacizumab or with regorafenib in small bowel cancers or intestinal subtype ampullary carcinomas, these agents are not recommended.

In addition to chemotherapy recommendations, pembrolizumab is a recommended option for all ampullary tumors with MSI-high (MSI-H), dMMR, or high TMB (TMB-H) (≥10 mut/Mb), and nivolumab + ipilimumab is a recommended option for MSI-H, dMMR intestinal type ampullary cancers. Patients can also receive larotrectinib or entrectinib if the tumors test positive for *NTRK* gene fusion. These options are applicable regardless of PS. With the exception of nivolumab + ipilimumab, the rationale for which comes from the metastatic colorectal cancer setting, the other four regimens are supported by basket trials that included many

different cancer types. No ampullary cancer and a very small number of periampullary cancers were included in these studies. Therefore, cautious extrapolation of data from these studies to the ampullary cancer setting is prudent.

The recommendation for pembrolizumab is supported by data from the phase II KEYNOTE-518 study, in which a total of 233 patients representing 27 tumor types were treated with pembrolizumab after failure with prior therapy.<sup>173</sup> The objective response rate was 34.3%, median PFS was 4.1 months, and median OS was 23.5 months. The rate of grade 3–5 treatment-related AEs was 14.6%. No patient with ampullary cancer was enrolled, although the trial included 24 patients with gastric cancer, 22 patients with cholangiocarcinoma, 22 patients with pancreatic cancer, and 19 patients with cancer of the small intestine.

The recommendation for nivolumab + ipilimumab is based on data in the metastatic colorectal cancer setting, hence its suitability only for intestinal type ampullary cancer.<sup>174</sup> In the phase II CheckMate 142 study, patients with no prior treatment received nivolumab + ipilimumab until disease progression. The objective response rate was 69%, while 2-year PFS and 2-year OS were 74% and 79%, respectively. The rate of grade 3–4 treatment-related AEs was 22%. This trial also included a cohort of previously treated patients. In this group (n = 119), the objective response rate was 55% and the 1-year PFS and 1-year OS were 71% and 85%, respectively. The rate of grade 3–4 treatment-related AEs was 32%.<sup>175</sup>

The recommendations for larotrectinib and entrectinib are supported by data from two phase I–II basket trials.<sup>176,177</sup> The first enrolled 55 patients, including 4 with colon cancer, 2 with cholangiocarcinoma, and 1 with pancreatic cancer, who were treated with larotrectinib. The overall response rate was 75%, and neither the median duration of response nor the median PFS was reached after a median follow-up of 9.9 months.<sup>176</sup> The second basket trial enrolled 54 patients, including 4 with colorectal



# NCCN Guidelines Version 2.2024

## Ampullary Adenocarcinoma

cancer, 3 with pancreatic cancer, and 1 with cholangiocarcinoma. Objective response was noted in 57% of patients and the median PFS and median OS were 11 months and 21 months, respectively.<sup>177</sup> Patients in both of these trials had received prior systemic therapy.

Based on the recent FDA approvals, dabrafenib + trametinib can be used as a treatment option for *BRAF* V600E-mutated ampullary adenocarcinomas with good or poor PS. This recommendation is based on data from 2 clinical trials.<sup>178,179</sup> NCI-MATCH Subprotocol H was an open-label study that evaluated dabrafenib + trametinib in patients with solid tumors, lymphomas, or multiple myeloma whose tumors harbored a *BRAF* V600E mutation. Overall, the response rate was 37.9% (n = 29), with a median duration of response of 25.1 months. With a median follow-up of 23 months, median OS was 28.6 months; median PFS was 11.4 months.<sup>178</sup> ROAR was a phase II, open-label basket trial in patients with *BRAF* V600E-mutated rare cancers. In 43 patients with *BRAF* V600E-mutated biliary tract cancer, the response rates by investigator and independent reviewer assessment were 51% and 47%, respectively. Median OS was 14 months and median PFS was 9 months.<sup>179</sup>

### Treatment for Disease Progression

Patients with disease progression and good PS should preferably be enrolled in clinical trials. Alternative options are systemic chemotherapy, or possibly targeted therapy based on molecular profiling as clinically indicated, or palliative RT for severe pain refractory to analgesic therapy. The second line of treatment includes palliative and best supportive care or clinical trial enrollment. Patients with disease progression and poor PS should receive palliative and best supportive care and be considered for systemic therapy, targeted therapy based on molecular profiling as clinically indicated, or palliative RT (See *Principles of Radiation Therapy* and *Principles of Palliation and Supportive Care* in the algorithm). For specific systemic therapy regimen recommendations, see *Principles of*

*Systemic Therapy* in the algorithm. For anyone receiving therapy for disease progression, serial imaging is recommended as indicated to assess disease response.

The recommendation for selpercatinib is supported by data from a phase I/II basket trial in *RET* fusion-positive solid tumors other than lung and thyroid tumors (LIBRETTO-001).<sup>180</sup> Among 41 patients with solid tumors, including pancreatic, biliary tract, and colorectal cancers, the overall response rate was 43.9% and the median duration of response was 24.5 months. The median PFS was 13.2 months. Among 11 patients with pancreatic cancer, the response rate was 54.5% and the median duration of response was not reached. The FDA approved selpercatinib as a treatment option for locally advanced or metastatic *RET* fusion-positive solid tumors.

### Subsequent-Line Systemic Therapy

For subsequent therapy for disease progression, the rule of thumb is that any regimen other than the one used in the first-line setting is a possible option. In patients with good PS and pancreatobiliary/mixed type ampullary cancer previously treated with a gemcitabine-based regimen, a fluoropyrimidine-based regimen is recommended for subsequent-line therapy. FOLFIRINOX<sup>181</sup> or mFOLFIRINOX and FOLFOX<sup>182-186</sup> can be used, as well as modifications to these regimens including 5-FU + leucovorin + liposomal irinotecan,<sup>187-189</sup> FOLFIRI,<sup>190-193</sup> OFF,<sup>149,182,194,195</sup> CapeOx,<sup>196</sup> capecitabine,<sup>197</sup> and 5-FU + leucovorin.<sup>149,187,195</sup> Vice versa, in patients with good PS and pancreatobiliary/mixed type ampullary cancer previously treated with a fluoropyrimidine-based regimen, a gemcitabine-based regimen is recommended for subsequent-line therapy. Gemcitabine + albumin-bound paclitaxel and gemcitabine + capecitabine can be used, as well as modifications to these regimens including gemcitabine. In addition, FOLFIRI<sup>190,191</sup> or 5-FU + leucovorin + liposomal irinotecan<sup>187</sup> can be tried in case of no progression on prior irinotecan. In patients with poor





# NCCN Guidelines Version 2.2024

## Ampullary Adenocarcinoma

PS and pancreatobiliary/mixed type ampullary cancer, gemcitabine,<sup>197</sup> capecitabine,<sup>197</sup> or 5-FU + leucovorin<sup>149,187,195</sup> can be used for disease progression, depending on the first-line regimen used. For patients with ECOG PS 2, multi-agent regimens such as FOLFOX and gemcitabine + albumin-bound paclitaxel are options, as well as CapeOx and FOLFIRI based on panel members' clinical experience.

In addition to these agents, gemcitabine + cisplatin for known *BRCA1/2/PALB2* mutations is recommended for patients with good PS in the subsequent-line setting. This recommendation is supported by data from a phase II randomized trial where 50 patients with previously untreated pancreatic cancer with germline *BRCA/PALB2* mutations were randomly assigned to gemcitabine + cisplatin or gemcitabine + cisplatin + veliparib. The response rate was 74.1% and 65.2% for each arm, respectively; median PFS was 10.1 months and 9.7 months, and median OS was 15.5 months and 16.4 months, respectively.<sup>198</sup>

Similar to recommendations for the first-line setting, all of the recommendations for the subsequent-line setting are derived from phase II/III data in pancreatic cancer or biliary cancer, with the exception of the reference for FOLFIRINOX, which is an exploratory analysis of the MPACT trial.<sup>181</sup> For more information on these studies, see the discussion sections of the [NCCN Guidelines for Pancreatic Adenocarcinoma](#) and [NCCN Guidelines for Biliary Tract Cancers](#).

For patients with good PS and intestinal type ampullary cancer, FOLFIRI ± bevacizumab is a possible subsequent-line option for patients previously treated with an oxaliplatin-based regimen. FOLFOX ± bevacizumab,<sup>168,169</sup> or CapeOx ± bevacizumab<sup>168</sup> can be used for patients previously treated with an irinotecan-based regimen. For patients with poor PS and intestinal type ampullary cancer, the same recommendations as those in the first-line setting apply (5-FU + leucovorin;<sup>199</sup> for those with ECOG PS 2: capecitabine ± bevacizumab, 5-FU ± bevacizumab,<sup>200</sup> FOLFOX ±

bevacizumab, FOLFIRI ± bevacizumab,<sup>201</sup> and CapeOx ± bevacizumab). Similar to recommendations for the first-line setting, all of the recommendations for the subsequent-line setting are derived from phase II/III data in colon cancer. For more information on these studies, see the discussion section of the [NCCN Guidelines for Colon Cancer](#).

Targeted therapy regimens recommended in the first-line setting are also possible options in the second-line setting: pembrolizumab, nivolumab + ipilimumab, larotrectinib, entrectinib, selpercatinib, and dabrafenib + trametinib. As explained in the previous section, trials demonstrating the efficacy of these regimens included all or a portion of patients who had received and progressed on prior systemic therapy.<sup>173,175-180</sup>

Furthermore, dostarlimab-gxly is recommended for good and poor PS in tumors with MSI-H or dMMR. This recommendation is based on results of a phase I basket study where a total of 209 patients, including 99 with gastrointestinal cancer (69 with colorectal cancer) who received dostarlimab-gxly until disease progression or discontinuation. The objective response rate was 41.6%.<sup>202</sup>

HER2 overexpression occurs in 13% of ampullary cancers, and HER2 targeting is relevant. HER2-targeted therapy is included in the [NCCN Guidelines for Biliary Tract Cancers](#) (applies to pancreatobiliary subtype). The FDA also recently approved tucatinib + trastuzumab for pretreated colorectal cancer. In the MY PATHWAY basket trial, among 114 patients, trastuzumab + pertuzumab conferred an overall response rate of 26%, and responses occurred in pancreatic (22%), biliary (29%), and colorectal (38%) cancers with HER2 amplifications, supporting the use of this combination in HER2-amplified ampullary carcinomas.<sup>203,204</sup> Of note, the NCCN Panel currently does not recommend HER2-targeted therapy as a treatment option for ampullary adenocarcinoma.

**References**

- Ahn DH, Bekaii-Saab T. Ampullary cancer: an overview. *Am Soc Clin Oncol Educ Book* 2014;112-115. Available at: <https://www.ncbi.nlm.nih.gov/pubmed/24857067>.
- Holzheimer RG, Mannick JA, eds. *Surgical Treatment: Evidence-Based and Problem-Oriented*. Munich: Zuckschwerdt. Copyright © 2001, W. Zuckschwerdt Verlag GmbH.; 2001.
- Westgaard A, Tafjord S, Farstad IN, et al. Pancreatobiliary versus intestinal histologic type of differentiation is an independent prognostic factor in resected periampullary adenocarcinoma. *BMC Cancer* 2008;8:170. Available at: <https://www.ncbi.nlm.nih.gov/pubmed/18547417>.
- Ramai D, Ofosu A, Singh J, et al. Demographics, tumor characteristics, treatment, and clinical outcomes of patients with ampullary cancer: a Surveillance, Epidemiology, and End Results (SEER) cohort study. *Minerva Gastroenterol Dietol* 2019;65:85-90. Available at: <https://www.ncbi.nlm.nih.gov/pubmed/30488680>.
- de Jong EJM, Geurts SME, van der Geest LG, et al. A population-based study on incidence, treatment, and survival in ampullary cancer in the Netherlands. *Eur J Surg Oncol* 2021;47:1742-1749. Available at: <https://www.ncbi.nlm.nih.gov/pubmed/33712346>.
- Balachandran P, Sikora SS, Kapoor S, et al. Long-term survival and recurrence patterns in ampullary cancer. *Pancreas* 2006;32:390-395. Available at: <https://www.ncbi.nlm.nih.gov/pubmed/16670621>.
- Hsu HP, Yang TM, Hsieh YH, et al. Predictors for patterns of failure after pancreaticoduodenectomy in ampullary cancer. *Ann Surg Oncol* 2007;14:50-60. Available at: <https://www.ncbi.nlm.nih.gov/pubmed/17054003>.
- Brown KM, Tompkins AJ, Yong S, et al. Pancreaticoduodenectomy is curative in the majority of patients with node-negative ampullary cancer. *Arch Surg* 2005;140:529-532; discussion 532-523. Available at: <https://www.ncbi.nlm.nih.gov/pubmed/15967899>.
- O'Connell JB, Maggard MA, Manunga J, Jr., et al. Survival after resection of ampullary carcinoma: a national population-based study. *Ann Surg Oncol* 2008;15:1820-1827. Available at: <https://www.ncbi.nlm.nih.gov/pubmed/18369675>.
- Sommerville CA, Limongelli P, Pai M, et al. Survival analysis after pancreatic resection for ampullary and pancreatic head carcinoma: an analysis of clinicopathological factors. *J Surg Oncol* 2009;100:651-656. Available at: <https://www.ncbi.nlm.nih.gov/pubmed/19722229>.
- Lemke J, Schafer D, Sander S, et al. Survival and prognostic factors in pancreatic and ampullary cancer. *Anticancer Res* 2014;34:3011-3020. Available at: <https://www.ncbi.nlm.nih.gov/pubmed/24922667>.
- Bettschart V, Rahman MQ, Engelken FJ, et al. Presentation, treatment and outcome in patients with ampullary tumours. *Br J Surg* 2004;91:1600-1607. Available at: <https://www.ncbi.nlm.nih.gov/pubmed/15515106>.
- Klein F, Jacob D, Bahra M, et al. Prognostic factors for long-term survival in patients with ampullary carcinoma: the results of a 15-year observation period after pancreaticoduodenectomy. *HPB Surg* 2014;2014:970234. Available at: <https://www.ncbi.nlm.nih.gov/pubmed/24723741>.
- Showalter TN, Zhan T, Anne PR, et al. The influence of prognostic factors and adjuvant chemoradiation on survival after pancreaticoduodenectomy for ampullary carcinoma. *J Gastrointest Surg* 2011;15:1411-1416. Available at: <https://www.ncbi.nlm.nih.gov/pubmed/21523621>.
- Qiao QL, Zhao YG, Ye ML, et al. Carcinoma of the ampulla of Vater: factors influencing long-term survival of 127 patients with resection. *World J Surg* 2007;31:137-143; discussion 144-136. Available at: <https://www.ncbi.nlm.nih.gov/pubmed/17171495>.
- Zhou YM, Liao S, Wei YZ, Wang SJ. Prognostic factors and benefits of adjuvant therapy for ampullary cancer following pancreatoduodenectomy: A systematic review and meta-analysis. *Asian J Surg* 2020;43:1133-1141. Available at: <https://www.ncbi.nlm.nih.gov/pubmed/32249101>.



# NCCN Guidelines Version 2.2024

## Ampullary Adenocarcinoma

17. He J, Ahuja N, Makary MA, et al. 2564 resected periampullary adenocarcinomas at a single institution: trends over three decades. *HPB (Oxford)* 2014;16:83-90. Available at: <https://www.ncbi.nlm.nih.gov/pubmed/23472829>.

18. Tol JA, Brosens LA, van Dieren S, et al. Impact of lymph node ratio on survival in patients with pancreatic and periampullary cancer. *Br J Surg* 2015;102:237-245. Available at: <https://www.ncbi.nlm.nih.gov/pubmed/25529117>.

19. Chen SC, Shyr YM, Wang SE. Longterm survival after pancreaticoduodenectomy for periampullary adenocarcinomas. *HPB (Oxford)* 2013;15:951-957. Available at: <https://www.ncbi.nlm.nih.gov/pubmed/23472708>.

20. Hatzaras I, George N, Muscarella P, et al. Predictors of survival in periampullary cancers following pancreaticoduodenectomy. *Ann Surg Oncol* 2010;17:991-997. Available at: <https://www.ncbi.nlm.nih.gov/pubmed/20108122>.

21. Jarufe NP, Coldham C, Mayer AD, et al. Favourable prognostic factors in a large UK experience of adenocarcinoma of the head of the pancreas and periampullary region. *Dig Surg* 2004;21:202-209. Available at: <https://www.ncbi.nlm.nih.gov/pubmed/15218236>.

22. Woo SM, Ryu JK, Lee SH, et al. Recurrence and prognostic factors of ampullary carcinoma after radical resection: comparison with distal extrahepatic cholangiocarcinoma. *Ann Surg Oncol* 2007;14:3195-3201. Available at: <https://www.ncbi.nlm.nih.gov/pubmed/17710498>.

23. Williams JL, Chan CK, Toste PA, et al. Association of histopathologic phenotype of periampullary adenocarcinomas with survival. *JAMA Surg* 2017;152:82-88. Available at: <https://www.ncbi.nlm.nih.gov/pubmed/27732711>.

24. El Nakeeb A, El Sorogy M, Ezzat H, et al. Predictors of long-term survival after pancreaticoduodenectomy for peri-ampullary adenocarcinoma: A retrospective study of 5-year survivors. *Hepatobiliary*

*Pancreat Dis Int* 2018;17:443-449. Available at: <https://www.ncbi.nlm.nih.gov/pubmed/30126828>.

25. Song KB, Kim SC, Lee W, et al. Laparoscopic pancreaticoduodenectomy for periampullary tumors: lessons learned from 500 consecutive patients in a single center. *Surg Endosc* 2020;34:1343-1352. Available at: <https://www.ncbi.nlm.nih.gov/pubmed/31214805>.

26. van Roessel S, Soer EC, Daamen LA, et al. Preoperative misdiagnosis of pancreatic and periampullary cancer in patients undergoing pancreatoduodenectomy: A multicentre retrospective cohort study. *Eur J Surg Oncol* 2021;47:2525-2532. Available at: <https://www.ncbi.nlm.nih.gov/pubmed/33745791>.

27. Leo JM, Kalloger SE, Peixoto RD, et al. Immunophenotyping of ampullary carcinomata allows for stratification of treatment specific subgroups. *J Clin Pathol* 2016;69:431-439. Available at: <https://www.ncbi.nlm.nih.gov/pubmed/26500334>.

28. Pomianowska E, Grzyb K, Westgaard A, et al. Reclassification of tumour origin in resected periampullary adenocarcinomas reveals underestimation of distal bile duct cancer. *Eur J Surg Oncol* 2012;38:1043-1050. Available at: <https://www.ncbi.nlm.nih.gov/pubmed/22883964>.

29. Kimura W, Futakawa N, Yamagata S, et al. Different clinicopathologic findings in two histologic types of carcinoma of papilla of Vater. *Jpn J Cancer Res* 1994;85:161-166. Available at: <https://www.ncbi.nlm.nih.gov/pubmed/7511574>.

30. Schueneman A, Goggins M, Ensor J, et al. Validation of histomolecular classification utilizing histological subtype, MUC1, and CDX2 for prognostication of resected ampullary adenocarcinoma. *Br J Cancer* 2015;113:64-68. Available at: <https://www.ncbi.nlm.nih.gov/pubmed/25989273>.

31. Chang DK, Jamieson NB, Johns AL, et al. Histomolecular phenotypes and outcome in adenocarcinoma of the ampulla of vater. *J Clin Oncol* 2013;31:1348-1356. Available at: <https://www.ncbi.nlm.nih.gov/pubmed/23439753>.





## NCCN Guidelines Version 2.2024 Ampullary Adenocarcinoma

32. Kawabata Y, Tanaka T, Nishisaka T, et al. Cytokeratin 20 (CK20) and apomucin 1 (MUC1) expression in ampullary carcinoma: Correlation with tumor progression and prognosis. *Diagn Pathol* 2010;5:75. Available at: <https://www.ncbi.nlm.nih.gov/pubmed/21106111>.
33. Kumari N, Prabha K, Singh RK, et al. Intestinal and pancreatobiliary differentiation in periampullary carcinoma: the role of immunohistochemistry. *Hum Pathol* 2013;44:2213-2219. Available at: <https://www.ncbi.nlm.nih.gov/pubmed/23834763>.
34. Ang DC, Shia J, Tang LH, et al. The utility of immunohistochemistry in subtyping adenocarcinoma of the ampulla of Vater. *Am J Surg Pathol* 2014;38:1371-1379. Available at: <https://www.ncbi.nlm.nih.gov/pubmed/24832159>.
35. Reid MD, Balci S, Ohike N, et al. Ampullary carcinoma is often of mixed or hybrid histologic type: an analysis of reproducibility and clinical relevance of classification as pancreatobiliary versus intestinal in 232 cases. *Mod Pathol* 2016;29:1575-1585. Available at: <https://www.ncbi.nlm.nih.gov/pubmed/27586202>.
36. Schiergens TS, Reu S, Neumann J, et al. Histomorphologic and molecular phenotypes predict gemcitabine response and overall survival in adenocarcinoma of the ampulla of Vater. *Surgery* 2015;158:151-161. Available at: <https://www.ncbi.nlm.nih.gov/pubmed/25819575>.
37. Nappo G, Galvanin J, Gentile D, et al. Long-term outcomes after pancreatoduodenectomy for ampullary cancer: The influence of the histological subtypes and comparison with the other periampullary neoplasms. *Pancreatol* 2021;21:950-956. Available at: <https://www.ncbi.nlm.nih.gov/pubmed/33795194>.
38. Neoptolemos JP, Moore MJ, Cox TF, et al. Effect of adjuvant chemotherapy with fluorouracil plus folinic acid or gemcitabine vs observation on survival in patients with resected periampullary adenocarcinoma: the ESPAC-3 periampullary cancer randomized trial. *JAMA* 2012;308:147-156. Available at: <https://www.ncbi.nlm.nih.gov/pubmed/22782416>.
39. Yovino S, Poppe M, Jabbour S, et al. Intensity-modulated radiation therapy significantly improves acute gastrointestinal toxicity in pancreatic and ampullary cancers. *Int J Radiat Oncol Biol Phys* 2011;79:158-162. Available at: <https://www.ncbi.nlm.nih.gov/pubmed/20399035>.
40. Schellenberg D, Kim J, Christman-Skieller C, et al. Single-fraction stereotactic body radiation therapy and sequential gemcitabine for the treatment of locally advanced pancreatic cancer. *Int J Radiat Oncol Biol Phys* 2011;81:181-188. Available at: <https://www.ncbi.nlm.nih.gov/pubmed/21549517>.
41. Loehrer PJ, Sr., Feng Y, Cardenes H, et al. Gemcitabine alone versus gemcitabine plus radiotherapy in patients with locally advanced pancreatic cancer: an Eastern Cooperative Oncology Group trial. *J Clin Oncol* 2011;29:4105-4112. Available at: <http://www.ncbi.nlm.nih.gov/pubmed/21969502>.
42. Hammel P, Huguet F, van Laethem JL, et al. Effect of chemoradiotherapy vs chemotherapy on survival in patients with locally advanced pancreatic cancer controlled after 4 months of gemcitabine with or without erlotinib: the LAP07 randomized clinical trial. *JAMA* 2016;315:1844-1853. Available at: <https://www.ncbi.nlm.nih.gov/pubmed/27139057>.
43. Marinova M, Feradova H, Gonzalez-Carmona MA, et al. Improving quality of life in pancreatic cancer patients following high-intensity focused ultrasound (HIFU) in two European centers. *Eur Radiol* 2021;31:5818-5829. Available at: <https://www.ncbi.nlm.nih.gov/pubmed/33486605>.
44. Valsangkar NP, Ingkakul T, Correa-Gallego C, et al. Survival in ampullary cancer: potential role of different KRAS mutations. *Surgery* 2015;157:260-268. Available at: <https://www.ncbi.nlm.nih.gov/pubmed/25616942>.
45. Kwon MJ, Kim JW, Jung JP, et al. Low incidence of KRAS, BRAF, and PIK3CA mutations in adenocarcinomas of the ampulla of Vater and their prognostic value. *Hum Pathol* 2016;50:90-100. Available at: <https://www.ncbi.nlm.nih.gov/pubmed/26997442>.



# NCCN Guidelines Version 2.2024

## Ampullary Adenocarcinoma

46. Jun SY, Kim M, Jin Gu M, et al. Clinicopathologic and prognostic associations of KRAS and BRAF mutations in small intestinal adenocarcinoma. *Mod Pathol* 2016;29:402-415. Available at: <https://www.ncbi.nlm.nih.gov/pubmed/26892442>.

47. Kinugasa H, Kanzaki H, Tanaka T, et al. The impact of KRAS mutation in patients with sporadic nonampullary duodenal epithelial tumors. *Clin Transl Gastroenterol* 2021;12:e00424. Available at: <https://www.ncbi.nlm.nih.gov/pubmed/34797780>.

48. Cox AD, Fesik SW, Kimmelman AC, et al. Drugging the undruggable RAS: Mission possible? *Nat Rev Drug Discov* 2014;13:828-851. Available at: <https://www.ncbi.nlm.nih.gov/pubmed/25323927>.

49. Kim BJ, Jang HJ, Kim JH, et al. KRAS mutation as a prognostic factor in ampullary adenocarcinoma: a meta-analysis and review. *Oncotarget* 2016;7:58001-58006. Available at: <https://www.ncbi.nlm.nih.gov/pubmed/27517148>.

50. Mikhitarian K, Pollen M, Zhao Z, et al. Epidermal growth factor receptor signaling pathway is frequently altered in ampullary carcinoma at protein and genetic levels. *Mod Pathol* 2014;27:665-674. Available at: <https://www.ncbi.nlm.nih.gov/pubmed/24186143>.

51. Hechtman JF, Liu W, Sadowska J, et al. Sequencing of 279 cancer genes in ampullary carcinoma reveals trends relating to histologic subtypes and frequent amplification and overexpression of ERBB2 (HER2). *Mod Pathol* 2015;28:1123-1129. Available at: <https://www.ncbi.nlm.nih.gov/pubmed/25975284>.

52. Chakraborty S, Ecker BL, Seier K, et al. Genome-derived classification Signature for ampullary adenocarcinoma to improve clinical cancer care. *Clin Cancer Res* 2021;27:5891-5899. Available at: <https://www.ncbi.nlm.nih.gov/pubmed/34433650>.

53. Moore PS, Orlandini S, Zamboni G, et al. Pancreatic tumours: molecular pathways implicated in ductal cancer are involved in ampullary but not in exocrine nonductal or endocrine tumorigenesis. *Br J Cancer*

2001;84:253-262. Available at: <https://www.ncbi.nlm.nih.gov/pubmed/11161385>.

54. Achille A, Scupoli MT, Magalini AR, et al. APC gene mutations and allelic losses in sporadic ampullary tumours: evidence of genetic difference from tumours associated with familial adenomatous polyposis. *Int J Cancer* 1996;68:305-312. Available at: <https://www.ncbi.nlm.nih.gov/pubmed/8903471>.

55. Achille A, Biasi MO, Zamboni G, et al. Cancers of the papilla of vater: mutator phenotype is associated with good prognosis. *Clin Cancer Res* 1997;3:1841-1847. Available at: <https://www.ncbi.nlm.nih.gov/pubmed/9815572>.

56. Harthimmer MR, Stolborg U, Pfeiffer P, et al. Mutational profiling and immunohistochemical analysis of a surgical series of ampullary carcinomas. *J Clin Pathol* 2019;72:762-770. Available at: <https://www.ncbi.nlm.nih.gov/pubmed/31256008>.

57. Wong W, Lowery MA, Berger MF, et al. Ampullary cancer: Evaluation of somatic and germline genetic alterations and association with clinical outcomes. *Cancer* 2019;125:1441-1448. Available at: <https://www.ncbi.nlm.nih.gov/pubmed/30620386>.

58. Kumari N, Singh RK, Mishra SK, et al. Identification of PI3K-AKT signaling as the dominant altered pathway in intestinal type ampullary cancers through whole-exome sequencing. *J Pathol Transl Med* 2021;55:192-201. Available at: <https://www.ncbi.nlm.nih.gov/pubmed/33677956>.

59. Yachida S, Wood LD, Suzuki M, et al. Genomic sequencing identifies ELF3 as a driver of ampullary carcinoma. *Cancer Cell* 2016;29:229-240. Available at: <https://www.ncbi.nlm.nih.gov/pubmed/26806338>.

60. Gingras MC, Covington KR, Chang DK, et al. Ampullary cancers harbor ELF3 tumor suppressor gene mutations and exhibit frequent WNT dysregulation. *Cell Rep* 2016;14:907-919. Available at: <https://www.ncbi.nlm.nih.gov/pubmed/26804919>.





# NCCN Guidelines Version 2.2024

## Ampullary Adenocarcinoma

61. Kumari N, Singh RK, Mishra SK, et al. Prevalence and spectrum of pathogenic germline variants in intestinal and pancreatobiliary type of ampullary cancer. *Pathol Res Pract* 2021;217:153309. Available at: <https://www.ncbi.nlm.nih.gov/pubmed/33341547>.
62. Lee SY, Jang KT, Lee KT, et al. Can endoscopic resection be applied for early stage ampulla of Vater cancer? *Gastrointest Endosc* 2006;63:783-788. Available at: <https://www.ncbi.nlm.nih.gov/pubmed/16650538>.
63. Kang SH, Kim KH, Kim TN, et al. Therapeutic outcomes of endoscopic papillectomy for ampullary neoplasms: retrospective analysis of a multicenter study. *BMC Gastroenterol* 2017;17:69. Available at: <https://www.ncbi.nlm.nih.gov/pubmed/28558658>.
64. Kim HN, Kim KM, Shin JU, et al. Prediction of carcinoma after resection in subjects with ampullary adenomas on endoscopic biopsy. *J Clin Gastroenterol* 2013;47:346-351. Available at: <https://www.ncbi.nlm.nih.gov/pubmed/23442830>.
65. Grobmyer SR, Stasik CN, Draganov P, et al. Contemporary results with ampullectomy for 29 "benign" neoplasms of the ampulla. *J Am Coll Surg* 2008;206:466-471. Available at: <https://www.ncbi.nlm.nih.gov/pubmed/18308217>.
66. Elek G, Gyori S, Toth B, Pap A. Histological evaluation of preoperative biopsies from ampulla vateri. *Pathol Oncol Res* 2003;9:32-41. Available at: <https://www.ncbi.nlm.nih.gov/pubmed/12704445>.
67. Menzel J, Poremba C, Dietl KH, et al. Tumors of the papilla of Vater--inadequate diagnostic impact of endoscopic forceps biopsies taken prior to and following sphincterotomy. *Ann Oncol* 1999;10:1227-1231. Available at: <https://www.ncbi.nlm.nih.gov/pubmed/10586341>.
68. Rodriguez C, Borda F, Elizalde I, et al. How accurate is preoperative diagnosis by endoscopic biopsies in ampullary tumours? *Rev Esp Enferm Dig* 2002;94:585-592. Available at: <https://www.ncbi.nlm.nih.gov/pubmed/12647408>.
69. Beger HG, Treitschke F, Gansauge F, et al. Tumor of the ampulla of Vater: experience with local or radical resection in 171 consecutively treated patients. *Arch Surg* 1999;134:526-532. Available at: <https://www.ncbi.nlm.nih.gov/pubmed/10323425>.
70. Roggin KK, Yeh JJ, Ferrone CR, et al. Limitations of ampullectomy in the treatment of nonfamilial ampullary neoplasms. *Ann Surg Oncol* 2005;12:971-980. Available at: <https://www.ncbi.nlm.nih.gov/pubmed/16244798>.
71. Bellizzi AM, Kahaleh M, Stelow EB. The assessment of specimens procured by endoscopic ampullectomy. *Am J Clin Pathol* 2009;132:506-513. Available at: <https://www.ncbi.nlm.nih.gov/pubmed/19762527>.
72. Alali A, Espino A, Moris M, et al. Endoscopic resection of ampullary tumours: Long-term outcomes and adverse events. *J Can Assoc Gastroenterol* 2020;3:17-25. Available at: <https://www.ncbi.nlm.nih.gov/pubmed/32010876>.
73. Askew J, Connor S. Review of the investigation and surgical management of resectable ampullary adenocarcinoma. *HPB (Oxford)* 2013;15:829-838. Available at: <https://www.ncbi.nlm.nih.gov/pubmed/23458317>.
74. Artifon EL, Couto D, Jr., Sakai P, da Silveira EB. Prospective evaluation of EUS versus CT scan for staging of ampullary cancer. *Gastrointest Endosc* 2009;70:290-296. Available at: <https://www.ncbi.nlm.nih.gov/pubmed/19523619>.
75. Okano N, Igarashi Y, Hara S, et al. Endosonographic preoperative evaluation for tumors of the ampulla of vater using endoscopic ultrasonography and intraductal ultrasonography. *Clin Endosc* 2014;47:174-177. Available at: <https://www.ncbi.nlm.nih.gov/pubmed/24765600>.
76. Chen WX, Xie QG, Zhang WF, et al. Multiple imaging techniques in the diagnosis of ampullary carcinoma. *Hepatobiliary Pancreat Dis Int* 2008;7:649-653. Available at: <https://www.ncbi.nlm.nih.gov/pubmed/19073413>.



# NCCN Guidelines Version 2.2024

## Ampullary Adenocarcinoma

77. Skordilis P, Mouzas IA, Dimoulios PD, et al. Is endosonography an effective method for detection and local staging of the ampullary carcinoma? A prospective study. *BMC Surg* 2002;2:1. Available at: <https://www.ncbi.nlm.nih.gov/pubmed/11914153>.

78. Chen CH, Yang CC, Yeh YH, et al. Reappraisal of endosonography of ampullary tumors: correlation with transabdominal sonography, CT, and MRI. *J Clin Ultrasound* 2009;37:18-25. Available at: <https://www.ncbi.nlm.nih.gov/pubmed/18726967>.

79. Ito K, Fujita N, Noda Y, et al. Preoperative evaluation of ampullary neoplasm with EUS and transpapillary intraductal US: a prospective and histopathologically controlled study. *Gastrointest Endosc* 2007;66:740-747. Available at: <https://www.ncbi.nlm.nih.gov/pubmed/17905017>.

80. Tien YW, Yeh CC, Wang SP, et al. Is blind pancreaticoduodenectomy justified for patients with ampullary neoplasms? *J Gastrointest Surg* 2009;13:1666-1673. Available at: <https://www.ncbi.nlm.nih.gov/pubmed/19557483>.

81. Cannon ME, Carpenter SL, Elta GH, et al. EUS compared with CT, magnetic resonance imaging, and angiography and the influence of biliary stenting on staging accuracy of ampullary neoplasms. *Gastrointest Endosc* 1999;50:27-33. Available at: <https://www.ncbi.nlm.nih.gov/pubmed/10385718>.

82. Chen CH, Tseng LJ, Yang CC, et al. The accuracy of endoscopic ultrasound, endoscopic retrograde cholangiopancreatography, computed tomography, and transabdominal ultrasound in the detection and staging of primary ampullary tumors. *Hepatogastroenterology* 2001;48:1750-1753. Available at: <https://www.ncbi.nlm.nih.gov/pubmed/11813616>.

83. Ridditid W, Schmidt SE, Al-Haddad MA, et al. Performance characteristics of EUS for locoregional evaluation of ampullary lesions. *Gastrointest Endosc* 2015;81:380-388. Available at: <https://www.ncbi.nlm.nih.gov/pubmed/25293823>.

84. Winter JM, Cameron JL, Olin K, et al. Clinicopathologic analysis of ampullary neoplasms in 450 patients: Implications for surgical strategy and

long-term prognosis. *J Gastrointest Surg* 2010;14:379-387. Available at: <https://doi.org/10.1007/s11605-009-1080-7>.

85. Burke CA, Beck GJ, Church JM, van Stolk RU. The natural history of untreated duodenal and ampullary adenomas in patients with familial adenomatous polyposis followed in an endoscopic surveillance program. *Gastrointest Endosc* 1999;49:358-364. Available at: <https://www.ncbi.nlm.nih.gov/pubmed/10049420>.

86. Stolte M, Pscherer C. Adenoma-carcinoma sequence in the papilla of Vater. *Scand J Gastroenterol* 1996;31:376-382. Available at: <https://www.ncbi.nlm.nih.gov/pubmed/8726307>.

87. Wen KW, Kim GE, Rabinovitch PS, et al. Diagnosis, risk stratification, and management of ampullary dysplasia by DNA flow cytometric analysis of paraffin-embedded tissue. *Mod Pathol* 2019;32:1291-1302. Available at: <https://www.ncbi.nlm.nih.gov/pubmed/30976103>.

88. Cheng CL, Sherman S, Fogel EL, et al. Endoscopic snare papillectomy for tumors of the duodenal papillae. *Gastrointest Endosc* 2004;60:757-764. Available at: <https://www.ncbi.nlm.nih.gov/pubmed/15557951>.

89. Bohnacker S, Seitz U, Nguyen D, et al. Endoscopic resection of benign tumors of the duodenal papilla without and with intraductal growth. *Gastrointest Endosc* 2005;62:551-560. Available at: <https://www.ncbi.nlm.nih.gov/pubmed/16185970>.

90. Onkendi EO, Naik ND, Rosedahl JK, et al. Adenomas of the ampulla of Vater: a comparison of outcomes of operative and endoscopic resections. *J Gastrointest Surg* 2014;18:1588-1596. Available at: <https://www.ncbi.nlm.nih.gov/pubmed/24916584>.

91. Ceppa EP, Burbridge RA, Rialon KL, et al. Endoscopic versus surgical ampullectomy: an algorithm to treat disease of the ampulla of Vater. *Ann Surg* 2013;257:315-322. Available at: <https://www.ncbi.nlm.nih.gov/pubmed/23059497>.



# NCCN Guidelines Version 2.2024

## Ampullary Adenocarcinoma

92. Clary BM, Tyler DS, Dematos P, et al. Local ampullary resection with careful intraoperative frozen section evaluation for presumed benign ampullary neoplasms. *Surgery* 2000;127:628-633. Available at: <https://www.ncbi.nlm.nih.gov/pubmed/10840357>.
93. van der Wiel SE, Poley JW, Koch AD, Bruno MJ. Endoscopic resection of advanced ampullary adenomas: a single-center 14-year retrospective cohort study. *Surg Endosc* 2019;33:1180-1188. Available at: <https://www.ncbi.nlm.nih.gov/pubmed/30167949>.
94. Napoleon B, Gincul R, Ponchon T, et al. Endoscopic papillectomy for early ampullary tumors: long-term results from a large multicenter prospective study. *Endoscopy* 2014;46:127-134. Available at: <https://www.ncbi.nlm.nih.gov/pubmed/24477368>.
95. Ridditid W, Tan D, Schmidt SE, et al. Endoscopic papillectomy: risk factors for incomplete resection and recurrence during long-term follow-up. *Gastrointest Endosc* 2014;79:289-296. Available at: <https://www.ncbi.nlm.nih.gov/pubmed/24094466>.
96. Catalano MF, Linder JD, Chak A, et al. Endoscopic management of adenoma of the major duodenal papilla. *Gastrointest Endosc* 2004;59:225-232. Available at: <https://www.ncbi.nlm.nih.gov/pubmed/14745396>.
97. Irani S, Arai A, Ayub K, et al. Papillectomy for ampullary neoplasm: results of a single referral center over a 10-year period. *Gastrointest Endosc* 2009;70:923-932. Available at: <https://www.ncbi.nlm.nih.gov/pubmed/19608181>.
98. Angsuwatcharakon P, Ahmed O, Lynch PM, et al. Management of ampullary adenomas in familial adenomatous polyposis syndrome: 16 years of experience from a tertiary cancer center. *Gastrointest Endosc* 2020;92:323-330. Available at: <https://www.ncbi.nlm.nih.gov/pubmed/32145286>.
99. Mendonça EQ, Bernardo WM, Moura EG, et al. Endoscopic versus surgical treatment of ampullary adenomas: a systematic review and meta-analysis. *Clinics (Sao Paulo)* 2016;71:28-35. Available at:
100. Di Giorgio A, Alfieri S, Rotondi F, et al. Pancreatoduodenectomy for tumors of Vater's ampulla: report on 94 consecutive patients. *World J Surg* 2005;29:513-518. Available at: <https://www.ncbi.nlm.nih.gov/pubmed/15776300>.
101. Duffy JP, Hines OJ, Liu JH, et al. Improved survival for adenocarcinoma of the ampulla of Vater: fifty-five consecutive resections. *Arch Surg* 2003;138:941-948; discussion 948-950. Available at: <https://www.ncbi.nlm.nih.gov/pubmed/12963649>.
102. Dembinski J, Yoh T, Aussilhou B, et al. The long-term outcomes of laparoscopic versus open pancreatoduodenectomy for ampullary carcinoma showed similar survival: a case-matched comparative study. *Surg Endosc* 2022;36:4732-4740. Available at: <https://www.ncbi.nlm.nih.gov/pubmed/34724575>.
103. Todoroki T, Koike N, Morishita Y, et al. Patterns and predictors of failure after curative resections of carcinoma of the ampulla of Vater. *Ann Surg Oncol* 2003;10:1176-1183. Available at: <https://www.ncbi.nlm.nih.gov/pubmed/14654474>.
104. Lazaryan A, Kalmadi S, Almhanna K, et al. Predictors of clinical outcomes of resected ampullary adenocarcinoma: a single-institution experience. *Eur J Surg Oncol* 2011;37:791-797. Available at: <https://www.ncbi.nlm.nih.gov/pubmed/21741199>.
105. Allema JH, Reinders ME, van Gulik TM, et al. Results of pancreaticoduodenectomy for ampullary carcinoma and analysis of prognostic factors for survival. *Surgery* 1995;117:247-253. Available at: <https://www.ncbi.nlm.nih.gov/pubmed/7878528>.
106. Park HM, Park SJ, Han SS, et al. Very early recurrence following pancreaticoduodenectomy in patients with ampullary cancer. *Medicine (Baltimore)* 2019;98:e17711. Available at: <https://www.ncbi.nlm.nih.gov/pubmed/31689805>.
107. Song J, Liu H, Li Z, et al. Long-term prognosis of surgical treatment for early ampullary cancers and implications for local ampullectomy. *BMC*





# NCCN Guidelines Version 2.2024

## Ampullary Adenocarcinoma

Surg 2015;15:32. Available at:

<https://www.ncbi.nlm.nih.gov/pubmed/25888004>.

108. Bolm L, Ohrner K, Nappo G, et al. Adjuvant therapy is associated with improved overall survival in patients with pancreatobiliary or mixed subtype ampullary cancer after pancreatoduodenectomy - A multicenter cohort study. *Pancreatology* 2020;20:433-441. Available at:

<https://www.ncbi.nlm.nih.gov/pubmed/31987649>.

109. Ha HR, Oh DY, Kim TY, et al. Survival outcomes according to adjuvant treatment and prognostic factors including host immune markers in patients with curatively resected ampulla of Vater cancer. *PLoS One* 2016;11:e0151406. Available at:

<https://www.ncbi.nlm.nih.gov/pubmed/26974670>.

110. Kim H, Kwon W, Kim JR, et al. Recurrence patterns after pancreaticoduodenectomy for ampullary cancer. *J Hepatobiliary Pancreat Sci* 2019;26:179-186. Available at:

<https://www.ncbi.nlm.nih.gov/pubmed/30849209>.

111. Narang AK, Miller RC, Hsu CC, et al. Evaluation of adjuvant chemoradiation therapy for ampullary adenocarcinoma: the Johns Hopkins Hospital-Mayo Clinic collaborative study. *Radiat Oncol* 2011;6:126. Available at: <https://www.ncbi.nlm.nih.gov/pubmed/21951377>.

112. Sakata J, Shirai Y, Wakai T, et al. Assessment of the nodal status in ampullary carcinoma: the number of positive lymph nodes versus the lymph node ratio. *World J Surg* 2011;35:2118-2124. Available at:

<https://www.ncbi.nlm.nih.gov/pubmed/21717240>.

113. Nassour I, Christie A, Choti MA, et al. Determining the adequate examined lymph node count in resected ampullary adenocarcinoma-A national cohort study. *J Gastrointest Surg* 2018;22:792-801. Available at:

<https://www.ncbi.nlm.nih.gov/pubmed/29546687>.

114. Balci S, Basturk O, Saka B, et al. Substaging nodal status in ampullary carcinomas has significant prognostic value: Proposed revised staging based on an analysis of 313 well-characterized cases. *Ann Surg*

Oncol 2015;22:4392-4401. Available at:

<https://www.ncbi.nlm.nih.gov/pubmed/25783680>.

115. Partelli S, Crippa S, Capelli P, et al. Adequacy of lymph node retrieval for ampullary cancer and its association with improved staging and survival. *World J Surg* 2013;37:1397-1404. Available at:

<https://www.ncbi.nlm.nih.gov/pubmed/23546531>.

116. Rattner DW, Fernandez-del Castillo C, Brugge WR, Warshaw AL. Defining the criteria for local resection of ampullary neoplasms. *Arch Surg* 1996;131:366-371. Available at:

<https://www.ncbi.nlm.nih.gov/pubmed/8615720>.

117. Palanivelu C, Senthilnathan P, Sabnis SC, et al. Randomized clinical trial of laparoscopic versus open pancreatoduodenectomy for periampullary tumours. *Br J Surg* 2017;104:1443-1450. Available at:

<https://www.ncbi.nlm.nih.gov/pubmed/28895142>.

118. Senthilnathan P, Srivatsan Gurumurthy S, Gul SI, et al. Long-term results of laparoscopic pancreaticoduodenectomy for pancreatic and periampullary cancer-experience of 130 cases from a tertiary-care center in South India. *J Laparoendosc Adv Surg Tech A* 2015;25:295-300. Available at: <https://www.ncbi.nlm.nih.gov/pubmed/25789541>.

119. Nassour I, Wang SC, Christie A, et al. Minimally invasive versus open pancreaticoduodenectomy: A propensity-matched study from a national cohort of patients. *Ann Surg* 2018;268:151-157. Available at:

<https://www.ncbi.nlm.nih.gov/pubmed/28486387>.

120. Zureikat AH, Beane JD, Zenati MS, et al. 500 minimally invasive robotic pancreatoduodenectomies: One decade of optimizing performance. *Ann Surg* 2021;273:966-972. Available at:

<https://www.ncbi.nlm.nih.gov/pubmed/31851003>.

121. Park JS, Yoon DS, Kim KS, et al. Factors influencing recurrence after curative resection for ampulla of Vater carcinoma. *J Surg Oncol* 2007;95:286-290. Available at:

<https://www.ncbi.nlm.nih.gov/pubmed/17326125>.



# NCCN Guidelines Version 2.2024

## Ampullary Adenocarcinoma

122. Guo M, Beal EW, Miller ED, et al. Neoadjuvant therapy versus surgery first for ampullary carcinoma: A propensity score-matched analysis of the NCDB. *J Surg Oncol* 2021;123:1558-1567. Available at: <https://www.ncbi.nlm.nih.gov/pubmed/33596343>.

123. Adam MA, Glencer A, AlMasri S, et al. Neoadjuvant therapy versus upfront resection for nonpancreatic periampullary adenocarcinoma. *Ann Surg Oncol* 2022. Available at: <https://www.ncbi.nlm.nih.gov/pubmed/35925536>.

124. Cloyd JM, Wang H, Overman M, et al. Influence of preoperative therapy on short- and long-term outcomes of patients with adenocarcinoma of the ampulla of Vater. *Ann Surg Oncol* 2017;24:2031-2039. Available at: <https://www.ncbi.nlm.nih.gov/pubmed/28124275>.

125. Palta M, Patel P, Broadwater G, et al. Carcinoma of the ampulla of Vater: patterns of failure following resection and benefit of chemoradiotherapy. *Ann Surg Oncol* 2012;19:1535-1540. Available at: <https://www.ncbi.nlm.nih.gov/pubmed/22045467>.

126. Varadhachary GR, Wolff RA, Crane CH, et al. Preoperative gemcitabine and cisplatin followed by gemcitabine-based chemoradiation for resectable adenocarcinoma of the pancreatic head. *J Clin Oncol* 2008;26:3487-3495. Available at: <https://www.ncbi.nlm.nih.gov/pubmed/18640929>.

127. Palmer DH, Stocken DD, Hewitt H, et al. A randomized phase 2 trial of neoadjuvant chemotherapy in resectable pancreatic cancer: gemcitabine alone versus gemcitabine combined with cisplatin. *Ann Surg Oncol* 2007;14:2088-2096. Available at: <https://www.ncbi.nlm.nih.gov/pubmed/17453298>.

128. Evans DB, Varadhachary GR, Crane CH, et al. Preoperative gemcitabine-based chemoradiation for patients with resectable adenocarcinoma of the pancreatic head. *J Clin Oncol* 2008;26:3496-3502. Available at: <https://www.ncbi.nlm.nih.gov/pubmed/18640930>.

129. Ettrich TJ, Uhl W, Kornmann M, et al. Perioperative or adjuvant nab-paclitaxel plus gemcitabine for resectable pancreatic cancer: Updated final

results of the randomized phase II AIO-NEONAX trial. *J Clin Oncol* 2022;40:4133-4133. Available at: [https://ascopubs.org/doi/abs/10.1200/JCO.2022.40.16\\_suppl.4133](https://ascopubs.org/doi/abs/10.1200/JCO.2022.40.16_suppl.4133).

130. Sohal DPS, Duong M, Ahmad SA, et al. Efficacy of perioperative chemotherapy for resectable pancreatic adenocarcinoma: A phase 2 randomized clinical trial. *JAMA Oncol* 2021;7:421-427. Available at: <https://www.ncbi.nlm.nih.gov/pubmed/33475684>.

131. Katz MHG, Shi Q, Meyers J, et al. Efficacy of preoperative mFOLFIRINOX vs mFOLFIRINOX plus hypofractionated radiotherapy for borderline resectable adenocarcinoma of the pancreas: The A021501 phase 2 randomized clinical trial. *JAMA Oncol* 2022;8:1263-1270. Available at: <https://www.ncbi.nlm.nih.gov/pubmed/35834226>.

132. Zhou H, Song Y, Jiang J, et al. A pilot phase II study of neoadjuvant triplet chemotherapy regimen in patients with locally advanced resectable colon cancer. *Chin J Cancer Res* 2016;28:598-605. Available at: <https://www.ncbi.nlm.nih.gov/pubmed/28174488>.

133. Cremolini C, Antoniotti C, Rossini D, et al. Upfront FOLFOXIRI plus bevacizumab and reintroduction after progression versus mFOLFOX6 plus bevacizumab followed by FOLFIRI plus bevacizumab in the treatment of patients with metastatic colorectal cancer (TRIBE2): a multicentre, open-label, phase 3, randomised, controlled trial. *Lancet Oncol* 2020;21:497-507. Available at: <https://www.ncbi.nlm.nih.gov/pubmed/32164906>.

134. Cremolini C, Loupakis F, Antoniotti C, et al. FOLFOXIRI plus bevacizumab versus FOLFIRI plus bevacizumab as first-line treatment of patients with metastatic colorectal cancer: updated overall survival and molecular subgroup analyses of the open-label, phase 3 TRIBE study. *Lancet Oncol* 2015;16:1306-1315. Available at: <https://www.ncbi.nlm.nih.gov/pubmed/26338525>.

135. Seymour MT, Morton D, Investigators obotIFT. FOxTROT: an international randomised controlled trial in 1052 patients (pts) evaluating neoadjuvant chemotherapy (NAC) for colon cancer. *J Clin Oncol* 2019;37:3504-3504. Available at: [https://ascopubs.org/doi/abs/10.1200/JCO.2019.37.15\\_suppl.3504](https://ascopubs.org/doi/abs/10.1200/JCO.2019.37.15_suppl.3504).



# NCCN Guidelines Version 2.2024

## Ampullary Adenocarcinoma

136. Nassour I, Hynan LS, Christie A, et al. Association of adjuvant therapy with improved survival in ampullary cancer: A national cohort study. *J Gastrointest Surg* 2018;22:695-702. Available at: <https://www.ncbi.nlm.nih.gov/pubmed/29127604>.

137. Kwon J, Kim BH, Kim K, et al. Survival benefit of adjuvant chemoradiotherapy in patients with ampulla of Vater cancer: A systematic review and meta-analysis. *Ann Surg* 2015;262:47-52. Available at: <https://www.ncbi.nlm.nih.gov/pubmed/25775067>.

138. Jin Z, Hartgers ML, Sanhueza CT, et al. Prognostic factors and benefits of adjuvant therapy after pancreatoduodenectomy for ampullary adenocarcinoma: Mayo Clinic experience. *Eur J Surg Oncol* 2018;44:677-683. Available at: <https://www.ncbi.nlm.nih.gov/pubmed/29506768>.

139. Kamarajah SK. Adjuvant radiotherapy following pancreaticoduodenectomy for ampullary adenocarcinoma improves survival in node-positive patients: a propensity score analysis. *Clin Transl Oncol* 2018;20:1212-1218. Available at: <https://www.ncbi.nlm.nih.gov/pubmed/29497964>.

140. Bhatia S, Miller RC, Haddock MG, et al. Adjuvant therapy for ampullary carcinomas: the Mayo Clinic experience. *Int J Radiat Oncol Biol Phys* 2006;66:514-519. Available at: <https://www.ncbi.nlm.nih.gov/pubmed/16863684>.

141. Stiles ZE, Behrman SW, Deneve JL, et al. Ampullary adenocarcinoma: Defining predictors of survival and the impact of adjuvant therapy following surgical resection for stage I disease. *J Surg Oncol* 2018;117:1500-1508. Available at: <https://www.ncbi.nlm.nih.gov/pubmed/29518820>.

142. Chavez MT, Sharpe JP, O'Brien T, et al. Management and outcomes following pancreaticoduodenectomy for ampullary adenocarcinoma. *Am J Surg* 2017;214:856-861. Available at: <https://www.ncbi.nlm.nih.gov/pubmed/28285709>.

143. Sikora SS, Balachandran P, Dimri K, et al. Adjuvant chemoradiotherapy in ampullary cancers. *Eur J Surg Oncol* 2005;31:158-163. Available at: <https://www.ncbi.nlm.nih.gov/pubmed/15698732>.

144. Kang J, Lee W, Shin J, et al. Controversial benefit of 5-fluorouracil/leucovorin-based adjuvant chemotherapy for ampullary cancer: a propensity score-matched analysis. *Langenbecks Arch Surg* 2022;407:1091-1097. Available at: <https://www.ncbi.nlm.nih.gov/pubmed/35013798>.

145. Al-Jumayli M, Batool A, Middiniti A, et al. Clinical outcome of ampullary carcinoma: Single cancer center Experience. *J Oncol* 2019;2019:3293509. Available at: <https://www.ncbi.nlm.nih.gov/pubmed/31186632>.

146. Krishnan S, Rana V, Evans DB, et al. Role of adjuvant chemoradiation therapy in adenocarcinomas of the ampulla of vater. *Int J Radiat Oncol Biol Phys* 2008;70:735-743. Available at: <https://www.ncbi.nlm.nih.gov/pubmed/17980502>.

147. Manne A, Hatic H, Li P, et al. The clinical benefit of adjuvant therapy in long-term survival of early-stage ampullary carcinoma: A single institutional experience. *J Clin Med Res* 2020;12:560-567. Available at: <https://www.ncbi.nlm.nih.gov/pubmed/32849944>.

148. Zhou J, Hsu CC, Winter JM, et al. Adjuvant chemoradiation versus surgery alone for adenocarcinoma of the ampulla of Vater. *Radiother Oncol* 2009;92:244-248. Available at: <https://www.ncbi.nlm.nih.gov/pubmed/19541379>.

149. Oettle H, Neuhaus P, Hochhaus A, et al. Adjuvant chemotherapy with gemcitabine and long-term outcomes among patients with resected pancreatic cancer: the CONKO-001 randomized trial. *JAMA* 2013;310:1473-1481. Available at: <http://www.ncbi.nlm.nih.gov/pubmed/24104372>.

150. Neoptolemos JP, Palmer DH, Ghaneh P, et al. Comparison of adjuvant gemcitabine and capecitabine with gemcitabine monotherapy in patients with resected pancreatic cancer (ESPAC-4): a multicentre, open-





# NCCN Guidelines Version 2.2024

## Ampullary Adenocarcinoma

label, randomised, phase 3 trial. *Lancet* 2017;389:1011-1024. Available at: <https://www.ncbi.nlm.nih.gov/pubmed/28129987>.

151. Valle J, Wasan H, Palmer DH, et al. Cisplatin plus gemcitabine versus gemcitabine for biliary tract cancer. *N Engl J Med* 2010;362:1273-1281. Available at: <https://www.ncbi.nlm.nih.gov/pubmed/20375404>.

152. Mori S, Aoki T, Shiraki T, et al. Efficacy and feasibility of adjuvant gemcitabine plus cisplatin chemotherapy after major hepatectomy for biliary tract cancer. *Anticancer Res* 2021;41:5231-5240. Available at: <https://www.ncbi.nlm.nih.gov/pubmed/34593476>.

153. Siebenhuner AR, Seifert H, Bachmann H, et al. Adjuvant treatment of resectable biliary tract cancer with cisplatin plus gemcitabine: A prospective single center phase II study. *BMC Cancer* 2018;18:72. Available at: <https://www.ncbi.nlm.nih.gov/pubmed/29325521>.

154. Overman MJ, Varadhachary GR, Kopetz S, et al. Phase II study of capecitabine and oxaliplatin for advanced adenocarcinoma of the small bowel and ampulla of Vater. *J Clin Oncol* 2009;27:2598-2603. Available at: <https://www.ncbi.nlm.nih.gov/pubmed/19164203>.

155. Andre T, Boni C, Mounedji-Boudiaf L, et al. Oxaliplatin, fluorouracil, and leucovorin as adjuvant treatment for colon cancer. *N Engl J Med* 2004;350:2343-2351. Available at: <https://www.ncbi.nlm.nih.gov/pubmed/15175436>.

156. Haller DG, Tabernero J, Maroun J, et al. Capecitabine plus oxaliplatin compared with fluorouracil and folinic acid as adjuvant therapy for stage III colon cancer. *J Clin Oncol* 2011;29:1465-1471. Available at: <https://www.ncbi.nlm.nih.gov/pubmed/21383294>.

157. Primrose JN, Fox RP, Palmer DH, et al. Capecitabine compared with observation in resected biliary tract cancer (BILCAP): a randomised, controlled, multicentre, phase 3 study. *Lancet Oncol* 2019;20:663-673. Available at: <https://www.ncbi.nlm.nih.gov/pubmed/30922733>.

158. Twelves C, Wong A, Nowacki MP, et al. Capecitabine as adjuvant treatment for stage III colon cancer. *N Engl J Med* 2005;352:2696-2704. Available at: <https://www.ncbi.nlm.nih.gov/pubmed/15987918>.

159. Conroy T, Hammel P, Hebbar M, et al. FOLFIRINOX or gemcitabine as adjuvant therapy for pancreatic cancer. *N Engl J Med* 2018;379:2395-2406. Available at: <https://www.ncbi.nlm.nih.gov/pubmed/30575490>.

160. Klinkenbijn JH, Jeekel J, Sahmoud T, et al. Adjuvant radiotherapy and 5-fluorouracil after curative resection of cancer of the pancreas and periampullary region: phase III trial of the EORTC gastrointestinal tract cancer cooperative group. *Ann Surg* 1999;230:776-782; discussion 782-774. Available at: <https://www.ncbi.nlm.nih.gov/pubmed/10615932>.

161. Neoptolemos JP, Stocken DD, Friess H, et al. A randomized trial of chemoradiotherapy and chemotherapy after resection of pancreatic cancer. *N Engl J Med* 2004;350:1200-1210. Available at: <https://www.ncbi.nlm.nih.gov/pubmed/15028824>.

162. Conroy T, Desseigne F, Ychou M, et al. FOLFIRINOX versus gemcitabine for metastatic pancreatic cancer. *N Engl J Med* 2011;364:1817-1825. Available at: <http://www.ncbi.nlm.nih.gov/pubmed/21561347>.

163. Stein SM, James ES, Deng Y, et al. Final analysis of a phase II study of modified FOLFIRINOX in locally advanced and metastatic pancreatic cancer. *Br J Cancer* 2016;114:737-743. Available at: <https://www.ncbi.nlm.nih.gov/pubmed/27022826>.

164. Von Hoff DD, Ervin T, Arena FP, et al. Increased survival in pancreatic cancer with nab-paclitaxel plus gemcitabine. *N Engl J Med* 2013;369:1691-1703. Available at: <http://www.ncbi.nlm.nih.gov/pubmed/24131140>.

165. Oh D-Y, Ruth He A, Qin S, et al. Durvalumab plus gemcitabine and cisplatin in advanced biliary tract cancer. *NEJM Evidence* 2022;1:EVIDoA2200015. Available at: <https://doi.org/10.1056/EVIDoA2200015>.





# NCCN Guidelines Version 2.2024

## Ampullary Adenocarcinoma

166. Cunningham D, Chau I, Stocken DD, et al. Phase III randomized comparison of gemcitabine versus gemcitabine plus capecitabine in patients with advanced pancreatic cancer. *J Clin Oncol* 2009;27:5513-5518. Available at: <https://www.ncbi.nlm.nih.gov/pubmed/19858379>.

167. Falcone A, Ricci S, Brunetti I, et al. Phase III trial of infusional fluorouracil, leucovorin, oxaliplatin, and irinotecan (FOLFOXIRI) compared with infusional fluorouracil, leucovorin, and irinotecan (FOLFIRI) as first-line treatment for metastatic colorectal cancer: the Gruppo Oncologico Nord Ovest. *J Clin Oncol* 2007;25:1670-1676. Available at: <https://www.ncbi.nlm.nih.gov/pubmed/17470860>.

168. Saltz LB, Clarke S, Diaz-Rubio E, et al. Bevacizumab in combination with oxaliplatin-based chemotherapy as first-line therapy in metastatic colorectal cancer: a randomized phase III study. *J Clin Oncol* 2008;26:2013-2019. Available at: <https://www.ncbi.nlm.nih.gov/pubmed/18421054>.

169. de Gramont A, Figer A, Seymour M, et al. Leucovorin and fluorouracil with or without oxaliplatin as first-line treatment in advanced colorectal cancer. *J Clin Oncol* 2000;18:2938-2947. Available at: <https://www.ncbi.nlm.nih.gov/pubmed/10944126>.

170. Fuchs CS, Marshall J, Mitchell E, et al. Randomized, controlled trial of irinotecan plus infusional, bolus, or oral fluoropyrimidines in first-line treatment of metastatic colorectal cancer: results from the BICC-C Study. *J Clin Oncol* 2007;25:4779-4786. Available at: <https://www.ncbi.nlm.nih.gov/pubmed/17947725>.

171. Van Cutsem E, Twelves C, Cassidy J, et al. Oral capecitabine compared with intravenous fluorouracil plus leucovorin in patients with metastatic colorectal cancer: results of a large phase III study. *J Clin Oncol* 2001;19:4097-4106. Available at: <https://www.ncbi.nlm.nih.gov/pubmed/11689577>.

172. Cunningham D, Lang I, Marcuello E, et al. Bevacizumab plus capecitabine versus capecitabine alone in elderly patients with previously untreated metastatic colorectal cancer (AVEX): an open-label, randomised

phase 3 trial. *Lancet Oncol* 2013;14:1077-1085. Available at: <https://www.ncbi.nlm.nih.gov/pubmed/24028813>.

173. Marabelle A, Le DT, Ascierto PA, et al. Efficacy of pembrolizumab in patients with noncolorectal high microsatellite instability/mismatch repair-deficient cancer: Results from the phase II KEYNOTE-158 study. *J Clin Oncol* 2020;38:1-10. Available at: <https://www.ncbi.nlm.nih.gov/pubmed/31682550>.

174. Lenz HJ, Van Cutsem E, Luisa Limon M, et al. First-line nivolumab plus low-dose ipilimumab for microsatellite instability-high/mismatch repair-deficient metastatic colorectal cancer: The phase II CheckMate 142 study. *J Clin Oncol* 2022;40:161-170. Available at: <https://www.ncbi.nlm.nih.gov/pubmed/34637336>.

175. Overman MJ, Lonardi S, Wong KYM, et al. Durable clinical benefit with nivolumab plus ipilimumab in DNA mismatch repair-deficient/microsatellite instability-high metastatic colorectal cancer. *J Clin Oncol* 2018;36:773-779. Available at: <https://www.ncbi.nlm.nih.gov/pubmed/29355075>.

176. Drilon A, Laetsch TW, Kummar S, et al. Efficacy of larotrectinib in TRK fusion-positive cancers in adults and children. *N Engl J Med* 2018;378:731-739. Available at: <https://www.ncbi.nlm.nih.gov/pubmed/29466156>.

177. Doebele RC, Drilon A, Paz-Ares L, et al. Entrectinib in patients with advanced or metastatic NTRK fusion-positive solid tumours: integrated analysis of three phase 1-2 trials. *Lancet Oncol* 2020;21:271-282. Available at: <https://www.ncbi.nlm.nih.gov/pubmed/31838007>.

178. Salama AKS, Li S, Macrae ER, et al. Dabrafenib and trametinib in patients with tumors with BRAF(V600E) mutations: results of the NCI-MATCH Trial Subprotocol H. *J Clin Oncol* 2020;38:3895-3904. Available at: <https://www.ncbi.nlm.nih.gov/pubmed/32758030>.

179. Subbiah V, Lassen U, Elez E, et al. Dabrafenib plus trametinib in patients with BRAF(V600E)-mutated biliary tract cancer (ROAR): a phase 2, open-label, single-arm, multicentre basket trial. *Lancet Oncol*



# NCCN Guidelines Version 2.2024

## Ampullary Adenocarcinoma

2020;21:1234-1243. Available at:

<https://www.ncbi.nlm.nih.gov/pubmed/32818466>.

180. Subbiah V, Wolf J, Konda B, et al. Tumour-agnostic efficacy and safety of selpercatinib in patients with RET fusion-positive solid tumours other than lung or thyroid tumours (LIBRETTO-001): a phase 1/2, open-label, basket trial. *Lancet Oncol* 2022;23:1261-1273. Available at:

<https://www.ncbi.nlm.nih.gov/pubmed/36108661>.

181. Chiorean EG, Von Hoff DD, Tabernero J, et al. Second-line therapy after nab-paclitaxel plus gemcitabine or after gemcitabine for patients with metastatic pancreatic cancer. *Br J Cancer* 2016;115:e13. Available at:

<https://www.ncbi.nlm.nih.gov/pubmed/27657342>.

182. Yoo C, Hwang JY, Kim JE, et al. A randomised phase II study of modified FOLFIRI.3 vs modified FOLFOX as second-line therapy in patients with gemcitabine-refractory advanced pancreatic cancer. *Br J Cancer* 2009;101:1658-1663. Available at:

<http://www.ncbi.nlm.nih.gov/pubmed/19826418>.

183. Tsavaris N, Kosmas C, Skopelitis H, et al. Second-line treatment with oxaliplatin, leucovorin and 5-fluorouracil in gemcitabine-pretreated advanced pancreatic cancer: A phase II study. *Invest New Drugs* 2005;23:369-375. Available at:

<https://www.ncbi.nlm.nih.gov/pubmed/16012797>.

184. Novarino A, Satolli MA, Chiappino I, et al. Oxaliplatin, 5-fluorouracil, and leucovorin as second-line treatment for advanced pancreatic cancer. *Am J Clin Oncol* 2009;32:44-48. Available at:

<https://www.ncbi.nlm.nih.gov/pubmed/19194124>.

185. Azmy A, Abdelwahab S, Yassen M. Oxaliplatin and bolus-modulated 5-fluorouracil as a second-line treatment for advanced pancreatic cancer: Can bolus regimens replace FOLFOX when considered for second line? *ISRN Oncol* 2013;2013:358538. Available at:

<https://www.ncbi.nlm.nih.gov/pubmed/23533808>.

186. Lamarca A, Palmer DH, Wasan HS, et al. Second-line FOLFOX chemotherapy versus active symptom control for advanced biliary tract

cancer (ABC-06): a phase 3, open-label, randomised, controlled trial. *Lancet Oncol* 2021;22:690-701. Available at:

<https://www.ncbi.nlm.nih.gov/pubmed/33798493>.

187. Wang-Gillam A, Li CP, Bodoky G, et al. Nanoliposomal irinotecan with fluorouracil and folinic acid in metastatic pancreatic cancer after previous gemcitabine-based therapy (NAPOLI-1): a global, randomised, open-label, phase 3 trial. *Lancet* 2016;387:545-557. Available at:

<https://www.ncbi.nlm.nih.gov/pubmed/26615328>.

188. Yoo C, Kim KP, Kim I, et al. Final results from the NIFTY trial, a phase IIb, randomized, open-label study of liposomal Irinotecan (nal-IRI) plus fluorouracil (5-FU)/leucovorin (LV) in patients (pts) with previously treated metastatic biliary tract cancer (BTC). *Ann Oncol* 2022;33:S565. Available at:

<https://doi.org/10.1016/j.annonc.2022.07.083>.

189. Vogel A, Wenzel P, Folprecht G, et al. Nal-IRI and 5-FU/LV compared to 5-FU/LV in patients with cholangio- and gallbladder carcinoma previously treated with gemcitabine-based therapies (NALIRICC – AIO-HEP-0116). *Ann Oncol* 2022;33:S563-S564. Available at:

<https://doi.org/10.1016/j.annonc.2022.07.081>.

190. Neuzillet C, Hentic O, Rousseau B, et al. FOLFIRI regimen in metastatic pancreatic adenocarcinoma resistant to gemcitabine and platinum-salts. *World J Gastroenterol* 2012;18:4533-4541. Available at:

<https://www.ncbi.nlm.nih.gov/pubmed/22969226>

<https://www.ncbi.nlm.nih.gov/pmc/articles/PMC3435778/pdf/WJG-18-4533.pdf>.

191. Zaniboni A, Aitini E, Barni S, et al. FOLFIRI as second-line chemotherapy for advanced pancreatic cancer: a GISCAD multicenter phase II study. *Cancer Chemother Pharmacol* 2012;69:1641-1645. Available at:

<https://www.ncbi.nlm.nih.gov/pubmed/22576338>

<https://link.springer.com/article/10.1007%2Fs00280-012-1875-1>.

192. Chiorean EG, Guthrie KA, Philip PA, et al. Randomized phase II study of PARP inhibitor ABT-888 (veliparib) with modified FOLFIRI versus



# NCCN Guidelines Version 2.2024

## Ampullary Adenocarcinoma

FOLFIRI as second-line treatment of metastatic pancreatic cancer: SWOG S1513. *Clin Cancer Res* 2021;27:6314-6322. Available at: <https://www.ncbi.nlm.nih.gov/pubmed/34580114>.

193. Mizrahi JD, Gunchick V, Mody K, et al. Multi-institutional retrospective analysis of FOLFIRI in patients with advanced biliary tract cancers. *World J Gastrointest Oncol* 2020;12:83-91. Available at: <https://www.ncbi.nlm.nih.gov/pubmed/31966916>.

194. Pelzer U, Schwaner I, Stieler J, et al. Best supportive care (BSC) versus oxaliplatin, folinic acid and 5-fluorouracil (OFF) plus BSC in patients for second-line advanced pancreatic cancer: a phase III-study from the German CONKO-study group. *Eur J Cancer* 2011;47:1676-1681. Available at: <http://www.ncbi.nlm.nih.gov/pubmed/21565490>.

195. Gill S, Ko YJ, Cripps C, et al. PANCREOX: A randomized phase III study of fluorouracil/leucovorin with or without oxaliplatin for second-line advanced pancreatic cancer in patients who have received gemcitabine-based chemotherapy. *J Clin Oncol* 2016;34:3914-3920. Available at: <https://www.ncbi.nlm.nih.gov/pubmed/27621395>.

196. Xiong HQ, Varadhachary GR, Blais JC, et al. Phase 2 trial of oxaliplatin plus capecitabine (XELOX) as second-line therapy for patients with advanced pancreatic cancer. *Cancer* 2008;113:2046-2052. Available at: <http://www.ncbi.nlm.nih.gov/pubmed/18756532>.

197. Boeck S, Vehling-Kaiser U, Waldschmidt D, et al. Erlotinib 150 mg daily plus chemotherapy in advanced pancreatic cancer: an interim safety analysis of a multicenter, randomized, cross-over phase III trial of the 'Arbeitsgemeinschaft Internistische Onkologie'. *Anticancer Drugs* 2010;21:94-100. Available at: <https://www.ncbi.nlm.nih.gov/pubmed/19770635>.

198. O'Reilly EM, Lee JW, Zalupski M, et al. Randomized, multicenter, phase II trial of gemcitabine and cisplatin with or without veliparib in patients with pancreas adenocarcinoma and a germline BRCA/PALB2 mutation. *J Clin Oncol* 2020;38:1378-1388. Available at: <https://www.ncbi.nlm.nih.gov/pubmed/31976786>.

199. Rothenberg ML, Oza AM, Bigelow RH, et al. Superiority of oxaliplatin and fluorouracil-leucovorin compared with either therapy alone in patients with progressive colorectal cancer after irinotecan and fluorouracil-leucovorin: interim results of a phase III trial. *J Clin Oncol* 2003;21:2059-2069. Available at: <https://www.ncbi.nlm.nih.gov/pubmed/12775730>.

200. Rougier P, Van Cutsem E, Bajetta E, et al. Randomised trial of irinotecan versus fluorouracil by continuous infusion after fluorouracil failure in patients with metastatic colorectal cancer. *Lancet* 1998;352:1407-1412. Available at: <https://www.ncbi.nlm.nih.gov/pubmed/9807986>.

201. Andre T, Louvet C, Maindrault-Goebel F, et al. CPT-11 (irinotecan) addition to bimonthly, high-dose leucovorin and bolus and continuous-infusion 5-fluorouracil (FOLFIRI) for pretreated metastatic colorectal cancer. *GERCOR*. *Eur J Cancer* 1999;35:1343-1347. Available at: <https://www.ncbi.nlm.nih.gov/pubmed/10658525>.

202. Berton D, Banerjee SN, Curigliano G, et al. Antitumor activity of dostarlimab in patients with mismatch repair-deficient/microsatellite instability-high tumors: A combined analysis of two cohorts in the GARNET study. *J Clin Oncol* 2021;39:2564-2564. Available at: [https://ascopubs.org/doi/abs/10.1200/JCO.2021.39.15\\_suppl.2564](https://ascopubs.org/doi/abs/10.1200/JCO.2021.39.15_suppl.2564).

203. Hainsworth JD, Meric-Bernstam F, Swanton C, et al. Targeted therapy for advanced solid tumors on the basis of molecular profiles: Results from MyPathway, an open-label, phase IIa multiple basket study. *J Clin Oncol* 2018;36:536-542. Available at: <https://www.ncbi.nlm.nih.gov/pubmed/29320312>.

204. Javle M, Borad MJ, Azad NS, et al. Pertuzumab and trastuzumab for HER2-positive, metastatic biliary tract cancer (MyPathway): a multicentre, open-label, phase 2a, multiple basket study. *Lancet Oncol* 2021;22:1290-1300. Available at: <https://www.ncbi.nlm.nih.gov/pubmed/34339623>.