



National Comprehensive  
Cancer Network®

NCCN Clinical Practice Guidelines in Oncology (NCCN Guidelines®)

# Squamous Cell Skin Cancer

Version 1.2024 — November 9, 2023

**NCCN.org**

NCCN Guidelines for Patients® available at [www.nccn.org/patients](http://www.nccn.org/patients)

**Continue**



**\*Chrysalyn D. Schmults, MD, MS/Chair**  $\omega$   $\neq$   $\uparrow$   
Dana-Farber/Brigham and Women's  
Cancer Center | Mass General Cancer Center

**Rachel Blitzblau, MD, PhD/Vice Chair**  $\S$   
Duke Cancer Institute

**Sumaira Z. Aasi, MD**  $\omega$   
Stanford Cancer Institute

**\*Murad Alam, MD, MBA, MSCI**  $\omega$   $\uparrow$   $\zeta$   
Robert H. Lurie Comprehensive Cancer  
Center of Northwestern University

**Arya Amini, MD**  $\S$   
City of Hope National Medical Center

**Kristin Bibee, MD, PhD**  $\omega$   
The Sidney Kimmel Comprehensive  
Cancer Center at Johns Hopkins

**Jeremy Bordeaux, MD, MPH**  $\omega$   
Case Comprehensive Cancer Center/  
University Hospitals Seidman Cancer Center  
and Cleveland Clinic Taussig Cancer Institute

**Pei-Ling Chen, MD, PhD**  $\neq$   
Moffitt Cancer Center

**Carlo M. Contreras, MD**  $\uparrow$   
The Ohio State University Comprehensive  
Cancer Center - James Cancer Hospital  
and Solove Research Institute

**Dominick DiMaio, MD**  $\neq$   
Fred & Pamela Buffett Cancer Center

**Jessica M. Donigan, MD**  $\omega$   $\uparrow$   
Huntsman Cancer Institute  
at the University of Utah

**Jeffrey M. Farma, MD**  $\uparrow$   
Fox Chase Cancer Center

**Karthik Ghosh, MD**  $\neq$   
Mayo Clinic Comprehensive Cancer Center

**Kelly Harms, MD, PhD**  $\omega$   
University of Michigan Rogel Cancer Center

**Alan L. Ho, MD, PhD**  $\dagger$   
Memorial Sloan Kettering Cancer Center

**John Nicholas Lukens, MD**  $\S$   
Abramson Cancer Center  
at the University of Pennsylvania

**Susan Manber**  $\neq$   
Publicis Health

**Lawrence Mark, MD, PhD**  $\omega$   
Indiana University Melvin and Bren Simon  
Comprehensive Cancer Center

**Theresa Medina, MD**  $\dagger$   
University of Colorado Cancer Center

**Kishwer S. Nehal, MD**  $\omega$   
Memorial Sloan Kettering Cancer Center

**Paul Nghiem, MD, PhD**  $\omega$   
Fred Hutchinson Cancer Center

**Kelly Olino, MD**  $\uparrow$   
Yale Cancer Center/Smilow Cancer Hospital

**Soo Park, MD**  $\dagger$   
UC San Diego Moores Cancer Center

**Tejesh Patel, MD**  $\omega$   
The University of Tennessee Health Science Center

**Igor Puzanov, MD, MSCI**  $\ddagger$   
Roswell Park Comprehensive Cancer Center

**Jason Rich, MD**  $\zeta$   
Siteman Cancer Center at Barnes-Jewish Hospital  
and Washington University School of Medicine

**Aleksandar Sekulic, MD, PhD**  $\omega$   
Mayo Clinic Comprehensive Cancer Center

**Ashok R. Shaha, MD**  $\uparrow$   
Memorial Sloan Kettering Cancer Center

**Divya Srivastava, MD**  $\omega$   
UT Southwestern Simmons  
Comprehensive Cancer Center

**Valencia Thomas, MD**  $\omega$   
The University of Texas  
MD Anderson Cancer Center

**Courtney Tomblinson, MD**  $\phi$   
Vanderbilt-Ingram Cancer Center

**Puja Venkat, MD**  $\S$   
UCLA Jonsson Comprehensive Cancer Center

**Yaohui Gloria Xu, MD, PhD**  $\omega$   $\ddagger$   
University of Wisconsin  
Carbone Cancer Center

**Siegrid Yu, MD**  $\omega$   
UCSF Helen Diller Family Comprehensive Cancer Center

**Mehran Yusuf, MD**  $\S$   
O'Neal Comprehensive Cancer Center at UAB

### **NCCN**

**Sara Espinosa, PhD**  
**Beth McCullough, RN, BS**

$\omega$ Dermatology	$\neq$ Pathology/ Dermatopathology
$\phi$ Diagnostic/Interventional radiology	$\neq$ Patient advocacy
$\ddagger$ Hematology/Hematology oncology	$\ddagger$ Reconstructive surgery
$\neq$ Internal medicine	$\S$ Radiotherapy/Radiation oncology
$\dagger$ Medical oncology	$\uparrow$ Surgery/Surgical oncology
$\zeta$ Otolaryngology	<b>*</b> Discussion Section Writing Committee



### [NCCN Squamous Cell Skin Cancer Panel Members](#) [Summary of the Guidelines Updates](#)

[Clinical Presentation, Workup, Diagnosis, and Risk Status \(SCC-1\)](#)  
[Treatment for Field Cancerization/Confluent Epidermal Dysplasia \(SCC-2\)](#)  
[Treatment for Low-Risk Cutaneous Squamous Cell Cancer \(CSCC\) \(SCC-3\)](#)  
[Treatment for High-Risk/Very-High-Risk CSCC Where Surgery or RT Has High Likelihood of Cure \(SCC-4\)](#)  
[Treatment for Very-high-risk CSCC With Significant Risk of Extensive Local Recurrence or Nodal Metastasis \(SCC-5\)](#)  
[Treatment for Locally Advanced \(laCSCC\) or Unresectable Disease \(SCC-6\)](#)  
[Clinical Staging, Preoperative Assessment, and Primary Treatment \(SCC-7\)](#)  
[Treatment for Regional Lymph Nodes \(SCC-8\)](#)  
[Follow-up \(SCC-9\)](#)

[Principles of Pathology \(SCC-A\)](#)  
[Stratification to Determine Treatment Options and Follow-up for Local CSCC Based on Risk Factors for Local Recurrence, Metastases, or Death from Disease \(SCC-B\)](#)  
[Identification and Management of Patients at High-Risk for Multiple Primary CSCCs \(SCC-C\)](#)  
[Principles of Treatment \(SCC-D\)](#)  
[Principles of Radiation Therapy \(SCC-E\)](#)  
[Principles of Systemic Therapy \(SCC-F\)](#)  
[Principles of PDEMA Technique \(SCC-G\)](#)  
[Principles of Cancer Risk Assessment and Counseling \(SCC-H\)](#)

### [Staging \(ST-1\)](#)

### [Abbreviations \(ABBR-1\)](#)

**Clinical Trials:** NCCN believes that the best management for any patient with cancer is in a clinical trial. Participation in clinical trials is especially encouraged.

Find an NCCN Member Institution:  
<https://www.nccn.org/home/member-institutions>.

**NCCN Categories of Evidence and Consensus:** All recommendations are category 2A unless otherwise indicated.

See [NCCN Categories of Evidence and Consensus](#).

**NCCN Categories of Preference:** All recommendations are considered appropriate.

See [NCCN Categories of Preference](#).

The NCCN Guidelines® are a statement of evidence and consensus of the authors regarding their views of currently accepted approaches to treatment. Any clinician seeking to apply or consult the NCCN Guidelines is expected to use independent medical judgment in the context of individual clinical circumstances to determine any patient's care or treatment. The National Comprehensive Cancer Network® (NCCN®) makes no representations or warranties of any kind regarding their content, use or application and disclaims any responsibility for their application or use in any way. The NCCN Guidelines are copyrighted by National Comprehensive Cancer Network®. All rights reserved. The NCCN Guidelines and the illustrations herein may not be reproduced in any form without the express written permission of NCCN. ©2023.



Terminologies in all NCCN Guidelines are being actively modified to advance the goals of equity, inclusion, and representation.

Updates in Version 1.2024 of the NCCN Guidelines for Squamous Cell Skin Cancer from Version 1.2023 include:

Global changes:

- Extracapsular extension (ECE) changed to extranodal extension (ENE).

#### [SCC-1](#)

- Preliminary Workup, third bullet revised: Imaging studies of area of interest as indicated for suspicion of *locally extensive or metastatic* disease.
- Risk Status, new options added:
  - ▶ Field Cancerization/Confluent Epidermal Dysplasia.
  - ▶ Locally Advanced (laCSCC) or Unresectable Disease.
- New header added on far right of page: Primary Treatment.
  - ▶ Following Field Cancerization/Confluent epidermal dysplasia, new link added: SCC-2.
  - ▶ Following Low-risk, link revised: ~~Primary Treatment (SCC-3)~~.
  - ▶ Following High-risk/Very-high risk, link revised: ~~Primary Treatment (SCC-4) and SCC-5~~.
  - ▶ Following Locally advanced (laCSCC) or Unresectable disease, new link added: SCC-6.
  - ▶ Following Clinically or radiographically concerning regional lymph nodes, link revised: ~~Clinical Staging and Preoperative Assessment (SCC-7)~~.
  - ▶ Following Distant metastatic disease, link revised: ~~Regional recurrence or distant metastases (SCC-9)~~.
- Footnotes revised:
  - ▶ Footnote c: Extensive disease includes deep involvement such as bone, named nerves, and deep soft tissue. If disease of named nerve(s) is suspected, MRI with *and without* contrast is preferred. . .
  - ▶ Footnote d: For rare cases that present with distant metastatic disease at diagnosis, treat ~~as-per~~ distant metastases pathway on SCC-9.
  - ▶ Footnote e: Imaging modality and targeted area should be at the discretion of the treating team based on the suspected extent of disease (ie, local, regional, metastatic). Histologic confirmation is ~~often~~ sufficient to diagnose local recurrence, but MRI *with and without* contrast can be considered to assess extent of local disease. . . (Also page SCC-9)
  - ▶ Footnote f: Including CSCC in situ (showing full-thickness epidermal atypia, ~~excluding actinic keratoses~~).
- New footnotes added:
  - ▶ Footnote g: Field cancerization defined as UV induced confluent dysplasia clinically manifested as diffuse actinic keratoses and superficial (in situ) SCC. Willenbrink TJ, et al. J Am Acad Dermatol 2020;83:709-717. (Also page SCC-2)
  - ▶ Footnote h: A cure is unlikely to result from surgery and/or RT or there are concerns of significant functional impairment. Multidisciplinary discussion and multimodality treatment (including neoadjuvant and adjuvant therapy) merits consideration.
- Footnote removed: For more information, see American Academy of Dermatology Association: <https://www.aad.org/public/diseases/skin-cancer/squamous-cell-carcinoma>.

#### [SCC-2](#)

- New page added for Field cancerization/Confluent epidermal dysplasia.

[Continued](#)

**UPDATES**



Updates in Version 1.2024 of the NCCN Guidelines for Squamous Cell Skin Cancer from Version 1.2023 include:

### [SCC-3](#)

- Primary Treatment, options revised: ~~Curettage and electrodessication (C&E) or shave excision~~, or *Shave removal (if tumor appears to extend beyond the dermis, surgical or shave excision should generally be performed rather than C&E or shave removal)*, or Standard excision with 4- to 6-mm clinical margins and postoperative margin assessment. Tissue rearrangement (eg, flap reconstruction, extensive undermining) should not be undertaken until clear margins are identified (second intention healing, linear repair, or skin graft are acceptable), or Mohs or other forms of peripheral and deep en face margin assessment (PDMEA), or Radiation therapy (RT) for ~~non-surgical candidates~~ *patients declining surgery*.
- New header added on right side of page: Additional Treatment.
- New footnote x added: Shave removal (shaving of epidermal or dermal lesion) is a sharp removal by transverse bowl-shaped slicing to remove epidermal and dermal lesions (without including fat) and does not require suture closure. Emmett AJ, et al. *Plast Reconstr Surg* 1987;80:47-54.
- Footnote bb revised: PDMEA ~~(via with permanent or frozen section)~~ *analysis or intraoperative frozen section analysis* is an alternative to Mohs. (Also pages SCC-4A, SCC-5A, and SCC-6A)

### [SCC-4](#)

- Significant changes to High-risk/very-high-risk CSCC *where surgery or RT has a high likelihood of cure*.
  - ▶ New header added to left side of page: Treatment Planning:
    - ◊ New option added: Consider SLNB in cases that are recurrent or with multiple high-risk features.
  - ▶ Primary Treatment, third option revised: For non-surgical *candidates, consider multidisciplinary consultation and discussion of definitive RT ± systemic therapy*. ~~Systemic therapy if curative RT not feasible~~.
  - ▶ New header added to right side of page: Additional Treatment:
    - ◊ Top of page following Positive margins, options revised: Multidisciplinary consultation to discuss options: Re-resect, if feasible *or RT ± systemic therapy or Systemic therapy if curative RT* ~~If surgery and/or RT are not feasible curative~~.
      - New link added to far right of page: laCSCC or Unresectable disease (SCC-6).

### [SCC-4A](#)

- Footnotes revised:
  - ▶ Footnote ee: For complicated cases, consider multidisciplinary consultation. ~~For locally advanced disease in which curative RT and curative surgery are not feasible, consider treatment with systemic therapy or clinical trial.~~ *Principles of Systemic Therapy (SCC-F)*.
  - ▶ Footnote ff: Discuss and consider SLNB prior to or at time of PDMEA for patients with very-high-risk CSCCs that are recurrent or have multiple risk factors placing them in the very-high-risk group and have normal exam of draining nodal basin (category 2B). ~~See Stratification to Determine Treatment Options and Follow-up for Local CSCC Based on Risk Factors for Local Recurrence, Metastases, or Death from Disease (SCC-B)~~. (Also page SCC-5A)
  - ▶ Footnote jj: For tumors being considered for sentinel lymph node biopsy (SLNB), delay reconstruction *if not able to close primarily with minimal undermining*. (Also pages SCC-5A and SCC-6A)
  - ▶ Footnote kk: ~~Due to the wide variability of clinical characteristics that may define a high-risk tumor, it is not feasible to recommend a defined margin for standard excision of high-risk CSCC. Keen awareness of the subclinical extension of CSCC is advised when selecting a treatment modality without complete margin assessment for a high-risk tumor. These~~ *Appropriate margins should be determined case by case may need to be modified based on tumor or and patient-specific factors*. (Also pages SCC-5A and SCC-6A)

[Continued](#)**UPDATES**



Updates in Version 1.2024 of the NCCN Guidelines for Squamous Cell Skin Cancer from Version 1.2023 include:

#### [SCC-4A](#) (continued)

- New footnote gg added: For positive SLNB: Recommend multidisciplinary discussion after obtaining radiologic staging of the neck, chest, abdomen, and pelvis if not yet completed. In the absence of metastatic disease, consider completion lymphadenectomy of the affected nodal basin. If surgery is not an option due to patient preference or poor performance status, then consider radiation therapy. Following neck dissection, refer to SCC-5 for additional recommendations. (Also page SCC-5A)
- Footnotes removed:
  - ▶ If patient is immunosuppressed, consider modification or reduction of immunosuppression as appropriate.
  - ▶ RT may be supplemented by systemic therapy in select patients. Principles of Systemic Therapy (SCC-F).

#### [SCC-5](#)

- New page added for Very-high-risk CSCC with significant risk of extensive local recurrence or nodal metastasis.

#### [SCC-6](#)

- New page for laCSCC or unresectable disease (A cure is unlikely to result from surgery and/or RT or there are concerns of significant functional impairment. Multidisciplinary discussion and multimodality treatment [including neoadjuvant and adjuvant therapy] merits consideration).

#### [SCC-7](#)

- Column following Positive, second bullet revised: Chest/~~abdominal/pelvic~~-*abdomen/pelvis* CT with contrast or *FDG*-PET/CT as clinically indicated to rule out distant disease.
- Footnote tt revised: MRI *with and without contrast* of the brain may be considered to rule out subclinical cortical involvement in cases with bone invasion.
- Footnote removed: Principles of Systemic Therapy (SCC-F).

#### [SCC-9](#)

- Local disease and Regional disease, Consider imaging, new sub-bullet added: If there is appreciable risk of subclinical local or nodal recurrence.
  - ▶ Following Follow-Up, new pathway added: Locally advanced recurrence.
    - ◊ Link to SCC-6 added to far right of page.

#### [SCC-A](#)

- Reference 1 revised: ~~Alam M, Armstrong A, Baum G~~ *Kim JYS, Kozlow JH, Mittal B, et al; Invited Reviewers; Work Group*. Guidelines of care for the management of cutaneous squamous cell carcinoma. *J Am Acad Dermatol* 2018;78:560-578.

#### [SCC-B 1 of 2](#)

- Treatment options, Very High Risk column: link to SCC-5 added.

[Continued](#)

**UPDATES**





Updates in Version 1.2024 of the NCCN Guidelines for Squamous Cell Skin Cancer from Version 1.2023 include:

### [SCC-C 2 of 2](#)

• Information removed, edited, and placed on new SCC-2 or SCC-F:

▶ Treatment of Precancers (Diffuse Actinic Keratoses, Field Cancerization, and CSCC Prophylaxis)

◊ Use of nicotinamide may be effective in reducing the development of CSCCs.

◊ Actinic keratoses should be treated at first development.

– Accepted treatment modalities include cryotherapy, topical 5-fluorouracil (5-FU) (preferred) with or without calcipotriol (calcipotriene), topical imiquimod, topical tirbanibulin, photodynamic therapy (eg, aminolevulinic acid [ALA], porfimer sodium), and C&E. For hyperkeratotic actinic keratoses, pretreatment with topical tazarotene, curettage, or topical keratolytics (topical urea, lactic acid, and salicylic acid) prior to above therapies may be considered.

– Other modalities that may be considered include topical diclofenac (category 2B), chemical peel (trichloroacetic acid), and ablative skin resurfacing (eg, laser, dermabrasion).

◊ Actinic keratoses that have an atypical clinical appearance or do not respond to appropriate therapy should be biopsied for histologic evaluation.

◊ Ablative laser vermilionectomy may be of value in the treatment of extensive actinic cheilitis.

▶ Prevention:

◊ New bullet added: Regular sunscreen use prevents CSCC long term.

◊ Second bullet revised: Use of oral retinoids (eg, acitretin, isotretinoin) ~~has been~~ is effective in reducing the development of ~~actinic keratoses and~~ CSCC in some patients who are high risk. Side effects of oral retinoids may be significant. Therapeutic effects disappear shortly after cessation of the drug. Oral retinoids are teratogenic and must be used with extreme caution in patients of childbearing potential. Topical retinoids have been shown not to reduce development of ~~actinic keratosis or~~ CSCC.

▶ Reference added: Green AC, Williams GM, Logan V, Strutton GM. Reduced melanoma after regular sunscreen use: randomized trial follow-up. *J Clin Oncol* 2011;29:257-263.

▶ Footnote removed: The longest duration of prophylaxis against SCC has been demonstrated with 5-FU plus calcipotriol.

▶ References removed:

◊ Cunningham TJ, Tabacchi M, Eliane JP, et al. Randomized trial of calcipotriol combined with 5-fluorouracil for skin cancer precursor immunotherapy. *J Clin Invest* 2017;127:106-116.

◊ Rosenberg AR, Tabacchi M, Ngo KH, et al. Skin cancer precursor immunotherapy for squamous cell carcinoma prevention. *JCI Insight* 2019;4:e125476.

◊ Jansen MHE, Kessels JPHM, Nelemans PJ, et al. Randomized trial of four treatment approaches for actinic keratosis. *N Engl J Med* 2019;380:935-946.

◊ Badri O, Schmults CD, Karia PS, Ruiz ES. Efficacy and cost analysis for acitretin for basal and squamous cell carcinoma prophylaxis in renal transplant recipients. *Dermatol Surg* 2021;47:125-126.

[Continued](#)

**UPDATES**



Updates in Version 1.2024 of the NCCN Guidelines for Squamous Cell Skin Cancer from Version 1.2023 include:

### [SCC-D](#)

- Second bullet revised: Surgical approaches often offer the most effective and efficient means for accomplishing cure, but considerations of function, cosmesis, and patient preference may lead to choosing RT/*topical therapy/systemic therapy* as primary treatment in order to achieve optimal overall results.
- Fourth bullet revised: ~~In patients with Epidermally limited CSCC may be treated with non-surgical options. in situ (Bowen disease), alternative therapies such as topical 5-FU, topical imiquimod, photodynamic therapy (eg, ALA, porfimer sodium), or vigorous cryotherapy may be considered although cure rates may be lower than with surgical treatment modalities. Focal squamous in situ arising within actinic keratosis is not appropriate for surgery and should be treated topically.~~

### [SCC-E 1 of 2](#)

- General Principles:
  - ▶ Fourth bullet revised: RT is contraindicated for genetic conditions predisposing to skin cancer (eg, basal cell nevus syndrome [*Gorlin syndrome*]) and relatively contraindicated for patients with connective tissue diseases (eg, scleroderma).
  - ▶ New bullet added: IGRT is considered best practice when treating with IMRT, proton beam radiotherapy, or 3-D conformal radiation. The use of IGRT for other types of radiotherapy to treat skin cancer should be left to the discretion of the treating physician.
- Regional Disease section in table, Lymph node regions, without lymph node dissection, option removed: Clinically negative, at risk.
  - ▶ RT dosing, option removed: 50 Gy over 5 to 7 weeks.

### [SCC-E 2 of 2](#)

- Footnote and Reference moved to this page.

### [SCC-F 1 of 4](#)

- New page added for Principles of Systemic Therapy for Field Cancerization/Confluent Epidermal Dysplasia.

### [SCC-F 2 of 4](#)

- ~~Local Disease (Including Multiple Primaries) Amenable to Curative Surgery Very-High-Risk Disease~~, bullet revised: ~~Systemic therapy is not recommended. Consider neoadjuvant cemiplimab-rwlc if the tumor has very rapid growth, in-transit metastasis, lymphovascular invasion, is borderline resectable, or surgery alone may not be curative or may result in significant functional limitation.~~
- ~~Primary and Recurrent Locally Advanced IaCSCC or Unresectable Disease in Non-Surgical Candidates~~:
  - ▶ First bullet revised: ~~For patients who have residual disease and further~~ *If surgery is not feasible, recommend RT, and multidisciplinary teams can consider concurrent systemic therapy in select cases (Table 2).*
  - ▶ Second bullet revised: ~~For patients who have complicated cases of locally advanced disease in which~~ *If curative surgery and curative RT are not feasible, recommend multidisciplinary consultation to consider systemic therapy alone (Table 3).*
- New Regional Disease:
  - ▶ Second bullet revised: ~~For patients with~~ *resected high-risk regional disease of head and neck, consider RT ± systemic therapy (Table 2).*
  - ▶ Third bullet revised: ~~For patients with~~ *unresectable, inoperable, or incompletely resected disease, multidisciplinary consultation is needed to consider:*
- Table 2:
  - ▶ Other Recommended Regimens:
    - ◇ Carboplatin ± paclitaxel moved to Other Recommended Regimens from Useful in Certain Circumstances.
    - ◇ EGFR inhibitors (eg, cetuximab) moved to Other Recommended Regimens from Useful in Certain Circumstances.

[Continued](#)**UPDATES**





Updates in Version 1.2024 of the NCCN Guidelines for Squamous Cell Skin Cancer from Version 1.2023 include:

### [SCC-F 2 of 4](#) (continued)

- Table 3:
  - ▶ Other Recommended Regimens:
    - ◊ First sub-bullet revised: Carboplatin + paclitaxel ± *cetuximab*.
    - ◊ EGFR inhibitors (eg, *cetuximab*) moved to Other Recommended Regimens from Useful in Certain Circumstances.
  - ▶ Useful in Certain Circumstances, regimen removed: Carboplatin.

### [SCC-F 3 of 4](#)

- New Footnote c added: A cure is unlikely to result from surgery and/or RT or there are concerns of significant functional impairment. Multidisciplinary discussion and multimodality treatment (including neoadjuvant and adjuvant therapy) merits consideration.
- Footnote removed: Cemiplimab-rwlc, in one study of 79 patients with CSCC, showed a 51% complete histologic response in the neoadjuvant setting. Therefore it may be considered in patients who are considered borderline resectable, unresectable, or for whom surgery may carry a high morbidity.

### [SCC-F 4 of 4](#)

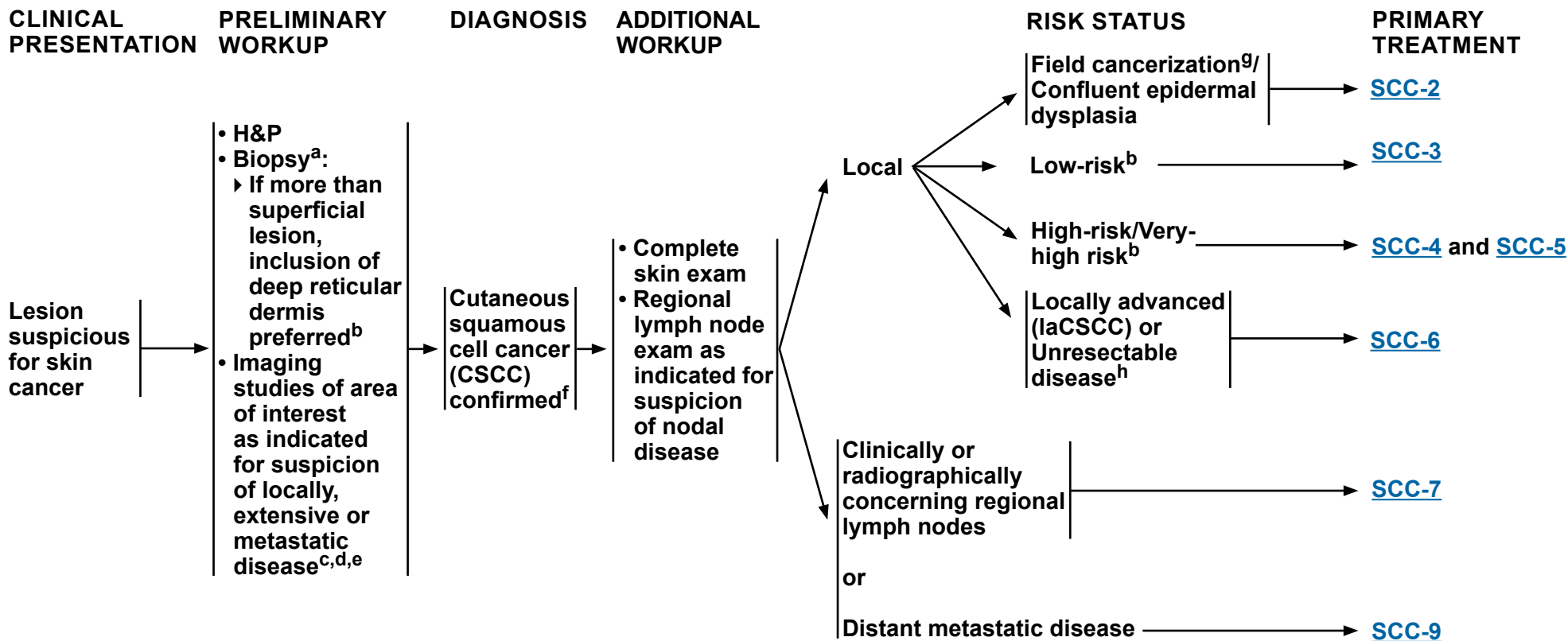
- References updated.

### [SCC-G 1 of 3](#)

- Reference 1 revised: ~~Gloster HM, Harris KR, Roenigk RK. A comparison between Mohs micrographic surgery and wide surgical excision for the treatment of dermatofibrosarcoma protuberans. J Am Acad Dermatol 1996;35:82-87. Fraga SD, Besaw RJ, Murad F, et al. Complete Margin Assessment Versus Sectional Assessment in Surgically Excised High-Risk Keratinocyte Carcinomas: A Systematic Review and Meta-Analysis. Dermatol Surg 2022;48:704-710.~~



# NCCN Guidelines Version 1.2024 Squamous Cell Skin Cancer



<sup>a</sup> [Principles of Pathology \(SCC-A\)](#).

<sup>b</sup> [Stratification to Determine Treatment Options and Follow-up for Local CSCC Based on Risk Factors for Local Recurrence, Metastases, or Death from Disease \(SCC-B\)](#) and [Identification and Management of Patients at High Risk for Multiple Primary CSCCs \(SCC-C\)](#).

<sup>c</sup> Extensive disease includes deep involvement such as bone, named nerves, and deep soft tissue. If disease of named nerve(s) is suspected, MRI with and without contrast is preferred. If bone disease is suspected, CT with contrast is preferred unless contraindicated.

<sup>d</sup> For rare cases that present with distant metastatic disease at diagnosis, treat per distant metastases pathway on [SCC-9](#).

<sup>e</sup> Imaging modality and targeted area should be at the discretion of the treating team based on the suspected extent of disease (ie, local, regional, metastatic). Histologic confirmation is sufficient to diagnose local recurrence, but MRI with and without contrast can be considered to assess extent of local disease. For nodal or distant metastases, histologic analysis and/or other imaging modalities can be used for confirmation and to gauge extent of disease.

<sup>f</sup> Including CSCC in situ (showing full-thickness epidermal atypia).

<sup>g</sup> Field cancerization defined as ultraviolet (UV) induced confluent dysplasia clinically manifested as diffuse actinic keratoses and superficial (in situ) SCC. Willenbrink TJ, et al. J Am Acad Dermatol 2020;83:709-717.


<sup>h</sup> A cure is unlikely to result from surgery and/or RT or there are concerns of significant functional impairment. Multidisciplinary discussion and multimodality treatment (including neoadjuvant and adjuvant therapy) merits consideration.

**Note: All recommendations are category 2A unless otherwise indicated.**

**Clinical Trials: NCCN believes that the best management of any patient with cancer is in a clinical trial. Participation in clinical trials is especially encouraged.**



Field cancerization<sup>9</sup>/  
Confluent epidermal  
dysplasia

**PRIMARY TREATMENT<sup>i,j,k,l</sup>**

- **Prevention<sup>m,n</sup>:**
  - ▶ **Daily sunscreen<sup>o</sup>**
  - ▶ **Nicotinamide<sup>p</sup>**
- **Accepted treatment modalities**
  - ▶ **Topical:**
    - ◇ **5-fluorouracil (5-FU)-based regimens are preferred**  
– Topical 5-FU ± calcipotriol (calcipotriene)<sup>q,r,s</sup>
  - ▶ **Destructive:**
    - ◇ **Ablative laser vermilionectomy (may be of value in the treatment of extensive actinic cheilitis)**
    - ◇ **Ablative skin resurfacing (eg, laser, dermabrasion)**
    - ◇ **Chemical peels (trichloroacetic acid)**
    - ◇ **Cryotherapy<sup>t</sup>**
    - ◇ **Curettage and electrodesiccation (C&E)**
  - ▶ **Other modalities that may be considered:**
    - ◇ **Photodynamic therapy (PDT) (eg, topical aminolevulinic acid [ALA], porfimer sodium)**
    - ◇ **Systemic retinoids (eg, acitretin,<sup>n</sup> isotretinoin)**
    - ◇ **Capecitabine<sup>l,u</sup> (for severe refractory disease that has progressed on oral retinoids)**

<sup>9</sup> Field cancerization defined as UV induced confluent dysplasia clinically manifested as diffuse actinic keratoses and superficial (in situ) SCC. Willenbrink TJ, et al. J Am Acad Dermatol 2020;83:709-717.

<sup>i</sup> [Principles of Systemic Therapy \(SCC-F 1 of 4\)](#).

<sup>j</sup> Actinic keratoses that have an atypical clinical appearance or do not respond to appropriate therapy should be biopsied for histologic evaluation.

<sup>k</sup> Actinic keratoses should be treated at first development.

<sup>l</sup> Cornejo CM, et al. J Am Acad Dermatol 2020;83:719-730.

<sup>m</sup> Use of oral retinoids (eg, acitretin, isotretinoin) is a therapeutic option used to reduce the development of actinic keratoses. Side effects of oral retinoids may be significant, especially in patients of childbearing potential, and therapeutic benefits are limited to the duration of the regimen. Topical retinoids were shown not to reduce development of actinic keratosis.

<sup>n</sup> Badri O, et al. Dermatol Surg 2021;47:125-126.

<sup>o</sup> Green AC, et al. J Clin Oncol 2011;29:257-263.

<sup>p</sup> Oral nicotinamide may be effective in reducing the development of CSCCs.

<sup>q</sup> The longest duration of prophylaxis against SCC has been demonstrated with topical 5-FU plus calcipotriol.

<sup>r</sup> Cunningham TJ, et al. J Clin Invest 2017;127:106-116.

<sup>s</sup> Jansen MHE, et al. N Engl J Med 2019;380:935-946.

<sup>t</sup> Afsar FS, et al. Postepy Dermatol Alergol 2015;32:88-93.

<sup>u</sup> Endrizzi B, et al. Dermatol Surg 2013;39:634-645.

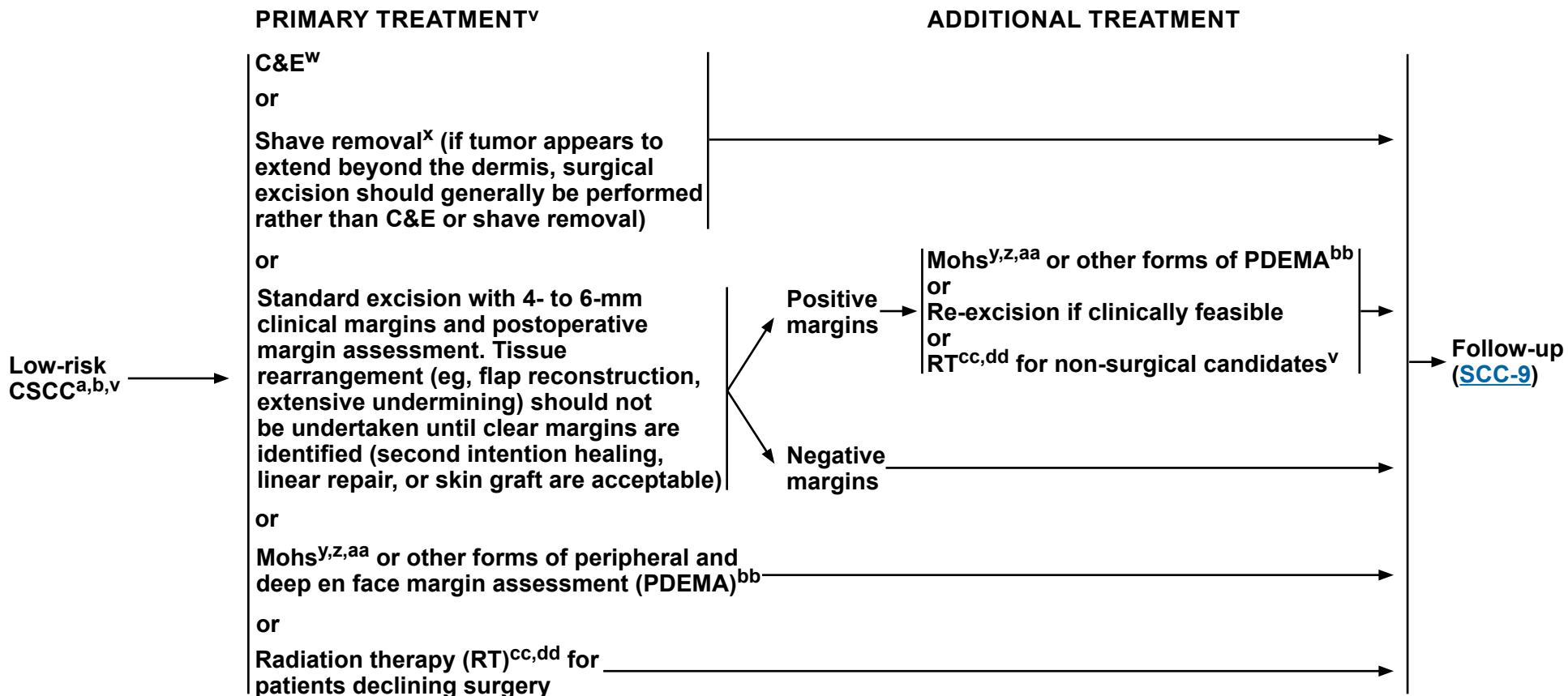
**Note: All recommendations are category 2A unless otherwise indicated.**

**Clinical Trials: NCCN believes that the best management of any patient with cancer is in a clinical trial. Participation in clinical trials is especially encouraged.**



# NCCN Guidelines Version 1.2024

## Squamous Cell Skin Cancer



<sup>a</sup> [Principles of Pathology \(SCC-A\)](#).

<sup>b</sup> [Stratification to Determine Treatment Options and Follow-up for Local CSCC Based on Risk Factors for Local Recurrence, Metastases, or Death from Disease \(SCC-B\)](#) and [Identification and Management of Patients at High Risk for Multiple Primary CSCCs \(SCC-C\)](#).

<sup>v</sup> [Principles of Treatment \(SCC-D\)](#).

<sup>w</sup> C&E may have a lower cure rate than excision.

<sup>x</sup> Shave removal (shaving of epidermal or dermal lesion) is a sharp removal by transverse bowl-shaped slicing to remove epidermal and dermal lesions (without including fat) and does not require suture closure. Emmett AJ, et al. *Plast Reconstr Surg* 1987;80:47-54.

<sup>y</sup> When Mohs is being performed and the preoperative biopsy is considered insufficient for providing all the staging information required to properly treat the tumor, submission of the central specimen for vertical paraffin-embedded permanent sections or documentation of staging parameters in Mohs report is recommended.

<sup>z</sup> As per other appropriate use Guidelines. Task Force/Committee Members, Vidal CI, Armbrecht EA, et al. *J Am Acad Dermatol* 2019;80:189-207.e11.

<sup>aa</sup> Mohs surgery should be performed by dermatologic surgeons who have specialized training and experience in this procedure.

<sup>bb</sup> PDEMA with permanent section analysis or intraoperative frozen section analysis is an alternative to Mohs. See [Principles of PDEMA Technique \(SCC-G\)](#).

<sup>cc</sup> [Principles of Radiation Therapy \(SCC-E\)](#).

<sup>dd</sup> Determination of the appropriateness of RT should be performed by a radiation oncologist.

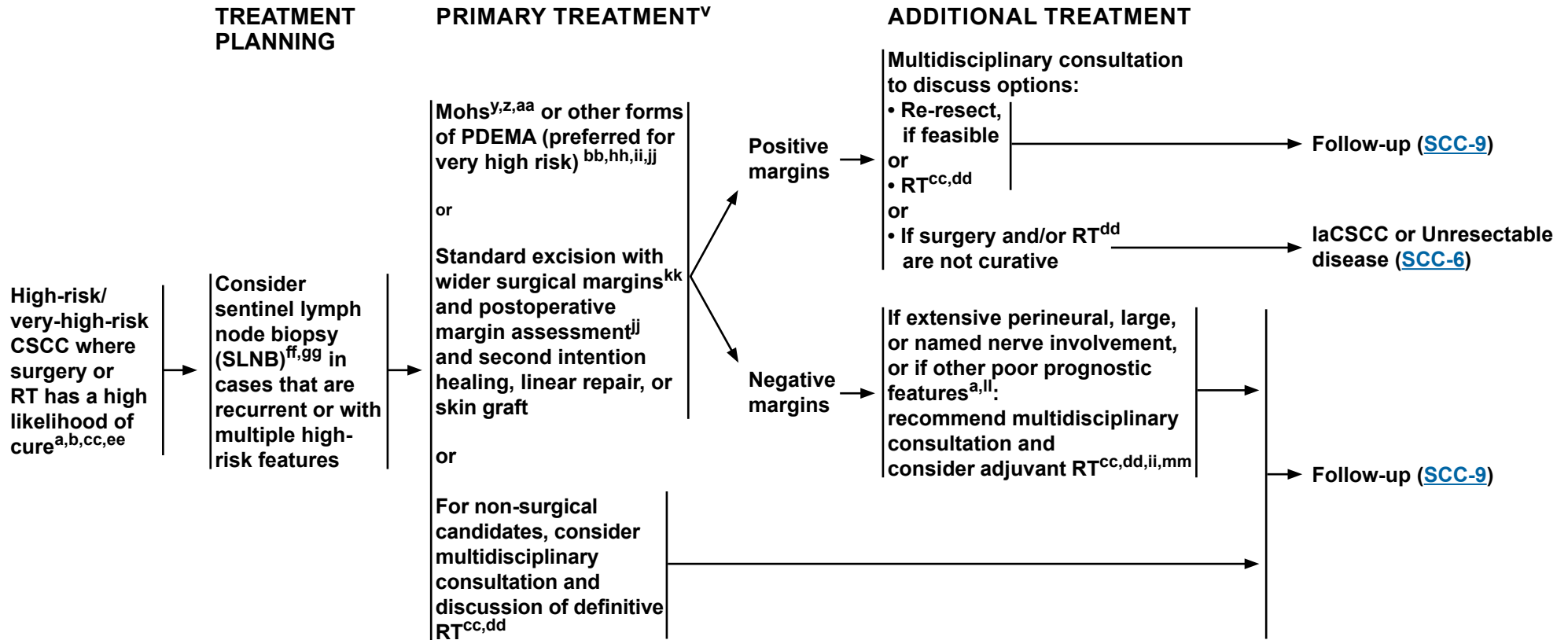
**Note: All recommendations are category 2A unless otherwise indicated.**

**Clinical Trials: NCCN believes that the best management of any patient with cancer is in a clinical trial. Participation in clinical trials is especially encouraged.**



# NCCN Guidelines Version 1.2024

## Squamous Cell Skin Cancer



[Footnotes on SCC-4A](#)

**Note:** All recommendations are category 2A unless otherwise indicated.  
**Clinical Trials:** NCCN believes that the best management of any patient with cancer is in a clinical trial. Participation in clinical trials is especially encouraged.

**FOOTNOTES**

<sup>a</sup> [Principles of Pathology \(SCC-A\)](#).

<sup>b</sup> [Stratification to Determine Treatment Options and Follow-up for Local CSCC Based on Risk Factors for Local Recurrence, Metastases, or Death from Disease \(SCC-B\)](#) and [Identification and Management of Patients at High Risk for Multiple Primary CSCCs \(SCC-C\)](#).

<sup>v</sup> [Principles of Treatment \(SCC-D\)](#).

<sup>y</sup> When Mohs is being performed and the preoperative biopsy is considered insufficient for providing all the staging information required to properly treat the tumor, submission of the central specimen for vertical paraffin-embedded permanent sections or documentation of staging parameters in Mohs report is recommended.

<sup>z</sup> As per other appropriate use Guidelines. Task Force/Committee Members, Vidal CI, Armbrect EA, et al. J Am Acad Dermatol 2019;80:189-207.e11.

<sup>aa</sup> Mohs surgery should be performed by dermatologic surgeons who have specialized training and experience in this procedure.

<sup>bb</sup> PDEMA with permanent section analysis or intraoperative frozen section analysis is an alternative to Mohs. See [Principles of PDEMA Technique \(SCC-G\)](#).

<sup>cc</sup> [Principles of Radiation Therapy \(SCC-E\)](#).

<sup>dd</sup> Determination of the appropriateness of RT should be performed by a radiation oncologist.

<sup>ee</sup> For complicated cases, consider multidisciplinary consultation.

<sup>ff</sup> Discuss and consider SLNB prior to or at time of PDEMA for patients with very-high-risk CSCCs that are recurrent or have multiple risk factors placing them in the very-high-risk group and have normal exam of draining nodal basin (category 2B).

<sup>gg</sup> For positive SLNB: Recommend multidisciplinary discussion after obtaining radiologic staging of the neck, chest, abdomen, and pelvis if not yet completed. In the absence of metastatic disease consider completion lymphadenectomy of the affected nodal basin. If surgery is not an option due to patient preference or poor performance status, then consider radiation therapy. Following neck dissection, refer to SCC-5 for additional recommendations.

<sup>hh</sup> In patients with very-high-risk CSCC and normal exam of nodal basin, discuss and consider radiologic imaging of nodal basin.

<sup>ii</sup> If invasion to parotid fascia, superficial parotidectomy may be indicated.

<sup>jj</sup> For tumors being considered for SLNB, delay reconstruction if not able to close primarily with minimal undermining.

<sup>kk</sup> Appropriate margins should be determined case by case based on tumor and patient-specific factors.

<sup>ll</sup> Large nerve involvement is defined by the American Joint Committee on Cancer (AJCC) Cancer Staging Manual, 8th Edition for CSCC of the head and neck as  $\geq 0.1$  mm or nerve involvement deeper than the dermis. Most nerves deep to the dermis are  $>0.1$  mm.

<sup>mm</sup> Adjuvant RT can be considered for CSCCs with gross clinical radiologic perineural invasion (PNI), multifocal histologic nerve invasion,  $\geq 6$  cm tumor diameter, recurrent tumors, high risk for regional or distant metastasis, close surgical margins where further surgery cannot be performed, and desmoplastic or infiltrative tumors in patients who are chronically immunosuppressed. Ruiz ES, et al. J Am Acad Dermatol 2022;87:87-94.

**Note: All recommendations are category 2A unless otherwise indicated.**

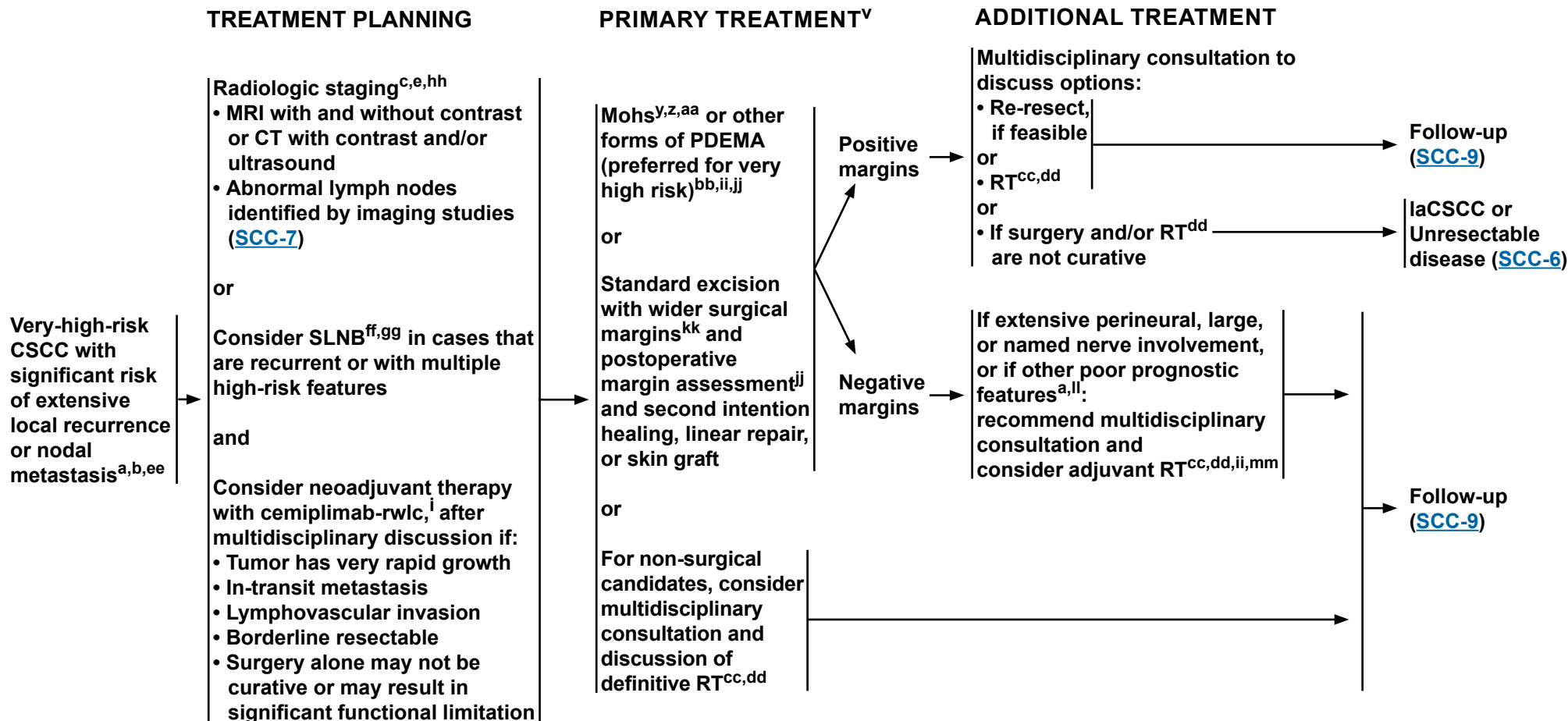
**Clinical Trials: NCCN believes that the best management of any patient with cancer is in a clinical trial. Participation in clinical trials is especially encouraged.**





# NCCN Guidelines Version 1.2024

## Squamous Cell Skin Cancer



[Footnotes on SCC-5A](#)

**Note:** All recommendations are category 2A unless otherwise indicated.  
**Clinical Trials:** NCCN believes that the best management of any patient with cancer is in a clinical trial. Participation in clinical trials is especially encouraged.

**FOOTNOTES**

<sup>a</sup> [Principles of Pathology \(SCC-A\)](#).

<sup>b</sup> [Stratification to Determine Treatment Options and Follow-up for Local CSCC Based on Risk Factors for Local Recurrence, Metastases, or Death from Disease \(SCC-B\)](#) and [Identification and Management of Patients at High Risk for Multiple Primary CSCCs \(SCC-C\)](#).

<sup>c</sup> Extensive disease includes deep involvement such as bone, named nerves, and deep soft tissue. If disease of named nerve(s) is suspected, MRI with and without contrast is preferred. If bone disease is suspected, CT with contrast is preferred unless contraindicated.

<sup>e</sup> Imaging modality and targeted area should be at the discretion of the treating team based on the suspected extent of disease (ie, local, regional, metastatic). Histologic confirmation is sufficient to diagnose local recurrence, but MRI with and without contrast can be considered to assess extent of local disease. For nodal or distant metastases, histologic analysis and/or other imaging modalities can be used for confirmation and to gauge extent of disease.

<sup>i</sup> [Principles of Systemic Therapy \(SCC-F 2 of 4\)](#).

<sup>v</sup> [Principles of Treatment \(SCC-D\)](#).

<sup>y</sup> When Mohs is being performed and the preoperative biopsy is considered insufficient for providing all the staging information required to properly treat the tumor, submission of the central specimen for vertical paraffin-embedded permanent sections or documentation of staging parameters in Mohs report is recommended.

<sup>z</sup> As per other appropriate use Guidelines. Task Force/Committee Members, Vidal CI, Armbrrect EA, et al. J Am Acad Dermatol 2019;80:189-207.e11.

<sup>aa</sup> Mohs surgery should be performed by dermatologic surgeons who have specialized training and experience in this procedure.

<sup>bb</sup> PDEMA with permanent section analysis or intraoperative frozen section analysis is an alternative to Mohs. See [Principles of PDEMA Technique \(SCC-G\)](#).

<sup>cc</sup> [Principles of Radiation Therapy \(SCC-E\)](#).

<sup>dd</sup> Determination of the appropriateness of RT should be performed by a radiation oncologist.

<sup>ee</sup> For complicated cases, consider multidisciplinary consultation.

<sup>ff</sup> Discuss and consider SLNB prior to or at time of PDEMA for patients with very-high-risk CSCCs that are recurrent or have multiple risk factors placing them in the very-high-risk group and have normal exam of draining nodal basin (category 2B).

<sup>gg</sup> For positive SLNB: Recommend multidisciplinary discussion after obtaining radiologic staging of the neck, chest, abdomen, and pelvis if not yet completed. In the absence of metastatic disease, consider completion lymphadenectomy of the affected nodal basin. If surgery is not an option due to patient preference or poor performance status, then consider radiation therapy. Following neck dissection, refer to [SCC-5](#) for additional recommendations.

<sup>hh</sup> In patients with very-high-risk CSCC and normal exam of nodal basin, discuss and consider radiologic imaging of nodal basin.

<sup>ii</sup> If invasion to parotid fascia, superficial parotidectomy may be indicated.

<sup>jj</sup> For tumors being considered for SLNB, delay reconstruction if not able to close primarily with minimal undermining.

<sup>kk</sup> Appropriate margins should be determined case by case based on tumor and patient-specific factors.

<sup>ll</sup> Large nerve involvement is defined by the AJCC Cancer Staging Manual, 8th Edition for CSCC of the head and neck as  $\geq 0.1$  mm or nerve involvement deeper than the dermis. Most nerves deep to the dermis are  $>0.1$  mm.

<sup>mm</sup> Adjuvant RT can be considered for CSCCs with gross clinical radiologic perineural invasion (PNI), multifocal histologic nerve invasion,  $\geq 6$  cm tumor diameter, recurrent tumors, high risk for regional or distant metastasis, close surgical margins where further surgery cannot be performed, and desmoplastic or infiltrative tumors in patients who are chronically immunosuppressed. Ruiz ES, et al. J Am Acad Dermatol 2022;87:87-94.

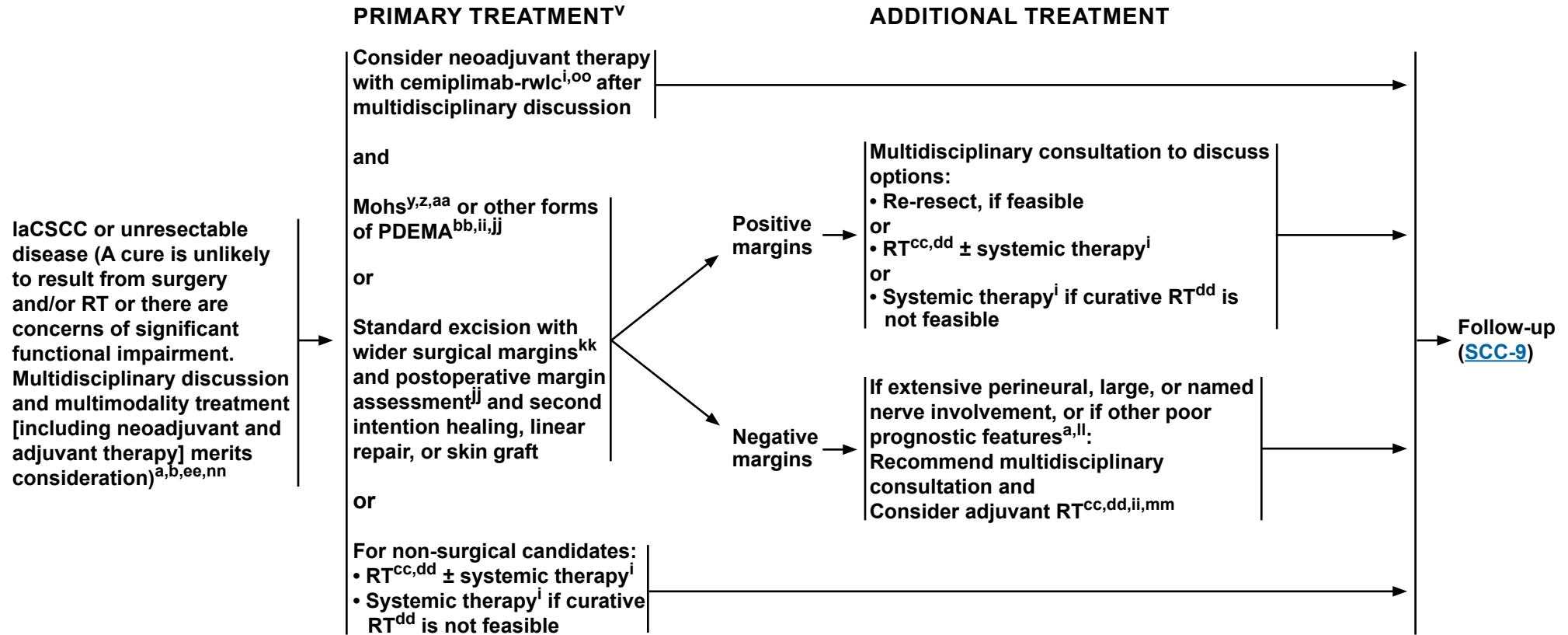
**Note: All recommendations are category 2A unless otherwise indicated.**

**Clinical Trials: NCCN believes that the best management of any patient with cancer is in a clinical trial. Participation in clinical trials is especially encouraged.**



# NCCN Guidelines Version 1.2024

## Squamous Cell Skin Cancer



[Footnotes on SCC-6A](#)

**Note:** All recommendations are category 2A unless otherwise indicated.  
**Clinical Trials:** NCCN believes that the best management of any patient with cancer is in a clinical trial. Participation in clinical trials is especially encouraged.

**FOOTNOTES**

<sup>a</sup> [Principles of Pathology \(SCC-A\)](#).

<sup>b</sup> [Stratification to Determine Treatment Options and Follow-up for Local CSCC Based on Risk Factors for Local Recurrence, Metastases, or Death from Disease \(SCC-B\)](#) and [Identification and Management of Patients at High Risk for Multiple Primary CSCCs \(SCC-C\)](#).

<sup>i</sup> [Principles of Systemic Therapy \(SCC-F 2 of 4\)](#).

<sup>v</sup> [Principles of Treatment \(SCC-D\)](#).

<sup>y</sup> When Mohs is being performed and the preoperative biopsy is considered insufficient for providing all the staging information required to properly treat the tumor, submission of the central specimen for vertical paraffin-embedded permanent sections or documentation of staging parameters in Mohs report is recommended.

<sup>z</sup> As per other appropriate use Guidelines. Task Force/Committee Members, Vidal CI, Ambrect EA, et al. J Am Acad Dermatol 2019;80:189-207.e11.

<sup>aa</sup> Mohs surgery should be performed by dermatologic surgeons who have specialized training and experience in this procedure.

<sup>bb</sup> PDEMA with permanent section analysis or intraoperative frozen section analysis is an alternative to Mohs. See [Principles of PDEMA Technique \(SCC-G\)](#).

<sup>cc</sup> [Principles of Radiation Therapy \(SCC-E\)](#).

<sup>dd</sup> Determination of the appropriateness of RT should be performed by a radiation oncologist.

<sup>ee</sup> For complicated cases, consider multidisciplinary consultation.

<sup>ii</sup> If invasion to parotid fascia, superficial parotidectomy may be indicated.

<sup>jj</sup> For tumors being considered for SLNB, delay reconstruction if not able to close primarily with minimal undermining.

<sup>kk</sup> Appropriate margins should be determined case by case based on tumor and patient-specific factors.

<sup>ll</sup> Large nerve involvement is defined by the AJCC Cancer Staging Manual, 8th Edition for CSCC of the head and neck as  $\geq 0.1$  mm or nerve involvement deeper than the dermis. Most nerves deep to the dermis are  $>0.1$  mm.

<sup>mm</sup> Adjuvant RT can be considered for CSCCs with gross clinical radiologic PNI, multifocal histologic nerve invasion,  $\geq 6$  cm tumor diameter, recurrent tumors, high risk for regional or distant metastasis, close surgical margins where further surgery cannot be performed, and desmoplastic or infiltrative tumors in patients who are chronically immunosuppressed. Ruiz ES, et al. J Am Acad Dermatol 2022;87:87-94.

<sup>nn</sup> If patient is immunosuppressed, consider modification or reduction of immunosuppression as appropriate.

<sup>oo</sup> Consider neoadjuvant therapy with cemiplimab-rwlc, after multidisciplinary discussion, if the tumor has very rapid growth, in-transit metastasis, lymphovascular invasion, is borderline resectable, or surgery alone may not be curative or may result in significant functional limitation.

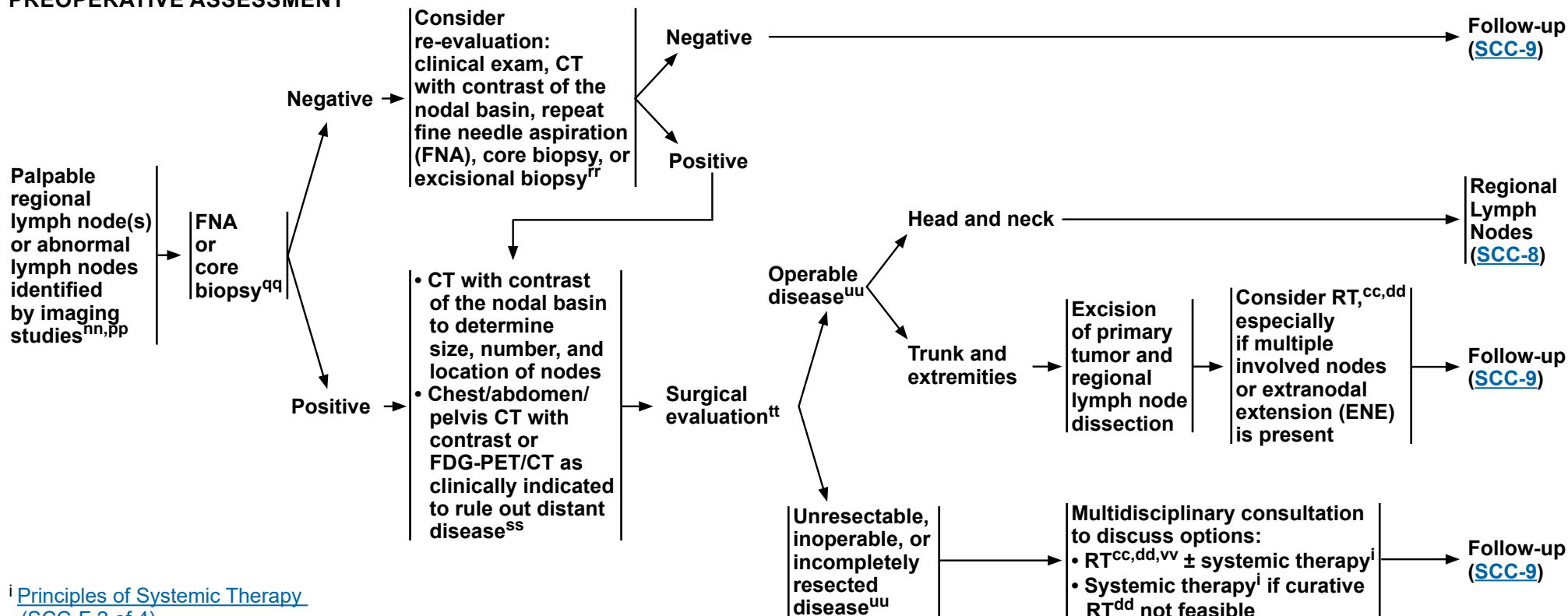
**Note: All recommendations are category 2A unless otherwise indicated.**

**Clinical Trials: NCCN believes that the best management of any patient with cancer is in a clinical trial. Participation in clinical trials is especially encouraged.**



# NCCN Guidelines Version 1.2024 Squamous Cell Skin Cancer

## CLINICAL STAGING AND PREOPERATIVE ASSESSMENT



<sup>i</sup> [Principles of Systemic Therapy \(SCC-F 2 of 4\)](#).

<sup>v</sup> [Principles of Treatment \(SCC-D\)](#).

<sup>cc</sup> [Principles of Radiation Therapy \(SCC-E\)](#).

<sup>dd</sup> Determination of the appropriateness of RT should be performed by a radiation oncologist.

<sup>nn</sup> If the patient is immunosuppressed, consider modification or reduction of immunosuppression as appropriate.

<sup>pp</sup> [Identification and Management of Patients at High Risk for Multiple Primary CSCCs \(SCC-C\)](#).

<sup>qq</sup> Ultrasound-guided biopsy by a center or physician with expertise is recommended. Core biopsy may be preferred over FNA in cases where primary tumor histology is uncertain or if a larger tissue sample is required for further genetic or other testing.

<sup>rr</sup> An excisional biopsy may be considered to confirm a negative initial FNA or core lymph node biopsy if clinical suspicion remains high.

<sup>ss</sup> MRI with and without contrast of the brain may be considered to rule out subclinical cortical involvement in cases with bone invasion.

<sup>tt</sup> Regional lymph node dissection is preferred unless the patient is not a surgical candidate.

<sup>uu</sup> Cemiplimab-rwlc, in one study of 79 patients with CSCC, showed a 51% complete histologic response in the neoadjuvant setting. Therefore it may be considered in patients who are considered borderline resectable, unresectable, or for whom surgery may carry a high morbidity.

<sup>vv</sup> Consider palliative RT/surgery for symptomatic sites. Stereotactic body RT (SBRT) may also be considered in select patients.

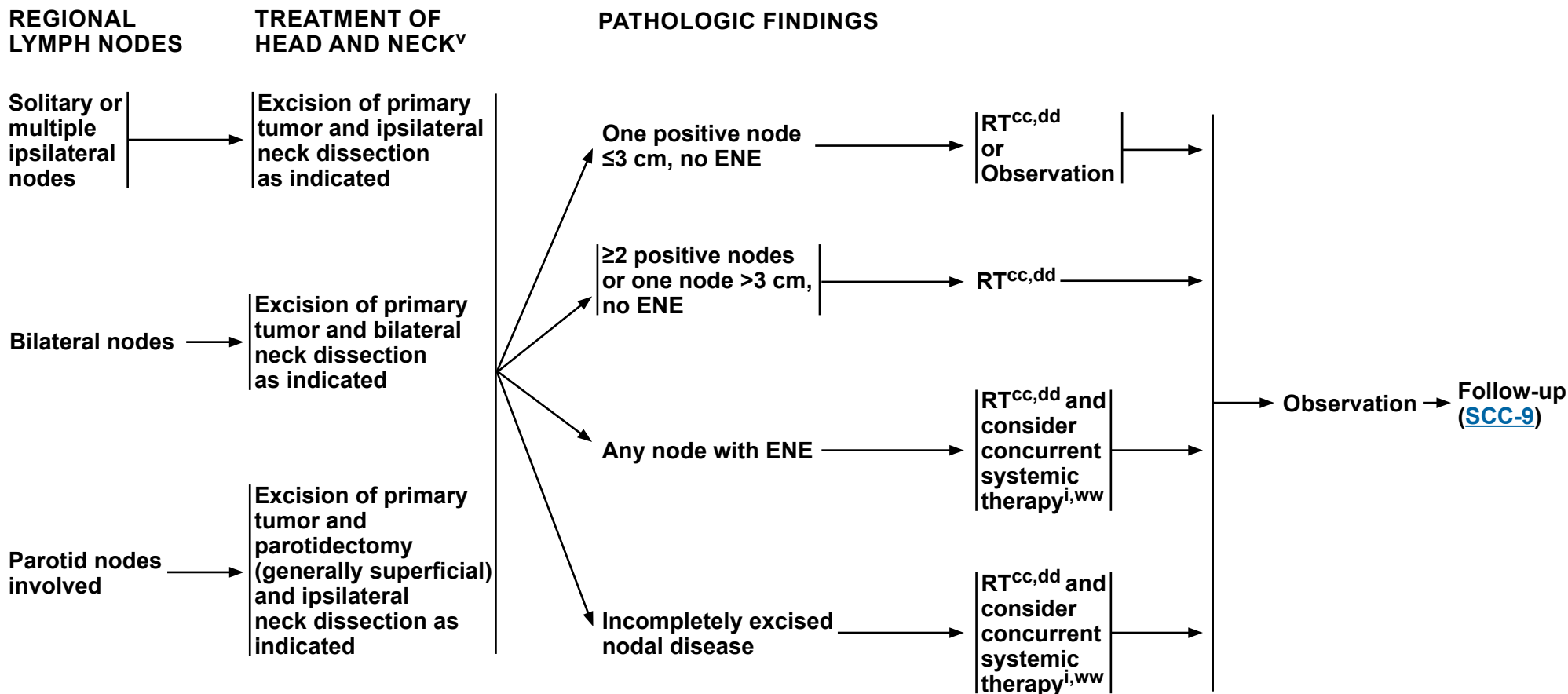
**Note:** All recommendations are category 2A unless otherwise indicated.

**Clinical Trials:** NCCN believes that the best management of any patient with cancer is in a clinical trial. Participation in clinical trials is especially encouraged.



# NCCN Guidelines Version 1.2024

## Squamous Cell Skin Cancer



<sup>i</sup> [Principles of Systemic Therapy \(SCC-F 2 of 4\)](#).

<sup>v</sup> [Principles of Treatment \(SCC-D\)](#).

<sup>cc</sup> [Principles of Radiation Therapy \(SCC-E\)](#).

<sup>dd</sup> Determination of the appropriateness of RT should be performed by a radiation oncologist.

<sup>ww</sup> Multidisciplinary consultation recommended.

**Note: All recommendations are category 2A unless otherwise indicated.**  
**Clinical Trials: NCCN believes that the best management of any patient with cancer is in a clinical trial. Participation in clinical trials is especially encouraged.**





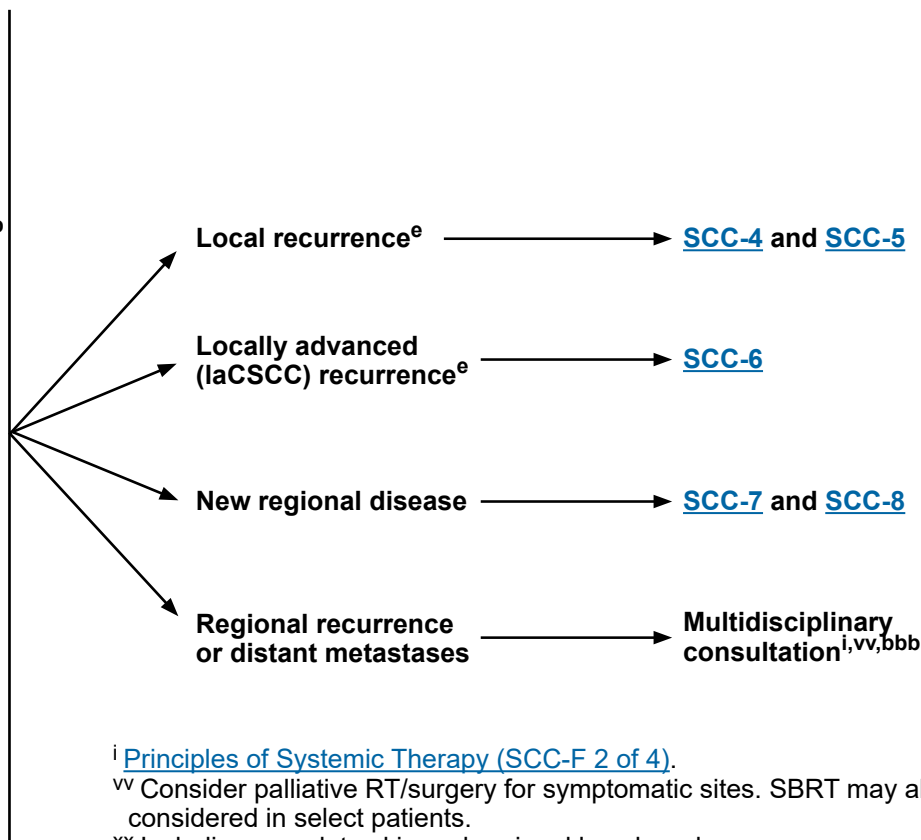
### FOLLOW-UP

#### Local disease:

- H&P<sup>xx,yy,zz</sup>
  - ▶ For patients who are low risk:  
Every 3–12 mo for 2 y, then every 6–12 mo for 3 y, then annually for life<sup>b</sup>
  - ▶ For patients who are high risk:  
Every 3–6 mo for 2 y, then every 6–12 mo for 3 y, then annually for life<sup>b</sup>
  - ▶ For patients who are very high risk:  
Every 3–6 mo for 2 y, then every 6 mo for 3 y, then every 6–12 mo for life<sup>b</sup>
- Consider imaging:
  - ▶ If clinical exam is insufficient for following disease
  - ▶ If there is appreciable risk of subclinical local or nodal recurrence<sup>e</sup>
- Patient education
  - ▶ Sun protection
  - ▶ Self examination of skin

#### Regional disease:

- H&P<sup>xx,yy,zz</sup>
  - ▶ Every 2–3 mo for 1 y,  
then every 2–4 mo for 1 y,  
then every 4–6 mo for 3 y,  
then every 6–12 mo for life
- Consider imaging:
  - ▶ If clinical exam is insufficient for following disease
  - ▶ If there is appreciable risk of subclinical local or nodal recurrence<sup>e,aaa</sup>
- Patient education
  - ▶ Sun protection
  - ▶ Self examination of skin  
and lymph nodes



<sup>b</sup> [Stratification to Determine Treatment Options and Follow-up for Local CSCC Based on Risk Factors for Local Recurrence, Metastases, or Death from Disease \(SCC-B\) and Identification and Management of Patients at High Risk for Multiple Primary CSCCs \(SCC-C\).](#)

<sup>e</sup> Imaging modality and targeted area should be at the discretion of the treating team based on the suspected extent of disease (ie, local, regional, metastatic). Histologic confirmation is sufficient to diagnose local recurrence, but MRI with and without contrast can be considered to assess extent of local disease. For nodal or distant metastases, histologic analysis and/or other imaging modalities can be used for confirmation and to gauge extent of disease.

<sup>i</sup> [Principles of Systemic Therapy \(SCC-F 2 of 4\).](#)

<sup>vv</sup> Consider palliative RT/surgery for symptomatic sites. SBRT may also be considered in select patients.

<sup>xx</sup> Including complete skin and regional lymph node exam.

<sup>yy</sup> Frequency of follow-up should be adjusted based on risk.

<sup>zz</sup> Follow-up with a dermatologist is strongly recommended if any of the following criteria are met: past or imminent solid organ, marrow, or stem cell transplant, one or more cutaneous melanomas in the past 5 years, or four or more non-melanoma skin cancers in the past 5 years.

<sup>aaa</sup> Surveillance imaging of regional nodal basin and to evaluate for distant metastatic disease, ideally based on multidisciplinary board recommendation, or as clinically indicated.

<sup>bbb</sup> Under highly selective circumstances, in the context of multidisciplinary consultation, resection of limited metastases can be considered.

**Note: All recommendations are category 2A unless otherwise indicated.**

**Clinical Trials: NCCN believes that the best management of any patient with cancer is in a clinical trial. Participation in clinical trials is especially encouraged.**

**PRINCIPLES OF PATHOLOGY****Principles of Biopsy Reporting**

- Pathologic evaluation of skin biopsies is ideally performed by a dermatologist, pathologist, or dermatopathologist experienced in interpreting cutaneous neoplasms. Reporting of margins and the elements below is not required for biopsy specimens.

**Principles of Excision Reporting (including Mohs excisions)**

- Specimens from intended complete surgical removal (eg, shave excisions) should be labeled as such so that margin status is reported.
- Since depth of invasion (in mm) may not be ascertained on tangentially cut Mohs specimens, anatomic level of invasion should be reported. Frozen or permanent section analysis of the clinical tumor specimen may be undertaken if needed for complete reporting of the features below to enable AJCC tumor staging.<sup>1,2</sup>
- Immunohistochemistry may be utilized as needed to help identify lymphovascular or nerve invasion, or to identify single tumor cells or small aggregates.

**Recommended Elements for Pathology Reporting of Excisional Specimens (including Mohs excisions)**

- **NOTE:** Tumors less than 2 cm in diameter without perineural invasion (as defined below) that are superficial (<6 mm in depth or confined to skin and fat) are AJCC T1 and do not require specific reporting of the histologic findings below with the exception of grade. However, reporting the presence of any of the prognostic features below is strongly encouraged.
- Elements reported (on requisition form) by the clinician submitting the tissue:
  - ▶ Anatomic location
  - ▶ Clinical pre-excision diameter in cm
  - ▶ Primary or recurrent tumor
  - ▶ Clinical or radiologic nerve invasion, including name of nerve
  - ▶ Other risk factors (optional) eg, immunosuppression, prior radiation at site
- Elements reported by the physician reporting the histologic findings:
  - ▶ Margin status (whether or not tumor is present at margins)
  - ▶ Well, moderate, or poor differentiation
  - ▶ Depth of invasion (either Breslow depth [in mm] measured from granular layer of adjacent normal epidermis to the base of the tumor OR tissue plane of deepest invasion eg, dermis, fat, fascia, muscle, perichondrium/periosteum, cartilage bone, other)
  - ▶ Perineural invasion defined as tumor cells within the nerve sheath of a nerve deep to dermis or with a caliber 0.1 mm or larger
  - ▶ Lymphovascular invasion
  - ▶ High-risk histology eg, desmoplasia, adenomatous, sarcomatous, or spindle cell
  - ▶ Low-risk histology (optional) eg, verrucous, keratoacanthomatous

<sup>1</sup> Kim JYS, Kozlow JH, Mittal B, et al; Invited Reviewers; Work Group. Guidelines of care for the management of cutaneous squamous cell carcinoma. J Am Acad Dermatol 2018;78:560-578.

<sup>2</sup> Califano JA, Lydiatt WM, Nehal KS, et al. Cutaneous squamous cell carcinoma of the head and neck. In: Amin MB, Edge S, Greene F, et al, eds. AJCC Cancer Staging Manual (Eighth Edition). New York: Springer International Publishing; 2017:171-181.

**Note:** All recommendations are category 2A unless otherwise indicated.

**Clinical Trials:** NCCN believes that the best management of any patient with cancer is in a clinical trial. Participation in clinical trials is especially encouraged.



# NCCN Guidelines Version 1.2024

## Squamous Cell Skin Cancer

### STRATIFICATION TO DETERMINE TREATMENT OPTIONS AND FOLLOW-UP FOR LOCAL CSCC BASED ON RISK FACTORS FOR LOCAL RECURRENCE, METASTASES, OR DEATH FROM DISEASE

Risk Group <sup>a</sup>	Low Risk	High Risk	Very High Risk
Treatment options	<a href="#">SCC-3</a>	<a href="#">SCC-4</a>	<a href="#">SCC-4</a> and <a href="#">SCC-5</a>
<b>H&amp;P</b>			
Location/size <sup>b</sup>	Trunk, extremities ≤2 cm	Trunk, extremities >2 cm – ≤4 cm Head, neck, hands, feet, pretibia, and anogenital (any size) <sup>e</sup>	>4 cm (any location)
Clinical extent	Well-defined	Poorly defined	
Primary vs. recurrent	Primary	Recurrent	
Immunosuppression	(-)	(+)	
Site of prior RT or chronic inflammatory process	(-)	(+)	
Rapidly growing tumor	(-)	(+)	
Neurologic symptoms	(-)	(+)	
<b>Pathology (<a href="#">SCC-A</a>)</b>			
Degree of differentiation	Well or moderately differentiated		Poor differentiation
Histologic features: Acantholytic (adenoid), adenosquamous (showing mucin production), or metaplastic (carcinosarcomatous) subtypes	(-)	(+)	Desmoplastic SCC
Depth <sup>c,d</sup> : Thickness or level of invasion	<2 mm thick and no invasion beyond subcutaneous fat	2–6 mm depth	>6 mm or invasion beyond subcutaneous fat
Perineural involvement	(-)	(+)	Tumor cells within the nerve sheath of a nerve lying deeper than the dermis or measuring ≥0.1 mm
Lymphatic or vascular involvement	(-)	(-)	(+)

[Footnotes on SCC-B \(2 of 2\)](#)

**Note:** All recommendations are category 2A unless otherwise indicated.  
**Clinical Trials:** NCCN believes that the best management of any patient with cancer is in a clinical trial. Participation in clinical trials is especially encouraged.



### FOOTNOTES

- <sup>a</sup> Risk category assignment should be based on the highest risk factor present. The high-risk group has elevated risk of local recurrence; the very-high-risk group has elevated risk of local recurrence and elevated risk of metastasis.
- <sup>b</sup> Preoperative clinical tumor diameter.
- <sup>c</sup> If clinical evaluation of incisional biopsy suggests that microstaging is inadequate, consider narrow margin excisional biopsy.
- <sup>d</sup> Deep invasion is defined as invasion beyond the subcutaneous fat OR >6 mm (as measured from the granular layer of adjacent normal epidermis to the base of the tumor, consistent with the AJCC Cancer Staging Manual, 8th Edition).
- <sup>e</sup> Location on the head, neck, hands, feet, pretibia, or anogenital area constitutes high risk based on location, independent of size. Narrow excision margins due to anatomic and functional constraints are associated with increased recurrence rates with standard histologic processing. Complete margin assessment such as with Mohs/PDEMA is recommended for optimal tumor clearance and maximal tissue conservation. For tumors <6 mm in size, without other high-risk or very-high-risk features, other treatment modalities may be considered if at least 4-mm clinically tumor-free margins can be obtained without significant anatomic or functional distortions.

**Note: All recommendations are category 2A unless otherwise indicated.**

**Clinical Trials: NCCN believes that the best management of any patient with cancer is in a clinical trial. Participation in clinical trials is especially encouraged.**



### IDENTIFICATION AND MANAGEMENT OF PATIENTS AT HIGH RISK FOR MULTIPLE PRIMARY CSCCs

#### Definition

- Certain patient groups are at high risk for developing multiple CSCCs and tumors that can behave aggressively. These include:
  - ▶ Organ transplant recipients
  - ▶ Other settings of immunosuppression (eg, lymphoma, chronic lymphocytic leukemia [CLL], drug-induced, HIV)
  - ▶ Genetic syndromes predisposing to CSCC formation<sup>a</sup>
- Within these high-risk groups, individual patients who are high risk should be identified for closer follow-up.
- Important individual risk factors include:
  - ▶ Total number of tumors
  - ▶ Frequency of development
  - ▶ Occurrence of aggressive tumors (eg, extension beyond cutaneous structures, perineural involvement, large and poorly differentiated, having ≥3 risk factors for recurrence) (See [Stratification to Determine Treatment Options and Follow-up for Local CSCC Based on Risk Factors for Local Recurrence, Metastases, or Death from Disease \[SCC-B\]](#)).

#### Diagnosis

- Skin lesions in these high-risk populations may be difficult to assess clinically. Therefore, a low threshold for performing skin biopsies of suspect lesions is necessary.
- In these patients, urgent diagnosis and treatment of lesions are important, and nodal staging (CT with contrast and/or ultrasound or pathologic evaluation) may be considered in those with significant risk of nodal metastases.

<sup>a</sup> Examples include xeroderma pigmentosum, generalized eruptive keratoacanthoma of Grzybowski, Rothmund-Thomson syndrome, dyskeratosis congenita, epidermodysplasia verruciformis, recessive dystrophic epidermolysis bullosa, severe generalized junctional epidermolysis bullosa, KID syndrome (keratitis, ichthyosis, deafness), and Ferguson-Smith disease.

**Note:** All recommendations are category 2A unless otherwise indicated.

**Clinical Trials:** NCCN believes that the best management of any patient with cancer is in a clinical trial. Participation in clinical trials is especially encouraged.

**IDENTIFICATION AND MANAGEMENT OF PATIENTS AT HIGH RISK FOR MULTIPLE PRIMARY CSCCs****Treatment of Skin Cancers**

- Because patients in high-risk groups may develop multiple lesions in short periods of time, destructive therapy (eg, C&E, cryotherapy) may be a preferred treatment for clinically low-risk tumors because of the ability to treat multiple lesions at a single patient visit. If C&E has been performed based solely on the clinical appearance of a low-risk tumor, the pathology from the biopsy taken at the time of C&E should be reviewed to make sure there are no high-risk pathologic features that would suggest the need for further therapy beyond C&E.
- In patients who develop multiple adjacent tumors in close proximity, surgical excision of invasive disease sometimes does not include surrounding in situ disease, and tissue rearrangement should be minimized. In situ disease may then be treated with topical approaches similar to actinic keratoses/field cancerization.
- Compared to the low-risk population, RT is used more frequently as an adjuvant therapy in patients who are high risk and for perineural disease.
- Satellite lesions and in-transit cutaneous metastases may occur more frequently in this population. They must be treated aggressively with multidisciplinary consultation.
- In organ transplant recipients and other patients undergoing immunosuppressive therapy, decreasing the level of immunosuppressive therapy and/or incorporating mTOR inhibitors may be considered in cases of life-threatening skin cancer or the rapid development of multiple tumors.

**Follow-Up**

- Follow-up schedules should be titrated to the frequency of tumor development.

**Patient Education**

- Individual risk assessment is necessary and should be discussed.
- Both extensive and repetitive patient education regarding sun avoidance and protection is required.
- Sun avoidance and protection methods must be stringent.
- Monthly self examination of all skin surfaces is recommended. If a patient has a history of invasive skin cancer, self examination of the lymph nodes should be taught and performed.
- Rapid entrance into the health care delivery system at the onset of tumor development is critical.
- Patient education should begin, in the case of recipients of organ transplant, at transplantation, and in the case of xeroderma pigmentosum, at birth or diagnosis.

**Prevention**

- Regular sunscreen use prevents CSCC long term.<sup>1</sup>
- Use of oral retinoids (eg, acitretin, isotretinoin) is effective in reducing the development of CSCC in some patients who are high risk. Side effects of oral retinoids may be significant. Therapeutic effects disappear shortly after cessation of the drug. Oral retinoids are teratogenic and must be used with extreme caution in patients of childbearing potential. Topical retinoids have been shown not to reduce development of CSCC. (See [SCC-2](#))
- Use of nicotinamide may be effective in reducing the development of CSCCs. Therapeutic effects disappear shortly after cessation of the drug.
- Aggressive treatment of precancers can prevent the development of subsequent invasive tumors.

<sup>1</sup> Green AC, Williams GM, Logan V, Strutton GM. Reduced melanoma after regular sunscreen use: randomized trial follow-up. J Clin Oncol 2011;29:257-263.

**Note:** All recommendations are category 2A unless otherwise indicated.

**Clinical Trials:** NCCN believes that the best management of any patient with cancer is in a clinical trial. Participation in clinical trials is especially encouraged.





### PRINCIPLES OF TREATMENT

- **The primary goals of treatment of CSCCs are the complete removal of the tumor and the maximal preservation of function and cosmesis. All treatment decisions should be customized to account for the particular factors present in the individual case and for the patient's preference.**
- **Surgical approaches often offer the most effective and efficient means for accomplishing cure, but considerations of function, cosmesis, and patient preference may lead to choosing RT/topical therapy/systemic therapy as primary treatment in order to achieve optimal overall results.**
- **In certain patients at high risk for multiple primary tumors, increased surveillance and consideration of prophylactic measures may be indicated. (See [Identification and Management of Patients at High Risk for Multiple Primary CSCCs \[SCC-C\]](#)).**
- **Epidermally limited CSCC may be treated with non-surgical options. (See [SCC-2](#) and [Principles of Systemic Therapy SCC-F](#)).**
- **When Mohs with margin assessment is being performed and the preoperative biopsy is considered insufficient for providing all the staging information required to properly treat the tumor, submission of the central specimen for vertical paraffin-embedded permanent sections or documentation of staging parameters in Mohs report is recommended.**

**Note: All recommendations are category 2A unless otherwise indicated.**

**Clinical Trials: NCCN believes that the best management of any patient with cancer is in a clinical trial. Participation in clinical trials is especially encouraged.**

### PRINCIPLES OF RADIATION THERAPY

#### General Principles<sup>a</sup>

- Protracted fractionation is associated with improved cosmetic results and should be utilized for poorly vascularized or cartilaginous areas.
- For extensive perineural invasion, clinically evident perineural involvement, or involvement of named nerves (particularly in the head and neck region), consider including the course of the local nerves proximally.
- In the setting of clinically evident PNI (or if grossly radiographically involved) for head and neck CSCCs, comprehensive coverage of involved cranial nerve pathways in addition to proximal local nerves should be considered.
- RT is contraindicated for genetic conditions predisposing to skin cancer (eg, basal cell nevus syndrome [Gorlin syndrome]) and relatively contraindicated for patients with connective tissue diseases (eg, scleroderma).
- Given higher complication rates, re-irradiation should not be routinely utilized for recurrent disease within a prior radiation field.
- Isotope-based brachytherapy can be an effective treatment for certain sites of disease, particularly on the head and neck.
- There are insufficient long-term efficacy and safety data to support the routine use of electronic surface brachytherapy.
- Image-guided radiation therapy (IGRT) is considered best practice when treating with intensity-modulated radiation therapy (IMRT), proton beam radiotherapy, or 3-D conformal radiation. The use of IGRT for other types of radiotherapy to treat skin cancer should be left to the discretion of the treating physician.

#### General Treatment Information

- Radiation treatments should be given by a practicing radiation oncologist with radiation physics support to meet established quality assurance and dosimetric constraints.

<u>Primary Tumor</u>	<u>RT Dosing</u>
Definitive RT	BED10 of 70–93 Gy for conventional fractionation BED10 of 56–88 Gy for hypofractionation
Postoperative Adjuvant RT <sup>1</sup>	BED10 of 60–79 Gy for conventional fractionation BED10 of 56–70 Gy for hypofractionation
<u>Regional Disease</u>	
<ul style="list-style-type: none"> <li>• Lymph node regions, after lymph node dissection                             <ul style="list-style-type: none"> <li>▶ Negative margins, no ENE</li> <li>▶ Positive margins or ENE</li> </ul> </li> </ul>	50–60 Gy over 5 to 6 weeks 60–66 Gy over 6 to 7 weeks
<ul style="list-style-type: none"> <li>• Lymph node regions, without lymph node dissection                             <ul style="list-style-type: none"> <li>▶ Clinically positive</li> </ul> </li> </ul>	60–70 Gy over 6 to 7 weeks
<ul style="list-style-type: none"> <li>• Clinically at-risk nerves</li> </ul>	50–60 Gy over 5 to 6 weeks

- BED = Biologically Effective Dose.
- Conventionally fractionated radiotherapy consists of five daily treatments per week.
- Hypofractionated radiotherapy consists of daily treatments or two to four treatments per week. Fraction sizes larger than 6 Gy are not routinely recommended outside of the palliative setting.

[Footnote and reference on SCC-E \(2 of 2\)](#)

Note: All recommendations are category 2A unless otherwise indicated.  
Clinical Trials: NCCN believes that the best management of any patient with cancer is in a clinical trial. Participation in clinical trials is especially encouraged.



### FOOTNOTE and REFERENCE

#### Footnote

<sup>a</sup> [ASTRO Guideline on Definitive and Postoperative Radiation Therapy for Basal and Squamous Cell Cancers of the Skin.](#)

#### Reference

<sup>1</sup> Porceddu SV, Daniels C, Yom SS, et al. Head and Neck Cancer International Group (HNCIG) Consensus Guidelines for the Delivery of Postoperative Radiation Therapy in Complex Cutaneous Squamous Cell Carcinoma of the Head and Neck (cSCCHN). *Int J Radiat Oncol Biol Phys* 2020;107:641-651.

**Note: All recommendations are category 2A unless otherwise indicated.**

**Clinical Trials: NCCN believes that the best management of any patient with cancer is in a clinical trial. Participation in clinical trials is especially encouraged.**

**PRINCIPLES OF SYSTEMIC THERAPY****Field Cancerization/Confluent Epidermal Dysplasia (SCC-2)<sup>1</sup>**

- Actinic keratoses should be treated at first development.
  - ▶ Accepted treatment modalities (in addition to [SCC-2](#)) include topical imiquimod and topical tirbanibulin. For hyperkeratotic actinic keratoses, pretreatment with topical tazarotene, curettage, or topical keratolytics (topical urea, lactic acid, and salicylic acid) prior to above therapies and select therapies listed in table 1 may be considered. Another modality that may be considered is topical diclofenac (category 2B).
- Actinic keratoses that have an atypical clinical appearance or do not respond to appropriate therapy should be biopsied for histologic evaluation.
- Use of oral retinoids (eg, acitretin, isotretinoin) is a therapeutic option used to reduce the development of actinic keratoses. Side effects of oral retinoids may be significant, especially in patients of childbearing potential, and therapeutic benefits are limited to the duration of the regimen. Topical retinoids were shown not to reduce development of actinic keratosis.
- In patients with CSCC in situ (Bowen disease), therapies such as topical 5-FU, topical imiquimod, and photodynamic therapy (eg, ALA, porfimer sodium) may be considered.<sup>a</sup>
- Vigorous cryotherapy<sup>2</sup> may be considered for discrete lesions (not field cancerization).
- Focal squamous in situ arising within actinic keratosis is not appropriate for surgery and should be treated topically.

**Table 1: Therapy Options for Field Cancerization/Confluent Epidermal Dysplasia**

Preferred Regimens	Other Recommended Regimens	Useful in Certain Circumstances
<ul style="list-style-type: none"> <li>• Topical 5-FU based regimens               <ul style="list-style-type: none"> <li>▶ Topical 5-FU ± calcipotriol (calcipotriene)<sup>b,3,4</sup></li> </ul> </li> </ul>	<ul style="list-style-type: none"> <li>• Topical aminolevulinic acid (in conjunction with PDT)</li> </ul>	<ul style="list-style-type: none"> <li>• Acitretin<sup>5</sup></li> <li>• Capecitabine<sup>1,6</sup> (for severe refractory disease that has progressed on oral retinoids)</li> <li>• Isotretinoin</li> <li>• Porfimer sodium (in conjunction with PDT)</li> </ul>

<sup>a</sup> Cure rates are approximately 10% lower than for surgical treatment modalities. Jansen MHE, et al. J Invest Dermatol 2018;138:527-533. Drew BA, et al. Dermatol Surg 2017;43:1423-1430.

<sup>b</sup> The longest duration of prophylaxis against SCC has been demonstrated with topical 5-FU plus calcipotriol.

[References on SCC-F \(4 of 4\)](#)

**Note: All recommendations are category 2A unless otherwise indicated.**

**Clinical Trials: NCCN believes that the best management of any patient with cancer is in a clinical trial. Participation in clinical trials is especially encouraged.**

### PRINCIPLES OF SYSTEMIC THERAPY

#### Very-High-Risk Disease (SCC-5)

- Consider neoadjuvant cemiplimab-rwlc if the tumor has very rapid growth, in-transit metastasis, lymphovascular invasion, is borderline resectable, or surgery alone may not be curative or may result in significant functional limitation.

#### Primary and Recurrent IaCSCC or Unresectable Disease<sup>c</sup> (SCC-6)

- If surgery is not feasible, recommend RT, and multidisciplinary teams can consider concurrent systemic therapy in select cases (Table 2).
- If curative surgery and curative RT<sup>d</sup> are not feasible, recommend multidisciplinary consultation to consider systemic therapy alone (Table 3).

#### New Regional Disease (SCC-7 and SCC-8)

- For most cases of fully resected regional disease, adjuvant systemic therapy is not recommended, unless within a clinical trial.
- For resected high-risk regional disease of head and neck, consider RT ± systemic therapy (Table 2).
- For unresectable, inoperable, or incompletely resected disease, multidisciplinary consultation is needed to consider:
  - RT ± systemic therapy (Table 2)
  - Systemic therapy alone if curative RT<sup>d</sup> is not feasible (Table 3).

#### Regional Recurrence or Distant Metastatic Disease (SCC-9)

- For regional recurrence or distant metastases, multidisciplinary team can consider systemic therapy alone (Table 3) or in combination with RT (Table 2).

**Table 2: Systemic Therapy Options for Use with RT**

Preferred Regimens	Other Recommended Regimens	Useful in Certain Circumstances
<ul style="list-style-type: none"> <li>Cisplatin<sup>e,7</sup></li> <li>Clinical trial</li> </ul>	<ul style="list-style-type: none"> <li>Carboplatin ± paclitaxel<sup>e,11,12</sup></li> <li>EGFR inhibitors (eg, cetuximab)<sup>e,13</sup></li> </ul>	<ul style="list-style-type: none"> <li>Cisplatin + 5-FU<sup>e,19</sup></li> </ul>

**Table 3: Options for Systemic Therapy Alone**

Preferred Regimens	Other Recommended Regimens	Useful in Certain Circumstances
<ul style="list-style-type: none"> <li>Cemiplimab-rwlc<sup>f,9</sup> (if curative RT<sup>d</sup> or surgery is not feasible for locally advanced, recurrent, or metastatic disease)<sup>8,9</sup></li> <li>Pembrolizumab<sup>f,9</sup> (if curative RT<sup>d</sup> or surgery is not feasible for locally advanced, recurrent, or metastatic disease)<sup>10</sup></li> <li>Clinical trial</li> </ul>	<ul style="list-style-type: none"> <li>If ineligible for or progressed on immune checkpoint inhibitors and clinical trials, consider:                             <ul style="list-style-type: none"> <li>Carboplatin + paclitaxel ± cetuximab<sup>14-18</sup></li> <li>EGFR inhibitors (eg, cetuximab)<sup>e,13</sup></li> </ul> </li> </ul>	<ul style="list-style-type: none"> <li>Neoadjuvant cemiplimab-rwlc<sup>9,8</sup></li> <li>If ineligible for or progressed on immune checkpoint inhibitors and clinical trials, consider:                             <ul style="list-style-type: none"> <li>Capecitabine<sup>20,21</sup></li> <li>Cisplatin<sup>e,7</sup></li> <li>Cisplatin + 5-FU<sup>e,19</sup></li> </ul> </li> </ul>

[Footnotes on SCC-F \(3 of 4\)](#)

[References on SCC-F \(4 of 4\)](#)

**Note:** All recommendations are category 2A unless otherwise indicated.  
**Clinical Trials:** NCCN believes that the best management of any patient with cancer is in a clinical trial. Participation in clinical trials is especially encouraged.



### FOOTNOTES

<sup>c</sup> A cure is unlikely to result from surgery and/or RT or there are concerns of significant functional impairment. Multidisciplinary discussion and multimodality treatment (including neoadjuvant and adjuvant therapy) merits consideration.

<sup>d</sup> Assessment of feasibility of RT should be made by a radiation oncologist.

<sup>e</sup> These options have occasionally produced useful responses, but data supporting efficacy are limited.

<sup>f</sup> Recent published phase II trial data support the efficacy and safety of cemiplimab-rwlc and pembrolizumab in patients with laCSCC, recurrent, and metastatic CSCC. Migden MR, Khushalani NI, Chang ALS, et al. Cemiplimab in locally advanced cutaneous squamous cell carcinoma: results from an open-label, phase 2, single-arm trial. *Lancet Oncol* 2020;21:294-305. Rischin D, Migden MR, Lim AM, et al. Phase 2 study of cemiplimab in patients with metastatic cutaneous squamous cell carcinoma: primary analysis of fixed-dosing, long-term outcome of weight-based dosing. *J Immunother Cancer* 2020;8:e000775. Hughes BGM, Munoz-Couselo E, Mortier L, et al. Pembrolizumab for locally advanced and recurrent/metastatic cutaneous squamous cell carcinoma (KEYNOTE-629 study): an open-label, nonrandomized, multicenter, phase II trial. *Ann Oncol* 2021;32:1276-1285.

<sup>g</sup> In solid organ transplant recipients, potential benefit from immune checkpoint inhibitor therapy has to be weighed against a significant risk of organ rejection. For patients receiving immunosuppressive therapy, in consultation with their treating physician, consider dose reduction of the immunosuppressive agent(s) and/or minimizing the doses of calcineurin inhibitors and/or antimetabolites in favor of mTOR inhibitors where appropriate. Patients with underlying immunodeficiencies, including CLL, were excluded from the phase I–II cemiplimab-rwlc trial, so the efficacy of cemiplimab-rwlc in this population is unclear.

**Note: All recommendations are category 2A unless otherwise indicated.**

**Clinical Trials: NCCN believes that the best management of any patient with cancer is in a clinical trial. Participation in clinical trials is especially encouraged.**



**REFERENCES**

- 1 Cornejo CM, Jambusaria-Pahlajani A, Willenbrink TJ, et al. Field cancerization: Treatment. *J Am Acad Dermatol* 2020;83:719-730.
- 2 Afsar FS, Erkan CD, Karaca S. Clinical practice trends in cryosurgery: a retrospective study of cutaneous lesions. *Postepy Dermatol Alergol* 2015;32:88-93.
- 3 Cunningham TJ, Tabacchi M, Eliane JP, et al. Randomized trial of calcipotriol combined with 5-fluorouracil for skin cancer precursor immunotherapy. *J Clin Invest* 2017;127:106-116.
- 4 Jansen MHE, Kessels JPHM, Nelemans PJ, et al. Randomized trial of four treatment approaches for actinic keratosis. *N Engl J Med* 2019;380:935-946.
- 5 Badri O, Schmults CD, Karia PS, Ruiz ES. Efficacy and cost analysis for acitretin for basal and squamous cell carcinoma prophylaxis in renal transplant recipients. *Dermatol Surg* 2021;47:125-126.
- 6 Endrizzi B, Ahmed RL, Ray T, et al. Capecitabine to reduce nonmelanoma skin carcinoma burden in solid organ transplant recipients. *Dermatol Surg* 2013;39:634-645.
- 7 Guthrie TH Jr, Porubsky ES, Luxenberg MN, et al. Cisplatin-based chemotherapy in advanced basal and squamous cell carcinomas of the skin: results in 28 patients including 13 patients receiving multimodality therapy. *J Clin Oncol* 1990;8:342-346.
- 8 Gross ND, Miller DM, Khushalani NI, et al. Neoadjuvant Cemiplimab for Stage II to IV Cutaneous Squamous-Cell Carcinoma. *N Engl J Med* 2022;387:1557-1568.
- 9 Rischin D, Migden MR, Lim AM, et al. Phase 2 study of cemiplimab in patients with metastatic cutaneous squamous cell carcinoma: primary analysis of fixed-dosing, long-term outcome of weight-based dosing. *J Immunother Cancer* 2020;8:e000775.
- 10 Hughes BGM, Munoz-Couselo E, Mortier L, et al. Pembrolizumab for locally advanced and recurrent/metastatic cutaneous squamous cell carcinoma (KEYNOTE-629 study): an open-label, nonrandomized, multicenter, phase II trial [published correction appears in *Ann Oncol* 2022 Aug;33:853]. *Ann Oncol* 2021;32:1276-1285.
- 11 Maring S, Elsayad K, Stenner M, et al. Efficacy of carboplatin/paclitaxel-based radiochemotherapy in locally advanced squamous cell carcinoma of head and neck. *Oncol Res Treat* 2018;41:736-743.
- 12 Vlacich G, Diaz R, Thorpe SW, et al. Intensity-modulated radiation therapy with concurrent carboplatin and paclitaxel for locally advanced head and neck cancer: toxicities and efficacy. *Oncologist* 2012;17:673-681.
- 13 Maubec E, Petrow P, Scheer-Senjarich I, et al. Phase II study of cetuximab as first-line single-drug therapy in patients with unresectable squamous cell carcinoma of the skin. *J Clin Oncol* 2011;29:3419-3426.
- 14 Ferrari D, Fiore J, Codecà C, et al. A phase II study of carboplatin and paclitaxel for recurrent or metastatic head and neck cancer. *Anticancer Drugs* 2009;20:185-190.
- 15 Carinato H, Burgy M, Ferry R, et al. Weekly Paclitaxel, Carboplatin, and Cetuximab as First-Line Treatment of Recurrent and/or Metastatic Head and Neck Squamous Cell Carcinoma for Patients Ineligible to Cisplatin-Based Chemotherapy: A Retrospective Monocentric Study in 60 Patients. *Front Oncol* 2021;11:714551.
- 16 Botticelli A, Pomati G, Cirillo A, et al. Weekly chemotherapy as first line treatment in frail head and neck cancer patients in the immunotherapy era. *J Transl Med* 2021;19:303.
- 17 Tahara M, Kiyota N, Yokota T, et al. Phase II trial of combination treatment with paclitaxel, carboplatin and cetuximab (PCE) as first-line treatment in patients with recurrent and/or metastatic squamous cell carcinoma of the head and neck (CSPOR-HN02). *Ann Oncol* 2018;29:1004-1009.
- 18 Geraghty L, Schultz TE, Hoffman SE, et al. Weekly vs. 3-weekly paclitaxel, carboplatin, and cetuximab (PCC) in recurrent/metastatic head and neck cancer. *Mol Clin Oncol* 2021;15:240.
- 19 Khansur T, Kennedy A. Cisplatin and 5-fluorouracil for advanced locoregional and metastatic squamous cell carcinoma of the skin. *Cancer* 1991;67:2030-2032.
- 20 Péron J, Poupard M, Ceruse P, et al. Efficacy and safety of capecitabine in heavily pretreated recurrent/metastatic head and neck squamous cell carcinoma. *Anticancer Drugs* 2012;23:1107-1111.
- 21 Martinez-Trufero J, Isla D, Adansa JC, et al. Phase II study of capecitabine as palliative treatment for patients with recurrent and metastatic squamous head and neck cancer after previous platinum-based treatment. *Br J Cancer* 2010;102:1687-1691.

**Note: All recommendations are category 2A unless otherwise indicated.****Clinical Trials: NCCN believes that the best management of any patient with cancer is in a clinical trial. Participation in clinical trials is especially encouraged.**



### PRINCIPLES OF PDEMA TECHNIQUE

- **PDEMA, also known as complete margin assessment, is a descriptive term for surgical techniques that allow high-quality histologic visualization and interpretation of the entire marginal surface of surgically excised tissue. The NCCN Guidelines Panel recognizes that a variety of surgical methods may achieve complete margin assessment. This NCCN appendix is intended to be inclusive of this diversity, while defining the features that are essential to the superior cure rates achieved by these techniques.<sup>1</sup>**
- **The most commonly used form of PDEMA is Mohs. When anatomic structures at the deep margin (eg, major vessels, nerves, bone) preclude complete histologic evaluation of the marginal surface via Mohs or other forms of PDEMA, Mohs or other forms of PDEMA should be used to evaluate as much of the marginal surface as feasible. Treatment considerations for non-visualized areas may be the subject of multidisciplinary discussion.**
- **A surgical procedure can be described as PDEMA if and only if all of the following criteria are met:**
  1. **The entire marginal surface of the surgical specimen is microscopically visualized and histopathologically analyzed for the presence of cancer. The marginal surface includes the complete deep and peripheral margin.**
  2. **The surgical specimen is oriented with respect to the surgical site and marked in a manner such that any positive margin identified in histopathologic analysis can be accurately located and re-excised.**
  3. **The surgical margin of any re-excised tissue is again entirely visualized and oriented as above. This process is repeated until no further cancer is identified at the surgical margin or until further excision is not anatomically possible or not in the best interest of the patient.**
  4. **The time interval between the steps of this process is rapid enough to prevent significant size or shape changes in the wound bed (ie, granulation, contraction) that would decrease the accuracy of orientation.**

<sup>1</sup> Fraga SD, Besaw RJ, Murad F, et al. Complete Margin Assessment Versus Sectional Assessment in Surgically Excised High-Risk Keratinocyte Carcinomas: A Systematic Review and Meta-Analysis. *Dermatol Surg* 2022;48:704-710.

**Note: All recommendations are category 2A unless otherwise indicated.**

**Clinical Trials: NCCN believes that the best management of any patient with cancer is in a clinical trial. Participation in clinical trials is especially encouraged.**

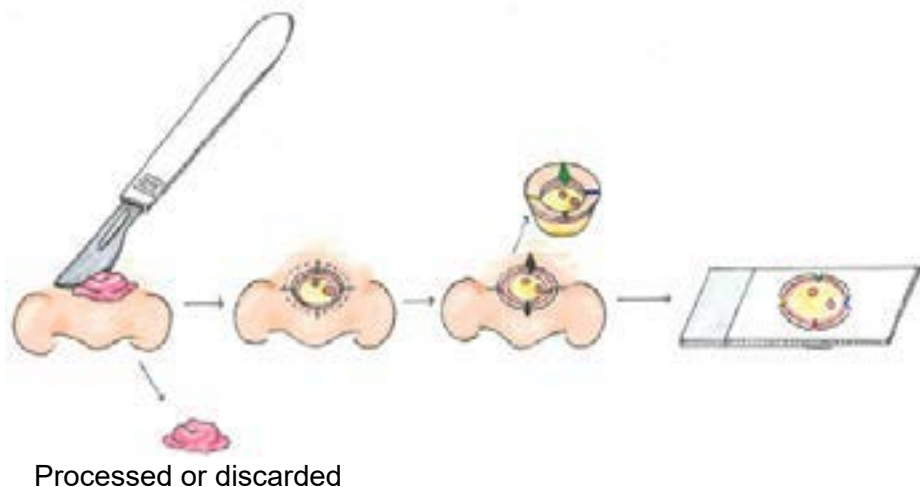
### PRINCIPLES OF PDEMA TECHNIQUE

- Visualization of the entire marginal surface of an irregular surgical specimen may be challenging, but is critical to the success of PDEMA methods. Typically, this visualization is achieved by flattening topographically complex surfaces onto a single plane and sectioning the specimen *parallel* to this plane (see Figure 1). Sampling methods such as perpendicular sectioning, also known as “breadloafing,” *do not* achieve direct visualization of the entire surgical margin and would prevent a procedure from achieving PDEMA.
- PDEMA can be achieved with either frozen sections or formalin fixation and paraffin embedding. Although it is often helpful for the surgeon to examine the specimen histologically, the surgeon is not required to examine the specimen histopathologically to achieve PDEMA; a trained pathologist or dermatopathologist may communicate results to the surgeon. If a pathologist or dermatopathologist analyzes the specimen, a consistent communication system must be in place to designate the marginal surfaces for examination and to ensure that the three-dimensional orientation of marginal surfaces and of tissue blocks relative to the wound bed are maintained and communicated to the surgeon to enable accurate localization of residual tumor within the wound bed. The use of multiple operating settings and surgeons is also consistent with PDEMA as long as the orientation of the tissue and wound bed are accurately communicated and complete margin assessment is maintained.<sup>2</sup>

Figure 1

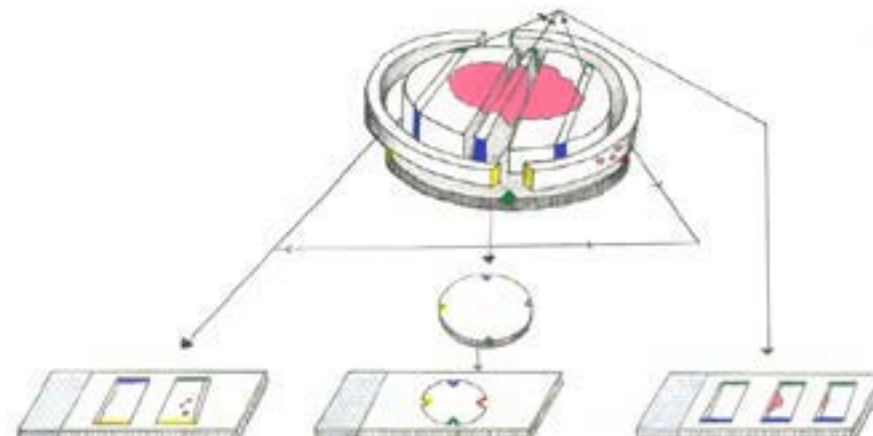
Courtesy of Dr. Brooke Walls, DO, FAAD, Aspen Center for Cosmetic Medicine & Dermatology

#### Tubingen muffin technique



OR

#### Tubingen torte technique



<sup>2</sup> Leigheb M, Zavattaro E, Bellinzona F, et al. Micrographic surgery (Tubingen torte technique) for the treatment of an invasive dermatofibrosarcoma protuberans with muscular involvement. *G Ital Dermatol Venereol* 2010;145:309-311.

**Note:** All recommendations are category 2A unless otherwise indicated.

**Clinical Trials:** NCCN believes that the best management of any patient with cancer is in a clinical trial. Participation in clinical trials is especially encouraged.

### PRINCIPLES OF PDEMA TECHNIQUE

- **Published examples of PDEMA include:**
  - ▶ Mohs<sup>3,4</sup>
  - ▶ Tubingen muffin technique<sup>5,6</sup>
  - ▶ Tubingen torte technique (see [https://ems-mohs.eu/fileadmin/user\\_upload/ESMS\\_Position\\_Paper\\_-\\_WEB.pdf](https://ems-mohs.eu/fileadmin/user_upload/ESMS_Position_Paper_-_WEB.pdf))
- **Examples of techniques that do not achieve PDEMA include:**
  - ▶ Wide local excision with “breadloafing” (perpendicular section prevents visualization of the entire margin)
  - ▶ Square procedure,<sup>7</sup> quadrant technique, moat technique, and perimeter technique<sup>8</sup> (wherein the deep margin is assessed with vertical sections so complete visualization of the deep margin is absent). As compared to “breadloafing,” these techniques provide more complete peripheral margin evaluation for superficial tumors (eg, melanoma in situ and extramammary Paget disease) that do not involve subcutaneous tissues. However, these techniques do not provide complete deep margin evaluation so are not PDEMA.

<b>PDEMA Checklist</b>	<b>Yes</b>	<b>No</b>
Is the entire peripheral margin of the surgical specimen microscopically visualized?		
Is the entire deep margin of the surgical specimen microscopically visualized?		
Is the surgical specimen oriented to the wound bed and marked such that any positive margin identified in histopathologic analysis can be accurately located and re-excised?		
Is the process of excision and complete histologic examination repeated until no further cancer is identified or until further excision is no longer in the best interest of the patient?		
Is the process rapid enough to prevent distortion of the wound bed that would decrease accuracy of tissue orientation?		

**All of the above categories must be marked Yes to achieve PDEMA. If any of the above are marked No, the procedure does not achieve PDEMA.**

<sup>3</sup> Tromovitch TA, Stegeman SJ. Microscopically controlled excision of skin tumors. Arch Dermatol 1974;110:231-232.

<sup>4</sup> Behshad R. Mohs Micrographic Surgery. In: Kantor J, ed. Dermatologic Surgery. McGraw-Hill Education; 2018:388-413.

<sup>5</sup> Möhrle M, Breuninger H. [The Muffin technique--an alternative to Mohs' micrographic surgery]. J Dtsch Dermatol Ges 2006;4:1080-1084.

<sup>6</sup> Farma JM, Ammori JB, Zager JS, et al. Dermatofibrosarcoma protuberans: How wide should we resect? Ann Surg Oncol 2010;17:2112-2118.

<sup>7</sup> Johnson TM, Headington JT, Baker SR, Lowe L. Usefulness of the staged excision for lentigo maligna and lentigo maligna melanoma: The “square” procedure. J Am Acad Dermatol 1997;37:758-764.

<sup>8</sup> Moehrle M, Breuninger H, Röcken M. A confusing world: what to call histology of three-dimensional tumour margins? J Eur Acad Dermatol Venereol 2007;21:591-595.

**Note: All recommendations are category 2A unless otherwise indicated.**

**Clinical Trials: NCCN believes that the best management of any patient with cancer is in a clinical trial. Participation in clinical trials is especially encouraged.**



### PRINCIPLES OF CANCER RISK ASSESSMENT AND COUNSELING

- The decision to offer genetic testing involves three related stages:
  - 1) Pre-test counseling prior to ordering testing;
  - 2) Consideration of the most appropriate testing strategy; and
  - 3) Testing result disclosure and post-test counseling.
- There are rare genetic syndromes that can markedly predispose patients to aggressive CSCC formations. These include xeroderma pigmentosum (XP) and recessive dystrophic epidermolysis bullosa (RDEB). Patients with these conditions should be referred to a cancer center with particular expertise in CSCC prevention and prophylaxis.
- It is recommended that a genetic counselor, medical geneticist, endocrinologist, oncologist, surgeon, oncology nurse, or other health professional with expertise and experience in cancer genetics be involved at each stage whenever possible. Clinicians without direct referral access to the appropriate expertise should be aware of the telehealth genetic counseling options available. These resources can be found through the National Society of Genetic Counselors (NSGC) “Find a Genetic Counselor” tool ([www.nsgc.org](http://www.nsgc.org)).

See the [NCCN Guidelines for Genetic/Familial High-Risk Assessment: Breast, Ovarian, and Pancreatic](#) for the following:

- Principles of Cancer Risk Assessment and Counseling (EVAL-A)
- Pedigree: First-, Second-, and Third-Degree Relatives of Proband (EVAL-B)

**Note:** All recommendations are category 2A unless otherwise indicated.

**Clinical Trials:** NCCN believes that the best management of any patient with cancer is in a clinical trial. Participation in clinical trials is especially encouraged.

**American Joint Committee on Cancer (AJCC)**  
**TNM Staging Classification for Cutaneous Carcinoma of the Head and Neck (8th ed., 2017)<sup>1,2</sup>****Table 1. Definitions for T, N, M**

<b>T</b>	<b>Primary Tumor</b>
<b>TX</b>	Primary tumor cannot be assessed
<b>Tis</b>	Carcinoma <i>in situ</i>
<b>T1</b>	Tumor smaller than or equal to 2 cm in greatest dimension
<b>T2</b>	Tumor larger than 2 cm, but smaller than or equal to 4 cm in greatest dimension
<b>T3</b>	Tumor larger than 4 cm in maximum dimension or minor bone erosion or perineural invasion or deep invasion*
<b>T4</b>	Tumor with gross cortical bone/marrow, skull base invasion and/or skull base foramen invasion
<b>T4a</b>	Tumor with gross cortical bone/marrow invasion
<b>T4b</b>	Tumor with skull base invasion and/or skull base foramen involvement

\*Deep invasion is defined as invasion beyond the subcutaneous fat or >6 mm (as measured from the granular layer of adjacent normal epidermis to the base of the tumor); perineural invasion for T3 classification is defined as tumor cells within the nerve sheath of a nerve lying deeper than the dermis or measuring 0.1 mm or larger in caliber, or presenting with clinical or radiographic involvement of named nerves without skull base invasion or transgression.

**Clinical N (cN)**

<b>cN</b>	<b>Regional Lymph Nodes</b>
<b>NX</b>	Regional lymph nodes cannot be assessed
<b>N0</b>	No regional lymph node metastasis
<b>N1</b>	Metastasis in a single ipsilateral lymph node, 3 cm or smaller in greatest dimension and ENE(-)
<b>N2</b>	Metastasis in a single ipsilateral node larger than 3 cm but not larger than 6 cm in greatest dimension and ENE(-); or metastases in multiple ipsilateral lymph nodes, none larger than 6 cm in greatest dimension and ENE(-); or in bilateral or contralateral lymph nodes, none larger than 6 cm in greatest dimension and ENE(-)
<b>N2a</b>	Metastasis in a single ipsilateral node larger than 3 cm but not larger than 6 cm in greatest dimension and ENE(-)
<b>N2b</b>	Metastases in multiple ipsilateral nodes, none larger than 6 cm in greatest dimension and ENE(-)
<b>N2c</b>	Metastases in bilateral or contralateral lymph nodes, none larger than 6 cm in greatest dimension and ENE(-)
<b>N3</b>	Metastasis in a lymph node larger than 6 cm in greatest dimension and ENE(-); or metastasis in any node(s) and clinically overt ENE [ENE(+)]
<b>N3a</b>	Metastasis in a lymph node larger than 6 cm in greatest dimension and ENE(-)
<b>N3b</b>	Metastasis in any node(s) and ENE (+)

Note: A designation of “U” or “L” may be used for any N category to indicate metastasis above the lower border of the cricoid (U) or below the lower border of the cricoid (L). Similarly, clinical and pathological extranodal extension (ENE) should be recorded as ENE(-) or ENE(+).

<sup>1</sup> These staging tables are for cutaneous squamous cell carcinoma, cutaneous carcinoma, basal cell carcinoma of the head and neck, and all other nonmelanoma skin carcinomas of the head and neck (except Merkel cell carcinoma). Anatomic site of external vermilion lip is included because it has a more similar embryologic origin to skin, and its etiology—which is often based on ultraviolet exposure—is more similar to other nonmelanoma skin cancers. The AJCC Staging Manual, Eighth Edition does not include staging for cutaneous carcinoma outside the head and neck.

<sup>2</sup> Used with the permission of the American College of Surgeons, Chicago, Illinois. The original source for this information is the AJCC Cancer Staging Manual, Eighth Edition (2017) published by Springer International Publishing.

**Continued**



**American Joint Committee on Cancer (AJCC)**  
**TNM Staging Classification for Cutaneous Carcinoma of the Head and Neck (8th ed., 2017)<sup>1,2</sup>****Pathological N (pN)****pN Regional Lymph Nodes****NX** Regional lymph nodes cannot be assessed**N0** No regional lymph node metastasis**N1** Metastasis in a single ipsilateral lymph node, 3 cm or smaller in greatest dimension and ENE(-)**N2** Metastasis in a single ipsilateral lymph node, 3 cm or smaller in greatest dimension and ENE(+);  
or larger than 3 cm but not larger than 6 cm in greatest dimension and ENE(-);  
or metastases in multiple ipsilateral lymph nodes, none larger than 6 cm in greatest dimension and ENE(-);  
or in bilateral or contralateral lymph node(s), none larger than 6 cm in greatest dimension, ENE(-)**N2a** Metastasis in single ipsilateral node 3 cm or smaller in greatest dimension and ENE(+);  
or a single ipsilateral node larger than 3 cm but not larger than 6 cm in greatest dimension and ENE(-)**N2b** Metastases in multiple ipsilateral nodes, none larger than 6 cm in greatest dimension and ENE(-)**N2c** Metastases in bilateral or contralateral lymph node(s), none larger than 6 cm in greatest dimension and ENE(-)**N3** Metastasis in a lymph node larger than 6 cm in greatest dimension and ENE(-);  
or in a single ipsilateral node larger than 3 cm in greatest dimension and ENE(+);  
or multiple ipsilateral, contralateral, or bilateral nodes, any with ENE(+);  
or a single contralateral node of any size and ENE(+)**N3a** Metastasis in a lymph node larger than 6 cm in greatest dimension and ENE(-)**N3b** Metastasis in a single ipsilateral node larger than 3 cm in greatest dimension and ENE(+);  
or multiple ipsilateral, contralateral, or bilateral nodes, any with ENE(+);  
or a single contralateral node of any size and ENE(+)

Note: A designation of “U” or “L” may be used for any N category to indicate metastasis above the lower border of the cricoid (U) or below the lower border of the cricoid (L). Similarly, clinical and pathological extranodal extension (ENE) should be recorded as ENE(-) or ENE(+).

**M Distant Metastasis****M0** No distant metastasis**M1** Distant metastasis**G Histologic Grade****GX** Grade cannot be assessed**G1** Well differentiated**G2** Moderately differentiated**G3** Poorly differentiated**G4** Undifferentiated**Table 2. AJCC Prognostic Stage Groups**

	<b>T</b>	<b>N</b>	<b>M</b>
<b>Stage 0</b>	Tis	N0	M0
<b>Stage I</b>	T1	N0	M0
<b>Stage II</b>	T2	N0	M0
<b>Stage III</b>	T3	N0	M0
	T1	N1	M0
	T2	N1	M0
	T3	N1	M0
<b>Stage IV</b>	T1	N2	M0
	T2	N2	M0
	T3	N2	M0
	Any T	N3	M0
	T4	Any N	M0
	Any T	Any N	M1

<sup>1</sup> These staging tables are for cutaneous squamous cell carcinoma, cutaneous carcinoma, basal cell carcinoma of the head and neck, and all other nonmelanoma skin carcinomas of the head and neck (except Merkel cell carcinoma). Anatomic site of external vermilion lip is included because it has a more similar embryologic origin to skin, and its etiology—which is often based on ultraviolet exposure—is more similar to other nonmelanoma skin cancers. The AJCC Staging Manual, Eighth Edition does not include staging for cutaneous carcinoma outside the head and neck.

<sup>2</sup> Used with the permission of the American College of Surgeons, Chicago, Illinois. The original source for this information is the AJCC Cancer Staging Manual, Eighth Edition (2017) published by Springer International Publishing.



### ABBREVIATIONS

<b>5-FU</b>	<b>5-fluorouracil</b>	<b>laCSCC</b>	<b>locally advanced cutaneous squamous cell carcinoma</b>
<b>ALA</b>	<b>aminolevulinic acid</b>	<b>NSGC</b>	<b>National Society of Genetic Counselors</b>
<b>BED</b>	<b>biologically effective dose</b>	<b>PDEMA</b>	<b>peripheral and deep en face margin assessment</b>
<b>C&amp;E</b>	<b>curettage and electrodesiccation</b>	<b>PDT</b>	<b>photodynamic therapy</b>
<b>CLL</b>	<b>chronic lymphocytic leukemia</b>	<b>PNI</b>	<b>perineural invasion</b>
<b>CSCC</b>	<b>cutaneous squamous cell carcinoma</b>	<b>RDEB</b>	<b>recessive dystrophic epidermolysis bullosa</b>
<b>ENE</b>	<b>extranodal extension</b>	<b>SBRT</b>	<b>stereotactic body radiation therapy</b>
<b>FDG</b>	<b>fluorodeoxyglucose</b>	<b>SLNB</b>	<b>sentinel lymph node biopsy</b>
<b>FNA</b>	<b>fine-needle aspiration</b>	<b>UV</b>	<b>ultraviolet</b>
<b>H&amp;P</b>	<b>history and physical</b>	<b>XP</b>	<b>xeroderma pigmentosum</b>
<b>IGRT</b>	<b>image-guided radiation therapy</b>		
<b>IMRT</b>	<b>intensity-modulated radiation therapy</b>		
<b>KID</b>	<b>keratitis, ichthyosis, deafness</b>		



NCCN Categories of Evidence and Consensus	
<b>Category 1</b>	Based upon high-level evidence, there is uniform NCCN consensus that the intervention is appropriate.
<b>Category 2A</b>	Based upon lower-level evidence, there is uniform NCCN consensus that the intervention is appropriate.
<b>Category 2B</b>	Based upon lower-level evidence, there is NCCN consensus that the intervention is appropriate.
<b>Category 3</b>	Based upon any level of evidence, there is major NCCN disagreement that the intervention is appropriate.

All recommendations are category 2A unless otherwise indicated.

NCCN Categories of Preference	
<b>Preferred intervention</b>	Interventions that are based on superior efficacy, safety, and evidence; and, when appropriate, affordability.
<b>Other recommended intervention</b>	Other interventions that may be somewhat less efficacious, more toxic, or based on less mature data; or significantly less affordable for similar outcomes.
<b>Useful in certain circumstances</b>	Other interventions that may be used for selected patient populations (defined with recommendation).

All recommendations are considered appropriate.



### Discussion

This discussion corresponds to the NCCN Guidelines for Squamous Cell Skin Cancer. Last updated April 25, 2022.

### Table of Contents

Overview.....	2
Literature Search Criteria and Guidelines Update Methodology.....	2
Risk Factors for SCC.....	2
Clinical Presentation and Workup.....	3
Risk Stratification of Local CSCC Based on Risk Factors for Local Recurrence, Metastases, or Death.....	3
History & Physical.....	3
Pathology.....	5
Treatment Modalities for Local SCC.....	6
Curettage and Electrodesiccation (C&E).....	6
Mohs Micrographic Surgery or Excision with Peripheral and Deep En Face Margin Assessment (PDEMA).....	7
Standard Excision with Postoperative Margin Assessment.....	8
Radiation Therapy.....	8
Sentinel Lymph Node Biopsy.....	10
Systemic Therapy for Local High-Risk SCC.....	10
Regional Lymph Node Involvement in SCC.....	11
Workup for Suspicion of Regional Lymph Node Involvement.....	11
Treatment of SCC with Regional Lymph Node Involvement.....	11
Systemic Therapy for Regional Disease.....	12
Recurrence and Metastasis.....	14
Systemic Therapy for Distant Metastatic Disease.....	14
Systemic Therapy Options.....	14
Follow-Up.....	16
Superficial Therapies for SCC <i>In Situ</i> .....	16
Care for Patients at High Risk of Developing Multiple SCCs.....	17
Treatment of Precancers in Patients at High-risk.....	17
Treatment of SCC in Patients at High-Risk.....	18
Prevention in Patients at High-Risk.....	18
Patient Education for Patients at High-Risk.....	19

References.....	21
-----------------	----



# NCCN Guidelines Version 1.2024

## Squamous Cell Skin Cancer

### Overview

Cutaneous squamous cell carcinoma (SCC or CSCC) is the second most common skin cancer.<sup>1-3</sup> Numerous population-based studies have demonstrated that the incidence of SCC is rising.<sup>1,4-8</sup> Some studies show that SCC incidence rates are rising more rapidly than basal cell carcinoma (BCC), reducing the difference in incidence between these two skin cancers.<sup>2,3,9</sup> Although rarely metastatic, SCC can produce substantial local destruction along with disfigurement and may involve extensive areas of soft tissue, cartilage, and bone. SCCs generally have a good prognosis, with 5-year survival of about 98%.<sup>1,10-12</sup>

### Literature Search Criteria and Guidelines Update Methodology

Prior to the update of this version of the NCCN Guidelines for Squamous Cell Skin Cancer, an electronic search of the PubMed database was performed to obtain key literature using the following search term: squamous cell carcinoma. The PubMed database was chosen as it remains the most widely used resource for medical literature and indexes peer-reviewed biomedical literature.<sup>13</sup>

The search results were narrowed by selecting studies in humans published in English. Results were confined to the following article types: Clinical Trial; Guideline; Meta-Analysis; Randomized Controlled Trial; Systematic Reviews; and Validation Studies.

The data from key PubMed articles as well as articles from additional sources deemed as relevant to these guidelines and discussed by the panel have been included in this version of the Discussion section (eg, e-publications ahead of print, meeting abstracts). Recommendations for which high-level evidence is lacking are based on the panel's review of lower-level evidence and expert opinion.

The complete details of the Development and Update of the NCCN Guidelines are available at [www.NCCN.org](http://www.NCCN.org).

### Risk Factors for SCC

A number of risk factors are associated with the development of SCC. The most recognized environmental carcinogen is sunlight. Evidence reveals that chronic sun exposure, total site-specific exposure, and number of site-specific sunburns are strongly correlated with development of SCC.<sup>14-18</sup> Due to the link with chronic and cumulative sun exposure, SCC rates are higher in occupations involving outdoor work<sup>19-21</sup> and increase with age, particularly in sun-exposed sites.<sup>2,5,9,16,17,22</sup> Indoor tanning is also significantly associated with SCC. According to two large meta-analyses, any exposure to indoor tanning increases the risk of SCC by 67%,<sup>23</sup> with the prevalence of indoor tanning much higher than previously thought among US adults and college students.<sup>24</sup> Individuals with light skin, hair, and eye color who have received too much sun exposure are at the greatest risk for SCC.<sup>14,15,25-29</sup> The incidence of ultraviolet (UV)-induced SCCs is very low in non-white populations and has been poorly quantified in people of mixed ethnicities. Most of SCCs develop on sun-exposed skin sites, especially the head and neck area.<sup>5,16,22,30,31</sup> Actinic keratoses (AKs) and Bowen's disease, if left untreated, can also progress to invasive SCC with the potential for metastasis.<sup>20,32-37</sup>

Furthermore, SCCs are also known to develop in association with scars or chronic wounds (Marjolin's ulcer).<sup>38-44</sup> These types of SCCs occur at similar rates in all races and ethnicities. Such SCC lesions tend to be difficult to treat and have higher risk of recurrence.<sup>45-47</sup>

Lastly, certain genetic syndromes greatly predispose affected individuals to SCC formation, such as albinism<sup>43,48-52</sup> and xeroderma pigmentosum.<sup>53-57</sup> Certain settings of immunosuppression (eg, organ transplantation, lymphoma, chronic lymphocytic leukemia, drug-induced





# NCCN Guidelines Version 1.2024

## Squamous Cell Skin Cancer

immunosuppression, and HIV) also predispose affected individuals to UV-induced SCC.<sup>58-72</sup> Most notably, analyses of transplant registries have reported a 5-fold to 113-fold increase in incidence of SCC in transplant recipients compared to the general population.<sup>60,61,68,72</sup> These patient groups are also at high risk of developing multiple CSCCs and tumors that can behave aggressively.<sup>45,53-57,73-86</sup> Within these high-risk groups, individual patients should be identified for closer follow-up (See *Identification and Management of Patients at High Risk for Multiple Primary CSCCs* in the Algorithm).

### Clinical Presentation and Workup

On clinical presentation of a suspicious lesion, workup for SCC begins with a history and physical examination, with an emphasis on a complete skin and regional lymph node (LN) examination. A full skin examination is recommended because individuals with a skin cancer often have additional, concurrent precancers or cancers located at other, usually sun-exposed skin sites. These individuals are also at increased risk of developing cutaneous melanoma.<sup>81,87,88</sup>

A skin biopsy is then performed on any suspicious lesion. The biopsy should include deep reticular dermis if the lesion is suspected to be more than a superficial process. This procedure is preferred because an infiltrative histology may sometimes be present only at the deeper, advancing margins of a tumor and superficial biopsies will frequently miss this component.<sup>89,90</sup> Skin lesions in high-risk populations may be difficult to assess clinically; therefore, a low threshold for performing skin biopsies in these patients is necessary. Basosquamous carcinoma may behave as aggressively as CSCC.<sup>91-93</sup>

Imaging studies of the area of interest should be done when extensive disease is suspected, which includes deep structural involvement such as bone, perineural disease, and deep soft tissue.<sup>94,95</sup> Due to its higher

sensitivity, MRI with contrast is preferred for perineural disease or deep soft tissue involvement.<sup>96-98</sup> If bone disease is suspected, CT with contrast is preferred unless contraindicated. Imaging modality and targeted area should be at the discretion of the treating team based on the suspected extent of disease (ie, local, regional, metastatic). Histologic confirmation is often sufficient to diagnose local recurrence, but MRI can be considered to assess extent of local disease. For nodal or distant metastases, histologic analysis and/or other imaging modalities can be employed for confirmation and to gauge extent of disease. For rare cases that present with distant metastatic disease at diagnosis, the distant metastases pathway should be followed. (see Guidelines sections *SCC-4 Clinical Staging and Preoperative Assessment* and *SCC-6 Regional Recurrence or Distant Metastases*).

### Risk Stratification of Local CSCC Based on Risk Factors for Local Recurrence, Metastases, or Death

After biopsy, a risk assessment of the primary tumor should be performed (See Stratification to Determine Treatment Options and Follow-up for Local CSCC Based on Risk Factors for Local Recurrence, Metastases, or Death from Disease in the algorithm). Risk category assignment should be based on the highest risk factor present. The high-risk group has elevated risk of local recurrence while the very-high-risk group has elevated risks of local recurrence and metastasis. Other staging systems, including the AJCC 8<sup>th</sup> edition staging system of CSCC, have been formulated and independently tested to define high-risk groups among patients with localized disease, and can act as additional sources of reference.<sup>10,73-75,81,99-105</sup>

### History & Physical

#### *Location and Size*

Anatomic location has been known to be a risk factor for SCC recurrence and metastasis for many years.<sup>45,74,106</sup> In general, SCCs that develop in





# NCCN Guidelines Version 1.2024

## Squamous Cell Skin Cancer

the head and neck area, particularly the ears and vermilion lips, are more likely to recur and metastasize than those developing on the trunk and extremities.<sup>10,45,73,74,99,106-109</sup> Besides the head and neck, SCCs that develop on the hands, feet, pretibial, and anogenital areas are also at greater risk of local recurrence and nodal metastasis, independent of size.<sup>10,110,111</sup>

Size has also been shown to be a risk factor for SCC recurrence and metastasis.<sup>45,74,109,112,113</sup> Although different divisions have been used, the most recent and robust data support that tumors >2 cm are at higher risk of recurrence, metastasis, and poor disease-specific survival (DSS).<sup>10,45-47,73-75,114,115</sup> Taken together, the NCCN Panel recommends that low-risk location (trunk, extremities) and size ≤ 2 cm constitute low-risk CSCC. Low-risk location (trunk, extremities) and size > 2 cm (but ≤ 4 cm), or high-risk locations outlined above, constitute high-risk CSCC.

Regardless of location, the NCCN Panel recommends that a tumor diameter of > 4 cm warrants the very-high risk designation. This is based on data from a large, prospective study, which demonstrate that lesion sizes of < 4 cm and ≥ 4 cm are associated with 3-year DSS of 93% and 67% (P = 0.0003), respectively.<sup>112</sup> Studies have also reported that mean lesion size of 4.2 cm (± 3.4)<sup>116</sup> and > 5 cm<sup>109</sup> as significantly associated with LN metastases.

### **Borders**

The risk factor of well-defined versus ill-defined clinical tumor borders has been reported in the context of BCC and extrapolated to the SCC population based on clinical experience of the NCCN panel.<sup>117-119</sup>

### **Primary Versus Recurrent Disease**

The higher risk of recurrence and metastasis for recurrent versus primary disease has been extensively documented in the literature.<sup>45,112,114,116,120,121</sup>

### **Immunosuppression**

In addition to increasing the risk of SCC development, immunosuppression has been shown to be associated with recurrence, metastasis, and death in multiple reports.<sup>45,73-75,78-81,122</sup> Studies from the organ transplant literature have further elucidated features linked with SCCs in this unique population of patients who are immunocompromised.<sup>79,101,123,124</sup> A retrospective review confirmed that organ transplant recipients with CSCC had more primary tumors and were more likely to have deep tissue spread and perineural and lymphatic invasion.<sup>79</sup> Other studies found diffuse/focal spindle cell morphology, evidence of human papillomavirus (HPV) infection, and aggressive subclinical extension to be more likely in SCCs from patients with transplants.<sup>123,125</sup> Two large retrospective studies reported high rates of SCC recurrence and metastasis among patients with transplants despite the fact that most SCCs were stage I/II at presentation.<sup>101,124</sup>

### **Site of Prior Radiotherapy or Chronic Inflammatory Process**

Tumors developing in sites of prior radiotherapy (RT) refer to primary CSCCs arising in areas previously irradiated for unrelated conditions. All recurrent tumors are defined as high risk irrespective of prior therapy. Data support that prior RT for unrelated (frequently benign) conditions is a risk factor for SCC recurrence or metastasis.<sup>114,126</sup> Retrospective studies and meta-analyses have also documented increased rates of metastasis for SCC arising from sites of chronic scarring or inflammation.<sup>45,46,116,120,127-129</sup>

### **Rapidly Growing Tumor**

The evidence for growth rate and prognosis is lacking in CSCC. Based on clinical experience, the NCCN Panel included rapid growth rate as a high-risk factor. A Japanese study reported a pair of tumor size and rapid growth as prognostic factor for SCC.<sup>130</sup> In a small retrospective series, tumor growth rate of > 4 mm/month exhibits a higher risk of nodal progression and a shorter progression time to LN metastasis.<sup>131</sup> There is



# NCCN Guidelines Version 1.2024

## Squamous Cell Skin Cancer

also evidence that CSCC in immunosuppressed individuals are often characterized by aggressive behavior and rapid growth.<sup>132,133</sup>

### **Neurologic Symptoms**

In tumors with perineural involvement (PNI), clinical symptoms suggesting possible involvement of sensory or motor nerves are commonly absent but may occur. Symptoms include pain, burning, stinging, anesthesia, paresthesia, facial paralysis, diplopia, and blurred vision.<sup>134,135</sup> Any suggestion of neurologic involvement in the region of a CSCC should place that tumor in a high-risk category, as PNI is associated with recurrence, metastasis, and poor outcomes.<sup>10,45,73,75,106,112,114,129,136-138</sup> Poorer outcomes are associated with the presence of clinical symptoms and extent of neuronal involvement.<sup>75,139-142</sup>

### **Pathology**

#### **Degree of Differentiation**

Although Broders originally divided CSCC histologically into four grades in 1920, the NCCN Panel has adopted the current trend to reduce the divisions to two groups: 1) well or moderately differentiated; and 2) poorly differentiated.<sup>99,143</sup> Many studies, including some very large retrospective studies (N > 1000) provide evidence that poor differentiation is correlated with CSCC recurrence, metastasis, DSS, and overall survival (OS).<sup>10,45,46,73,75,106,109,114,116,121,129,130,144</sup>

#### **Histology**

The histologic subtypes of acantholytic (adenoid), adenosquamous (or mucin-producing), and metaplastic (carcinosarcomatous) SCC are rare.<sup>145</sup> Only case reports and case series document the outcomes of patients with these subtypes, and thus their prognostic significance is debated.<sup>146-151</sup> Since these tumors may have a high risk of recurrence and likely would not be included in the high-risk category on the basis of their degree of differentiation, the panel decided to list them as separate risk factors.

Another histologic feature associated with greatly increased risks of recurrence and metastasis is desmoplasia.<sup>74,152</sup> A retrospective study using the PALGA national registry of the Netherlands reported significantly higher rates of metastasis for desmoplastic versus non-desmoplastic CSCCs: 89% versus 21% (P < .001).<sup>113</sup> A more recent review of 72 patients with desmoplastic SCC reported a rate of recurrence of 80%.<sup>153</sup>

#### **Depth**

Data from many large studies support that risk of recurrence and metastasis increases with increasing lesion depth.<sup>10,45,73,75,99,109,113-115,121,154</sup> CSCC lesion depth can be quantified as thickness in mm<sup>155</sup> or by anatomic layer(s) invaded, both of which have been included in the T classification of the AJCC 7<sup>th</sup> and 8<sup>th</sup> Edition staging for CSCC.<sup>143,156</sup>

Prospective data from Brantsch and colleagues reported metastasis rates of 0% of tumors ≤ 2.0 mm in thickness, 4% of tumors 2.1-6.0 mm in thickness, and 16% of tumors thicker than 6.0 mm, with depth measured as the greatest vertical distance from the top to the bottom of the tumor.<sup>74</sup> Other studies show that the risk of recurrence and metastasis is significantly higher for lesions with thickness >2 mm.<sup>73,109,115</sup> Meta-analyses have shown that 4-mm and 6-mm thickness cutoffs are prognostic for recurrence and metastasis,<sup>45,73</sup> and one retrospective study showed that risk for recurrence and metastasis increases significantly for every 1-mm increase in tumor depth.<sup>102</sup> Regarding anatomic level of invasion, some studies showed significantly higher risk of recurrence or metastasis for CSCC lesions with Clark levels IV-V, corresponding to invasion of the deep reticular dermis or subcutaneous fat, respectively.<sup>45,113</sup> Other studies have shown that lesions with invasion into the subcutaneous fat significantly increases rates of recurrence and metastasis.<sup>10,73,75,99,112,114,115</sup>

The NCCN Panel has chosen thickness > 6 mm or invasion beyond subcutaneous fat to be considered high risk. If clinical evaluation of



# NCCN Guidelines Version 1.2024

## Squamous Cell Skin Cancer

incisional biopsy suggests that microstaging is inadequate, the Panel recommends considering narrow margin excisional biopsy to obtain accurate measurement of thickness and anatomic level of invasion.

### ***Perineural Involvement***

PNI is uncommon in any non-melanoma skin cancer (NMSC), but develops more frequently and is more aggressive in CSCC versus BCC.<sup>140,141,157,158</sup> PNI poses increased risks of recurrence, metastasis (nodal and distant), and death, is more common in recurrent versus primary tumors, and is associated with other risk factors, including larger lesion size, poor differentiation, and adenosquamous, desmoplastic, and metaplastic subtypes.<sup>10,45,73,75,99,106,112,114,129,136-138,153,159-162</sup> Specifically, PNI with tumor cells within the nerve sheath of a nerve lying deeper than the dermis or measuring  $\geq 0.1$  mm has been associated with metastasis and DSS.<sup>99,103,156</sup> If large nerve involvement is suspected, MRI should be considered to evaluate extent and/or rule out skull involvement in those with head and neck tumors.<sup>96,97,135,142,163</sup>

### ***Lymphatic or Vascular Involvement***

Significant association between lymphovascular invasion (LVI) and LN metastasis has been reported in prospective<sup>116,138</sup> and retrospective studies<sup>137</sup>. One retrospective study showed that in high-risk CSCC populations with PNI or neurotropism, LVI was significantly associated with DSS and all-cause death.<sup>103</sup>

## **Treatment Modalities for Local SCC**

### **Curettage and Electrodesiccation (C&E)**

C&E is a fast and cost-effective technique for superficial lesions; however, it does not allow histologic margin assessment. Retrospective and observational data with long-term follow-up (>5 year) indicate that cure rates are between 95-100% for patients with primary CSCC lesions treated with C&E.<sup>45,164-166</sup> These estimates are largely based on low-risk cases, and there is evidence to suggest that the cure rate is lower for tumors with risk factors. One study reported recurrence rates of 0.4% versus 11% for CSCCs with diameter less than versus greater than 2 cm, and another reported a recurrence rate of 19% for SCCs on the skin of the pinna that were treated with C&E.<sup>167,168</sup>

The NCCN panel recommends this technique as a primary treatment option for **local, low-risk CSCCs** with three caveats. First, this technique should not be used to treat areas with terminal hair growth such as the scalp, pubic or axillary regions, or beard area in males due to the risk that a tumor extending down follicular structures might not be adequately removed. Second, if the subcutaneous layer is reached during the course of C&E, then surgical excision should generally be performed instead. This change in therapy is necessary as the effectiveness of the C&E technique rests on the ability of the clinician to distinguish between firm, normal dermis, and soft tumor tissue when using a sharp curette. Since subcutaneous adipose is even softer than tumor tissue, the ability of the curette to distinguish, and therefore to selectively and completely remove tumor cells, diminishes. Third, if C&E has been performed based only on the appearance of a low-risk tumor, biopsy results of the tissue taken at the time of C&E should be reviewed to make sure that there are no high-risk pathologic features that would require additional therapy. For **local, high-risk/very-high-risk CSCC** tumors in the cheeks, forehead, scalp, neck, and pretibial that are < 6mm in depth and confined to the





# NCCN Guidelines Version 1.2024

## Squamous Cell Skin Cancer

dermis, C&E may be considered as an alternative primary treatment option if comorbidities or other factors make surgical excision difficult.

### Mohs Micrographic Surgery or Excision with Peripheral and Deep En Face Margin Assessment (PDEMA)

Mohs is a primary treatment option for **local, low-risk CSCC** and **local, high-risk CSCC**, as well as the preferred surgical technique for **local, very-high-risk CSCC** because it allows intraoperative analysis of 100% of the excision margin. An extensive meta-analysis of studies with long-term follow-up ( $\geq 5$  years) reported local recurrence rates of 3.1% for primary CSCCs and 10% for recurrences treated with Mohs.<sup>45</sup> Moreover, local recurrence rates have been reported to be significantly less likely with Mohs compared to standard excision.<sup>169,170</sup> Cure rates for Mohs depended on tumor diameter ( $< 2$  vs.  $\geq 2$  cm: 98.1% vs. 74.8%) and differentiation (well vs poorly differentiated: 97.0% vs. 67.4%). For each of these subgroups, cure rates for Mohs were higher than for treatment with non-Mohs modalities.<sup>45</sup>

Retrospective and prospective observational studies of localized primary SCCs treated with Mohs reported local recurrence rates of 1.2% to 4.1% and rates of metastases between 0% and 6.3%.<sup>164,165,171-184</sup> Compared with primary tumors, rates of local recurrence or metastasis after Mohs are higher for recurrent tumors (previously treated with a non-Mohs modality).<sup>114,173</sup> For recurrent CSCCs treated with Mohs, subsequent local recurrences occurred in 5.9% to 7.7% of cases; metastasis in 0% to 10%.<sup>171-177</sup> Other risk factors associated with recurrence after Mohs include larger subclinical extension and more Mohs stages required for clearance.<sup>173</sup> CSCC with PNI is associated with elevated rates of recurrence (6.8%-32.3%) in studies that occasionally include BCC as well as treatment by RT.<sup>140,159,161,185-187</sup> Risk factors associated with metastasis after Mohs include: size  $> 2$  cm, Clark's level (metastatic CSCC are more likely to be deeper – Clark level III-V), poor differentiation, location in areas

of prior radiation, small tumor nests and infiltrative tumor strands, single-cell infiltration, PNI, and acantholysis.<sup>114</sup>

It is not uncommon to find discrepancies between pathology results from preoperative biopsy or initial debulking compared with frozen sections taken during Mohs.<sup>188-190</sup> When Mohs with marginal assessment is being performed and the preoperative biopsy is considered insufficient for providing all the staging information required to properly treat the tumor, submission of the central specimen for pathologic evaluation with paraffin sections is recommended. If invasion to the parotid fascia is noted, superficial parotidectomy may be indicated.

Excision with PDEMA using permanent section analysis or intraoperative frozen section analysis (IOFSA) is acceptable as an alternative to Mohs provided that it includes a complete assessment of en face peripheral and horizontal deep margins coupled with close communication between pathologists and surgeons regarding where within the tumor bed further resection is needed. These subsequent specimens must also be processed and results communicated via the PDEMA method. Low recurrence rates (0%–1%), and specifically lower recurrence rates when compared directly to standard excision,<sup>191</sup> have been reported where histologically clear margins are achieved.<sup>192</sup> It is important to note that truly histologically negative margins are not necessarily achieved by IOFSA alone, without PDEMA. Studies have reported that for CSCC tumors with negative margins upon IOFSA, permanent paraffin section analysis indicates positive margins in 10% to 20%.<sup>189,190,193-195</sup> These discrepancies may be due to unrepresentative sampling of the margins, and IOFSA cases in which permanent section showed positive margins have reported much higher recurrence rates.<sup>195</sup> Overall, the descriptive term PDEMA underscores the Panel's belief that complete assessment of all tissue margins is the key to optimal tumor removal for high-risk tumors. Such effort at local control is particularly important in SCC because one third of



# NCCN Guidelines Version 1.2024

## Squamous Cell Skin Cancer

deaths occur from local disease alone. Mohs or other forms of PDEMA are also recommended in case of positive margins after standard excision for both **local, low-risk CSCC** and **local, high-risk/very-high-risk CSCC**.

### Standard Excision with Postoperative Margin Assessment

A common therapeutic option for CSCC is standard surgical excision followed by postoperative pathologic evaluation of margins. Retrospective analyses and prospective observational studies have reported rates of recurrence or metastasis ranging from 0% and 14%, with most studies reporting rates of 6% or lower.<sup>45,115,144,154,164,165,176,181,196-200</sup> Distant metastasis was rarely observed, and rates of regional metastasis were highly variable across studies, ranging from 0% to 13%.<sup>144,154,181,196,200,201</sup> One large meta-analysis found that recurrence rates were lower for primary versus recurrent tumors, both with follow-up of less than 5 years (5.7% vs. 17.3%) and with longer follow-up (8.1% vs. 23.3%).<sup>45</sup> Incomplete excisions can depend on lesion location, thickness, PNI, invasion into the deep fascia, differentiation, surgeons' skills, and primary versus recurrent tumors,<sup>173,202-204</sup> among other factors.<sup>181,196,205-212</sup>

The clinical margins chosen by the NCCN Panel for the primary treatment of **local, low-risk CSCC** are based on the work of Brodland and colleagues.<sup>213</sup> Their analysis indicated that for well-circumscribed CSCC lesions less than 2 cm in diameter, excision with 4-mm clinical margins should result in complete removal in more than 95% of cases. For low-risk lesions >2 cm in diameter, results indicated that 6-mm margins would be needed to achieve histologically clear margins in 95% cases.

The NCCN Panel also recommends standard excision as the primary treatment for **local, high-risk/very-high-risk CSCC** when Mohs micrographic surgery (Mohs) and other forms of PDEMA is not available, however, wider surgical margins than those recommended for low-risk lesions must be taken and increased recurrence rates should be expected.

According to Brodland et al., for CSCCs in high-risk locations (scalp, ears, eyelids, nose, lips) or with other high-risk features (histologic grade  $\geq 2$ , invasion of subcutaneous tissue), lesions with a diameter <1 cm, 1 to 1.9 cm, and  $\geq 2$  cm would require margins of at least 4 mm, 6 mm, and 9 mm, respectively.<sup>213</sup> Other retrospective analyses of CSCCs removed with Mohs further support that larger excision margins are needed to consistently achieve clear margins as tumor diameter increases and when other risk factors are present.<sup>173,177,202,214</sup> Currently, European Guidelines recommend standard excisions with 6 to 10 mm peripheral clinical margins for high-risk to very-high-risk CSCCs.<sup>215-218</sup> Due to the wide variability of clinical characteristics that may define a very-high-risk tumor, it is not feasible to recommend a defined margin for standard excision of very-high-risk CSCC. Keen awareness of the subclinical extension of CSCC is advised when selecting a treatment modality with incomplete margin assessment for a very-high-risk tumor. These margins may need to be modified based on tumor- or patient-specific factors.

Whenever standard excision is utilized, any peripheral rim of erythema around a SCC must be included in what is assumed to be the tumor. For patients with positive margins from surgical excision and postoperative margin assessment, re-excision often yields clean margins, and in many cases, the re-excision specimen contains no tumor cells.<sup>144,154,197,219-221</sup> Re-excision with postoperative margin assessment is therefore among the recommended treatment options for positive margins after standard excision of both **local, low-risk CSCC** and **local, high-risk/very-high-risk CSCC**. In any case, tissue rearrangement should not be undertaken until clear margins are identified.

### Radiation Therapy

#### **Radiation as Primary Therapy**

Although surgery is the mainstay of local treatment for SCC, patient preference and other factors may lead to the choice of RT as primary



# NCCN Guidelines Version 1.2024

## Squamous Cell Skin Cancer

therapy for **local, low-risk** and **local, high-risk/very-high-risk CSCC**. A large meta-analysis reported 5-year recurrence rates of 6.7% and 10% after RT of primary and recurrent SCC, respectively.<sup>45</sup> Subsequent retrospective analyses of patients with primary CSCCs have reported a large range of recurrence rates, from 2.8% to 42%, the latter for patients with locally advanced disease (size >2 cm or deeply invasive).<sup>164,222-228</sup> The risk of recurrence appears to increase with increasing lesion size and T-stage.<sup>225,227,229</sup> A few small studies (n < 20) have reported that for CSCCs that have been previously treated and recurred, treatment with RT results in recurrence in 16.7% of cases.<sup>224,227</sup>

Retrospective analyses have reported recurrence rates ranging from 0% to 10.5% in situ SCC lesions treated with RT as primary therapy, with most studies reporting local control rates near 100%.<sup>226,227,230-233</sup>

### Adjuvant Radiation

For **local, low-risk** and **local, high-risk/very-high-risk CSCC**, the NCCN panel recommends adjuvant RT for non-surgical candidates in case of positive margins after definitive surgery. It has been shown that adjuvant RT improved locoregional control and survival outcomes for patients with positive margins after surgery or other high-risk features for recurrence.<sup>234-239</sup> However, RT in the progressive disease is usually not curative so every effort should be taken to obtain a clear surgical margin prior to RT initiation.<sup>186</sup> For any CSCC that shows evidence of extensive perineural, large, or named nerve involvement, or if other poor prognostic features are present, adjuvant RT can be considered even if negative margins are achieved after surgery.<sup>239</sup> The outcome benefit of adjuvant RT following resection of CSCC with negative margins has recently been estimated to be approximately 50% reduction in local and nodal recurrence risks,<sup>240</sup> despite older inconclusive data.<sup>238,241,242</sup> Other retrospective studies combined results for patients treated with other modalities (eg, Mohs/standard excision alone, RT alone, chemotherapy), patients with

other types of skin cancer (BCC and metatypical BCC), patients with LN metastases, and a mix of patients with primary and recurrent skin lesions, with and without positive margins.<sup>139,161,237,243-245</sup> These studies suggest that postoperative RT for patients with high-staged CSCC may improve local and regional control and disease-free survival (DFS), but a survival benefit has not been demonstrated.

### Radiotherapy Safety & Administration

The NCCN Panel previously cautioned that RT is often reserved for patients >60 years because of concerns about long-term sequelae, including secondary malignancies; however, this statement has been retracted. This is because age is no longer a major factor in determining treatment modality.

Large cohort and population-based studies (N > 1000) have shown that rates of NMSCs are significantly higher in those who received prior RT (either for a benign condition or for cancer) compared with those who have no history of therapeutic RT exposure.<sup>246-249</sup> In patients who developed NMSC after prior RT, most NMSC lesions occurred within the radiation field, with elevated risk of NMSC confined to the site of RT exposure. The risk of NMSC was particularly high in patients who received therapeutic RT early in life.

RT can result in poor cosmetic outcomes, including telangiectasia, changes in skin pigmentation, and fibrosis. More serious long-term complications include non-healing ulcers (especially for SCC in situ<sup>230-232</sup>); soft tissue, cartilage, bone, or brain necrosis; decreased sensation; and cataracts (for lesions in the periorbital region).<sup>227,229,231,233,250-252</sup>

Specifics about the application of RT, including total doses, treatment duration, and contraindications, are described under *Principles of Radiation Therapy* in the Algorithm. RT is contraindicated in patients with genetic conditions predisposing to irradiation-related skin cancer (eg,





# NCCN Guidelines Version 1.2024

## Squamous Cell Skin Cancer

basal cell nevus syndrome<sup>253-257</sup> and DNA-repair disorders such as Fanconi's anemia, xeroderma pigmentosum), and relatively contraindicated in patients with connective tissue diseases (eg, lupus, scleroderma).<sup>258-260</sup> Given higher rates of poor cosmesis and complications with increasing cumulative radiation dose,<sup>229,250,261</sup> reirradiation should not be routinely utilized for recurrent disease within a prior radiation field. Protracted fractionation is associated with improved cosmetic results,<sup>250,252,262</sup> and should be utilized for poorly vascularized or cartilaginous areas. Retrospective studies have found that for patients with CSCC and PNI, progressive disease tends to occur along involved nerves.<sup>139,263,264</sup> The NCCN Panel recommends including the course of the local nerves proximally for extensive PNI, clinically evident PNI, or involvement of named nerves (particularly in the head and neck region).

A variety of external beam options have been shown to be effective for treating CSCC and have similar cosmetic/safety results.<sup>229,250,262,265-267</sup> Isotope-based brachytherapy can be an effective treatment for certain sites of disease, particularly on the head and neck.<sup>268-274</sup> A retrospective multicentric analysis of 1676 carcinomas of the skin of the nose and nasal vestibule yielded a local control rate of 93% with a minimum follow-up of 2 years. It was determined in this study that local control depended on tumor size (diameter < 2 cm: 96%, 2-3.9 cm: 88%, ≥ 4 cm: 81%) and tumor site (external surface of the nose: 94%, vestibule: 75%).<sup>273</sup> On the other hand, there are insufficient long-term efficacy and safety data to support the routine use of electronic surface brachytherapy.

### Sentinel Lymph Node Biopsy

The NCCN Panel recommends a discussion and consideration of sentinel lymph node biopsy (SLNB) prior to PDEMA for very-high-risk CSCCs that are recurrent or have multiple risk factors placing them in the very high-risk group, and have normal exam of the draining nodal basin. Studies have reported sub-clinical nodal metastases in 7% to 21% of patients with

high-risk non-anogenital CSCC who underwent SLNB.<sup>100,110,137,138,275-281</sup> Although small sample sizes and low rates of SLN positivity limit assessment of prognostic factors, a few studies suggest that risk factors for SLNB positivity include tumor diameter and thickness, LVI, PNI, and the presence of multiple high-risk factors.<sup>100,137,138,279,282</sup>

Several studies reported that among patients with localized SCC and a negative SLNB, nodal metastases were later detected in 2% to 15% of patients.<sup>100,110,137,138,276-278,280,283</sup> In addition to false negatives, some studies documented patients with a negative SLNB who developed local recurrences or metastases outside of the previously biopsied LN basin.<sup>110,138,276</sup> It has been shown that despite receiving completion lymph node dissection, patients with a positive SLN had higher rates of postoperative recurrence/metastases, ranging from 33% to 45%,<sup>137,138,276,279</sup> and were also more likely to die from SCC, with significantly lower 3-year DSS rates compared to patients who have a negative SLN.<sup>110,138,279</sup> Therefore, although SLNB may have prognostic value, it is unclear whether SLNB followed by completion lymph node dissection or adjuvant RT improve patient outcomes.

### Systemic Therapy for Local High-Risk SCC

The NCCN Panel recommends systemic therapy with or without RT for **local, high-risk/very-high-risk CSCC** in case of positive margins after Mohs or other forms of PDEMA, residual disease after definite surgery, and for non-surgical candidates. For patients who have complicated cases of locally advanced disease in which curative surgery and curative RT are not feasible, multidisciplinary consultation is recommended to consider systemic therapy alone (Refer to *Principles of Systemic Therapy* in the algorithm and Discussion section *Systemic Therapy Options*). In the absence of data from prospective comparative studies, it is unclear which systemic therapies are appropriate for localized disease in the context of concomitant RT. In contrast, large randomized trials have tested systemic





# NCCN Guidelines Version 1.2024

## Squamous Cell Skin Cancer

therapy options for head and neck mucosal SCCs.<sup>284-286</sup> Therefore, for the rare cases of localized high-risk SCC in which chemoradiation is considered, the NCCN panel recommends referring to the systemic therapy options for mucosal SCC in the NCCN Guidelines for Head and Neck Cancers.

### Regional Lymph Node Involvement in SCC

Regional nodal involvement significantly increases the risk of recurrence and mortality.<sup>47,109,121</sup> Nodal metastasis also commonly coincides with other adverse histopathologic findings such as LVI, poor differentiation, and PNI.<sup>10,75,99,106,109,114,116,121,287</sup> About 60-82% of patients with nodal disease show involvement in the parotid gland, while cervical neck node disease without parotid invasion is observed in 18-41% of cases.<sup>288</sup>

### Workup for Suspicion of Regional Lymph Node Involvement

The presence of palpable regional LNs or suspicious LNs identified by imaging studies should prompt a fine-needle aspiration (FNA) or core biopsy of suspicious node(s). If initial pathology results are negative, the NCCN Panel recommends considering re-evaluation by clinical exam, CT with contrast imaging of the nodal basin, and/or pathology on additional LN specimens taken by repeat FNA, core biopsy, or open biopsy of the suspicious node(s). For patients with pathologic evidence of LN disease, preoperative imaging of the nodal basin by CT with contrast is recommended to determine the size, number, and location of involved nodes. PET/CT of the nodal basin can be useful for RT planning. In addition, chest/abdominal/pelvic CT with contrast or PET/CT are recommended as clinically indicated to rule out distant metastatic disease.

### Treatment of SCC with Regional Lymph Node Involvement

The NCCN Panel recommends resection of regional disease over RT or chemotherapy. RT with or without concurrent systemic therapy is reserved for patients who are not surgical candidates. Most studies of patients with regional involvement CSCC focus on treatment of parotid and/or cervical nodes either with surgery alone (parotidectomy and/or neck dissection) or surgery plus adjuvant RT. Some studies included patients receiving concomitant chemotherapy<sup>76,289-295</sup> or patients who received RT alone<sup>120,294,296-298</sup>. For studies where the majority of patients receive surgery plus adjuvant RT, recurrence rates are 20-35% and estimates of



# NCCN Guidelines Version 1.2024

## Squamous Cell Skin Cancer

5-year DFS and DSS are 59-83% and 63-83%, respectively.<sup>76,77,289,290,292-294,296,298-303</sup> Many studies support that adjuvant RT improved local regional control, DFS, and OS compared with surgery or RT alone.<sup>289,290,293,294,296,298-300,303</sup> In contrast, other studies found no significant association between adjuvant RT and improved disease outcomes.<sup>76,289,301,302</sup> There may be subsets of patients who derive more clinical benefit from adjuvant RT than other patients; however, it is difficult to identify such patients. Results vary for all of the prognostic factors frequently considered such as immunosuppression, primary tumor size, LVI, PNI, differentiation, and features of the regional disease such as extracapsular extension (ECE) and number of involved nodes.<sup>76,77,289,290,292,293,296,298,300,303,304</sup>

Several staging systems have been proposed for regional CSCC, as shown in [Table 1](#). O'Brien proposed a staging system that separates parotid involvement from neck LN involvement based on multivariate analysis showing improved local control for P1 compared with P2/P3.<sup>305</sup> Multivariate analyses of survival and locoregional control have yielded favorable<sup>291,296,298,303</sup> as well as discordant results<sup>77,291,300</sup> regarding the prognostic value of O'Brien P-stage. O'Brien also showed that survival was significantly better for patients with N0/N1 compared with N2.<sup>305</sup> Two studies supported this result,<sup>77,303</sup> but several others did not.<sup>296,298,300</sup> According to the AJCC 7<sup>th</sup> edition, N1 disease with no ECE had a 5-year cure rate of 92%.<sup>139</sup> N2 disease with immunosuppression, in particular patients with transplants or those with hematologic malignancies, on the other hand, had a 5-year survival of 52%, in contrast to 72% for patients who are immunocompetent.<sup>306</sup> The AJCC 7<sup>th</sup> edition staging does not separate parotid from cervical lymph node involvement and includes both 3-cm and 6-cm cutoffs for largest lymph node dimension.<sup>307</sup> Forest et al. found that lymph node size was related to ECE, and that 6-cm cutoff and 3-cm cutoff groups performed similarly.<sup>289</sup> Risk stratification per the NCCN Guidelines takes into account both ECE<sup>300,308,309</sup> and margin status after

resection<sup>291,298,300,305,308</sup> as prognostic factors for recurrence and survival. The recent update of the AJCC staging system also includes ECE as a criterion for determining N-stage.<sup>156</sup> It should be noted that there are studies that showed no significant association between outcomes and ECE or margin status.<sup>291,293</sup>

The NCCN-recommended and preferred treatment for CSCC with lymph node involvement is excision of the primary tumor and regional lymph node dissection for all surgical candidates. Patients treated with dissection of nodes in the trunk and extremities should consider adjuvant RT of the nodal bed, especially if multiple nodes are involved or if ECE is present. For patients with nodal metastasis to the head and neck, the extent of surgery should depend on the number, location, and size of effected nodes. Postoperative adjuvant treatment should depend on the pathologic findings after surgery—namely the extent of resection, number of positive nodes, and presence or absence of ECE. Patients with ECE or incompletely excised nodes should receive adjuvant RT and also consider concurrent systemic therapy depending on individual toxicity tolerance. Patients with inoperable nodal disease should be treated with RT of the nodal bed and consider concurrent systemic therapy. Multidisciplinary consultation is recommended for these cases and should consider the systemic therapies used to treat head and neck squamous cell carcinomas as indicated in the NCCN Guidelines for Head and Neck Cancers. For symptomatic sites, palliative RT or surgery should be considered. Stereotactic body radiation (SBRT) may be appropriate in select patients.

### Systemic Therapy for Regional Disease

The NCCN Panel recommends systemic therapy with or without RT for **regional CSCC** in case of unresectable, inoperable, or incompletely resected nodal disease and concurrently with RT as outlined in *Principles of Systemic Therapy* in the algorithm and Discussion section *Systemic Therapy Options*.



# NCCN Guidelines Version 1.2024 Squamous Cell Skin Cancer

**Table 1. Staging Systems for Regional Cutaneous SCC of the Head and Neck**

O'Brien 2002 Staging System <sup>305</sup>	
Parotid Stage	
Stage	Criteria
P1	1 LN+ ≤3 cm
P2	1 LN+ >3 and ≤6 cm or ≥2 LN+
P3	1 LN+ >6 cm or Involves VII nerve or skull base
Neck Stage	
Stage	Criteria
N0	No clinical neck disease
N1	1 LN+ ≤3 cm ipsilateral
N2	1 LN+ >3 cm or ≥2 LN+ or ≥1 LN+ contralateral

AJCC 7 <sup>th</sup> Edition (2009) Regional LN Staging <sup>307</sup>	
Stage	Criteria
N1	1 LN+ ≤3 cm ipsilateral
N2a	1 LN+ >3 and ≤6 cm ipsilateral
N2b	≥2 LN+ all ≤6 cm ipsilateral
N2c	≥1 LN+ ≤6 cm bilateral/contralateral
N3	≥1 LN+ >6 cm

AJCC 8 <sup>th</sup> Edition (2017) Regional LN Pathological Staging <sup>156</sup>	
Stage	Criteria <sup>a</sup>
N1	1 LN+ ≤3 cm ENE(-)
N2a	1 LN+, >3 and ≤6 cm ipsilateral ENE(-) or 1 LN+ ≤3 cm ipsilateral ENE(+)
N2b	≥2 LN+ all ≤6 cm ipsilateral ENE(-)
N2c	≥1 LN+ all ≤6 cm bilateral/ contralateral ENE(-)
N3a	≥1 LN+ >6 cm ENE(-)
N3b	1 LN+ ≤3 cm ENE(+) contralateral, or ≥1 LN+ >3 cm ipsilateral ENE(+) or ≥2 LN+, any ENE(+)

Forest 2010 N1S3 Staging System <sup>289</sup>	
Stage	Criteria
I	1 LN+ ≤3 cm
II	1 LN+ >3 cm or ≥2 LN+ ≤3 cm
III	≥2 LN+ >3 cm

NCCN Guidelines	
Risk Level	Criteria
Low	1 LN+ ≤3 cm, no ECE
Medium	1 LN+ >3 cm no ECE or ≥2 LN+ no ECE
High	≥1 LN+ with ECE or Incompletely excised disease

ECE, extracapsular extension; ENE(+), with extranodal extension; ENE(-), without extranodal extension; LN+, positive lymph node(s)  
<sup>a</sup>Pathologic criteria



# NCCN Guidelines Version 1.2024

## Squamous Cell Skin Cancer

### Recurrence and Metastasis

Metastatic CSCC is rare, estimated at 1.9-2.7% of all CSCC, with nodal metastases and distant metastatic disease estimated at 3.7% and 0.4%, respectively.<sup>10,106</sup> For the management of local tumor recurrence or new regional disease, the Algorithm directs clinicians to follow the appropriate pathways for primary treatment. Complicated high-risk tumors, regional recurrence, or the development of distant metastases should be managed by a multidisciplinary tumor board. The NCCN Panel encourages participation in a clinical trial for patients with metastatic CSCC. Unfortunately, such trials are scarce. For symptomatic sites, palliative RT or surgery should be considered. SBRT may be appropriate in select patients. Under highly selective circumstances and in the context of multidisciplinary consultation, resection of limited metastases can be considered.

### Systemic Therapy for Distant Metastatic Disease

Unfortunately, evidence regarding systemic therapy for distant metastatic CSCC is limited, except for in the case of the recently established immunotherapy paradigm. Whereas a number of small studies have reported responses to cytotoxic therapy in patients with local or regional CSCC (Refer to *Principles of Systemic Therapy* in the algorithm and Discussion section *Systemic Therapy Options*), few of these studies included patients with distant metastatic CSCC.

### Systemic Therapy Options

Systemic therapy with or without RT is recommended for primary and recurrent locally advanced disease in non-surgical candidates, for patients with resected high-risk regional disease, patients with unresectable, inoperable, or incompletely resected disease, and in patients with regional recurrence or distant metastatic disease. For locoregional disease for which surgery or RT are unlikely to be curative, both cytotoxic and EGFR inhibitor systemic therapy (monotherapy or combination) have been successfully used to reduce tumor load, which in some cases enabled complete resection or complete response with or without concurrent/subsequent RT.<sup>310-314</sup> In the absence of prospective comparative trial data, it is unclear whether systemic therapy provides additional clinical benefit when used postoperatively with RT. Small retrospective studies were unable to establish definitely that the addition of chemotherapy to postoperative RT significantly improved any disease-related outcome in patients with regional disease,<sup>292,309,315-317</sup> except for one study.<sup>318</sup> The emergence of anti-PD-1 inhibitors and robust clinical trial data have recently opened up novel treatment venues for patients with both locally advanced and metastatic CSCC not amenable to surgery and RT. It must be noted that the preferred recommendation for all of these settings is enrolment in a clinical trial.

The systemic therapy options for use with RT recommended by the NCCN Panel are cisplatin (preferred)<sup>319-322</sup> or epidermal growth factor receptor (EGFR) inhibitors (eg, cetuximab<sup>321-329</sup>, erlotinib<sup>330</sup>, gefitinib<sup>314</sup>, panitumumab<sup>331</sup>), cisplatin + 5-fluorouracil (5-FU)<sup>320,328,329,332</sup>, and carboplatin ± paclitaxel<sup>286,319,321</sup> (useful in certain circumstances). Evidence supporting the efficacy of any of these regimens is mostly limited to case reports and small retrospective studies. In a small (N = 21) prospective phase II study in patients with locally advanced primary or nodal disease who received definitive RT with concurrent cisplatin or carboplatin, the overall complete response (CR) was reported to be 63%.<sup>319</sup> Efficacy and





# NCCN Guidelines Version 1.2024

## Squamous Cell Skin Cancer

safety data for cisplatin, cetuximab, or carboplatin + paclitaxel in combination with RT can also be extrapolated from large randomized trials in patients with non-cutaneous head and neck cancers.<sup>284-286</sup> On the other hand, data from a rare, large (N = 321) randomized trial in patients with CSCC of the head and neck testing RT ± carboplatin did not find an added benefit with carboplatin.<sup>315</sup>

The systemic therapy options for use alone without RT recommended by the NCCN Panel are cemiplimab-rwlc<sup>333-336</sup> and pembrolizumab<sup>337,338</sup> (preferred if curative RT or surgery is not feasible for locally advanced, recurrent, or metastatic disease), or carboplatin + paclitaxel<sup>339</sup> (other recommended regimen), and EGFR inhibitors (eg, cetuximab<sup>312,313,322,323,325,327,329,339,340</sup>, panitumumab<sup>331,341</sup>, gefitinib<sup>342</sup>, dacomitinib<sup>343</sup>, erlotinib<sup>344</sup>), capecitabine<sup>312,322</sup>, cisplatin ± 5-FU<sup>310,312,320,322,329</sup>, and carboplatin (useful in certain circumstances) if the patients are ineligible for or progressed on checkpoint inhibitors and clinical trials.

Published data reported an objective response rate (ORR) of 44-54%, CR of 0-13%, and partial response (PR) of 31-50% to cemiplimab-rwlc in patients with locally advanced, recurrent, or metastatic CSCC.<sup>333-336</sup> Data from the phase II KEYNOTE-629 trial, which included patients with locally advanced, recurrent, or metastatic CSCC, reported an ORR of 34-50%, a CR of 4-17%, and a PR of 25-33% for patients treated with pembrolizumab.<sup>337,338</sup> Preliminary data and the clinical experience of NCCN Panel members suggest that other anti-PD-1 inhibitors may also be effective in this setting. It was recently demonstrated in a retrospective study that patients receiving immunotherapy showed a statistically significant better survival compared to those treated with other systemic therapies (P = 0.034);<sup>322</sup> the validity of this finding remains to be tested in prospective randomized studies. The use of immune checkpoint inhibitors might perhaps be extended to other indications, with early reports

advocating its safety and efficacy in the neoadjuvant setting,<sup>345</sup> as well as concurrently with RT.<sup>346</sup>

In the case of EGFR inhibitors, all recommended regimens have been tested in small, single-arm phase II clinical trials among patients with CSCC nonamenable to surgery and RT. However, low rates of response were documented. Among 25 patients who received cetuximab, 8 PR's and 2 CR's were documented, with a disease control rate of 69%.<sup>313</sup> As for gefitinib, among 40 patients treated, the ORR was reported to be 16%, with an additional 35% achieving stable disease at 8 weeks.<sup>342</sup> In a smaller study of 16 patients with CSCC testing panitumumab, the best ORR (PR and CR) was 31%, with a further 6 patients achieving stable disease.<sup>341</sup> The response rates reported for 42 patients treated with dacomitinib were 2% CR, 26% PR, with a disease control rate of 86%.<sup>343</sup> The ORR for 39 patients treated with erlotinib was 10%, with a disease control rate of 71%.<sup>344</sup> Efficacy data for chemotherapeutic agents are not much better. In a systemic review of 60 patients with metastatic CSCC treated with cisplatin, the CR was reported to be 2%, with an ORR of 45% and median DFS of 14.6 months.<sup>329</sup> Data supporting carboplatin utility are even more limited, with most studies examining carboplatin combinations and not carboplatin monotherapy.<sup>322,339</sup>



# NCCN Guidelines Version 1.2024

## Squamous Cell Skin Cancer

### Follow-Up

It has been well-established that 13-50% of these patients will develop another SCC within 5 years.<sup>347-349</sup> This represents at least a 10-fold increase in risk compared to the general population.<sup>348,349</sup> Patients with a prior SCC are also at increased risk of developing cutaneous melanoma and BCC, and patients with multiple prior SCCs are at even higher risk.<sup>88,348</sup> Therefore, continued long-term surveillance of these patients is essential, as is patient education about sun protection and regular self-examination of the skin. Additionally, 70-80% of cutaneous SCC recurrences develop within 2 years of the initial therapy.<sup>10,45,81,99,102</sup> Therefore, close follow-up of these patients during this time period is critical.

Patient education is a key component of follow-up for patients who have had cutaneous SCC. All patients should be made aware of the various resources that discuss skin cancer prevention. Patients should be educated in strict sun protection and taught how to perform a comprehensive self-examination of the skin. For those who had regional SCC, training in self-examination of lymph nodes is also recommended.

Patients should also be monitored with regular physical exams including complete skin and regional lymph node examination. The frequency of follow-up should be adjusted based on risk (Refer to *SCC-6 Follow-up* in the Algorithm). For following disease, the imaging modality and targeted area should be at the discretion of the treating team based on the suspected extent of disease (ie, local, regional, metastatic). Histologic confirmation is often sufficient to diagnose local recurrence, but MRI can be considered to assess extent of local disease. For nodal or distant metastases, histologic analysis and/or other imaging modalities can be employed for confirmation and to gauge extent of disease. In certain patients at high risk for multiple primary tumors, increased surveillance and consideration of prophylactic measures may be indicated.

### Superficial Therapies for SCC *In Situ*

Given the limited penetration beyond the epidermis and lower cure rates than with surgical techniques, superficial therapies should be reserved for those patients with SCC in situ.<sup>350-353</sup> The NCCN Panel's experience indicates that they may be effective for anatomically challenging locations, and recurrences are often small and manageable. Recommended superficial therapies include topical fluorouracil (5-FU), topical imiquimod, photodynamic therapy (PDT), and cryotherapy.

Retrospective studies, meta-analyses, and a small open-label phase II trial have shown that imiquimod was effective for treating patients with SCC in situ, with high rates of initial clearance (70%–100%) and low rates of recurrence.<sup>354-358</sup> One small double-blind randomized trial showed that imiquimod led to the resolution of 73% of lesions compared to 0% with vehicle control ( $P < .001$ ).<sup>359</sup> Clearance rates with 5-FU tend to be lower than those for topical imiquimod and vary widely, ranging from 27% to 92%.<sup>355,358,360-362</sup> Toxicities are similar between imiquimod and 5-FU, being primarily inflammatory skin reactions such as severe eczematous reactions, ulceration, and erosions.<sup>355,361,362</sup>

PDT with photosensitizing agents including methyl aminolevulinate (MAL) and 5-aminolevulinic acid (ALA) is another option for superficial SCC. MAL is no longer produced in the United States. For SCC in situ, rates of initial complete clearance following PDT range between 52% and 98%.<sup>361,363-374</sup> Durable complete response rates range from 48% to 89%.<sup>361-366,368-372,374,375</sup> It has been shown that differences in PDT techniques can cause significant differences in clearance rate for SCC in situ.<sup>364,372</sup> Furthermore, results from randomized trials showed fewer treatments required for complete clearance and higher durable complete response rates with PDT versus cryotherapy.<sup>362,376</sup> Compared to 5-FU, PDT was also associated with higher rates of initial complete clearance and higher durable complete response rates.<sup>361,362</sup> Data suggest that 5-FU may be associated with



# NCCN Guidelines Version 1.2024

## Squamous Cell Skin Cancer

lower risk of adverse events compared with PDT or cryotherapy, but it is unclear whether risk of toxicity differs between cryotherapy and PDT.<sup>361,362,376</sup>

Cryotherapy has been used for many years as a fast and cost-effective means for removal of SCCs. Prospective and retrospective studies, including large meta-analyses, have shown recurrence rates of 0% to 4% for invasive SCCs treated with cryotherapy.<sup>45,377-380</sup> For SCC in situ, recurrence rates range from 1% to 13% in retrospective studies<sup>230,351,352,380</sup> and 0% to 50% in prospective studies.<sup>350,362,376,379,381</sup> One prospective study reported that patients were much more likely to experience pain with cryotherapy compared with C&E, and time to complete healing was also significantly longer with cryotherapy.<sup>350</sup> Cryotherapy may also be associated with poorer cosmetic outcomes compared with topical 5-FU.<sup>362</sup>

### Care for Patients at High Risk of Developing Multiple SCCs

#### Treatment of Precancers in Patients at High-risk

AKs are a premalignant skin condition that should be treated at first development, particularly in patients with diffuse AKs and/or field cancerization, as these patients are at high risk of developing multiple primary CSCCs.<sup>382</sup> Cryotherapy has been used to treat AK for many decades, despite lack of prospective randomized trials comparing them with non-treatment. In more recent years, large prospective randomized trials in patients with AKs (N > 100) have shown that each of the following therapies provides better complete clearance rates compared with placebo: topical 5-FU with or without calcipotriol,<sup>383-388</sup> topical imiquimod,<sup>389-392</sup> topical tirbanibulin,<sup>393</sup> and PDT.<sup>394-402</sup>

Prospective randomized trials have reported pair-wise comparisons of the above treatments, but results are not consistent. These comparisons include PDT versus cryotherapy,<sup>394,396,399,403-405</sup> imiquimod,<sup>406,407</sup> 5-FU,<sup>408-410</sup> or ingenol mebutate,<sup>411-413</sup> cryotherapy versus 5-FU or imiquimod,<sup>414-416</sup> and 5-FU versus imiquimod<sup>417</sup> or ingenol mebutate.<sup>418,419</sup> Meta-analyses of randomized trials have attempted to determine an order of preference for these treatments.<sup>420-423</sup> The NCCN panel currently assigns a preference for 5-FU based on data from a randomized trial which reported the cumulative probability of remaining free from disease progression was significantly higher for 5-FU (74.7%) than imiquimod (53.9%), MAL-PDT (37.7%), or ingenol mebutate (28.9%).<sup>424</sup> The longest duration for CSCC prophylaxis has been demonstrated with the combination of 5-FU and calcipotriol.<sup>388</sup> It was demonstrated that more participants who received topical calcipotriol plus 5-FU for AK remained disease-free over the > 1,500-day period compared to those receiving petroleum jelly-based skin product plus 5-FU.<sup>425</sup> Moreover, significantly fewer participants in the test cohort developed CSCC on the treated face and scalp within 3 years (7% vs. 28% in control group, hazard ratio 0.215, *P* = 0.032).<sup>425</sup>





# NCCN Guidelines Version 1.2024

## Squamous Cell Skin Cancer

Topical tirbanibulin was added to the list of recommended treatment for AK based on results from two identically designed double-blind phase III trials in which patients received either tirbanibulin or vehicle ointment for the treatment of AKs on the face or scalp. In both trials, complete clearance by day 57 occurred in significantly more patients in the tirbanibulin group compared to the vehicle group (trial 1: 44% versus 5%,  $P < 0.001$ ; trial 2: 54% versus 13%,  $P < 0.001$ ).<sup>393</sup>

The utility of topical diclofenac is less clear, as efficacy results vary across large randomized trials, with some studies reporting no significant difference between diclofenac/hyaluronan and hyaluronan alone.<sup>387,426-428</sup> Diclofenac/hyaluronan has also been shown to be inferior to MAL-PDT and to 5-FU for the treatment of AKs.<sup>429,430</sup> The Panel therefore assigns category 2B for diclofenac in this setting.

Fewer high-quality data are available regarding the efficacy and safety of other treatments that are sometimes used and may be considered for treating AKs: chemical peels (trichloroacetic acid) and ablative skin resurfacing (eg, dermabrasion, laser).<sup>431-438</sup> These studies have all confirmed that chemical peel or laser resurfacing significantly reduced AKs, although in some studies they were less effective than PDT or 5-FU. The use of chemical peels and ablative skin resurfacing varies widely across NCCN institutions.

AKs that have an atypical clinical appearance or do not respond to appropriate therapy should be biopsied for histologic evaluation. AK on the lip, known as actinic cheilitis, may require a different approach. Prospective studies on the treatment of actinic cheilitis are limited. Therapies tested include surgical vermilionectomy, lip shave, electrodesiccation, laser vermilion ablation, laser resurfacing, 5-FU, laser + 5-FU, trichloroacetic acid (TCA) chemical peel, PDT, PDT + imiquimod, and diclofenac.<sup>439-450</sup> The NCCN panel considers ablative laser

vermilionectomy to be of value for treating some cases of extensive actinic cheilitis.

### Treatment of SCC in Patients at High-Risk

For individuals who rapidly develop multiple CSCC lesions, destructive techniques such as C&E and cryotherapy may be employed. Some NCCN panel members use a combination of shave excision to remove the bulk of the tumor and ensure sufficient material for pathology, and then destructive techniques for margin control. The details of the techniques used to remove CSCC lesions in patients at high-risk with multiple lesions vary widely between NCCN Member Institutions and between practitioners at these institutions, and there is no standard language for describing these methods. Compared to the low-risk population, RT is used more frequently as an adjuvant therapy in patients at high-risk and for PNI.<sup>451</sup> Satellite lesions and in-transit cutaneous metastases may occur more frequently and are more likely to progress in this population.<sup>452,453</sup>

One strategy for cases of life-threatening skin cancer or rapid development of multiple tumors in organ transplant recipients is dose reduction of immunosuppressive therapy and/or the use of mTOR inhibitors. Analyses of large populations of patients with organ transplants have found that the incidence of new skin cancers is linked to the duration and dose of immunosuppression.<sup>454-456</sup> Prospective randomized trials have shown that switching from other immunosuppressants to mTOR inhibitors reduces the risk of developing new CSCC lesions, particularly in patients with a history of one or more CSCCs.<sup>457-465</sup> In the case where surgery is impractical due to high CSCC burden, oral capecitabine has been suggested in the transplantation setting, although toxicity is a concern.<sup>466</sup>

### Prevention in Patients at High-Risk

Treatment of precancers at first development can help prevent the development of subsequent invasive tumors. Prophylactic treatment may



# NCCN Guidelines Version 1.2024

## Squamous Cell Skin Cancer

be needed for patients with a history of multiple lesions and/or extensive diffuse AK or field cancerization. Oral retinol and synthetic retinoids (eg, acitretin<sup>467</sup>, isotretinoin, etretinate) have been tested in prospective studies in patients at high risk for multiple AKs or SCCs, including transplant recipients,<sup>468-473</sup> patients with xeroderma pigmentosa,<sup>474</sup> or with psoriasis and PUVA (psoralen plus UV-A) exposure.<sup>475</sup> By comparison with placebo or with SCC incidence during treatment-free periods, data from these studies support that oral retinol and oral retinoids significantly reduce the incidence of new CSCCs in patients at very high risk for multiple lesions.<sup>469-472,474,475</sup> Outside of these very-high-risk groups, the effectiveness of retinol/retinoid therapy for prophylaxis is less clear.<sup>476-478</sup> Side effects may be significant and include mucocutaneous, such as cheilitis, excessive peeling of the skin, and hair disorders,<sup>473</sup> but musculoskeletal, vascular, hepatic triglyceride, and neurologic adverse events have also been reported.<sup>472,474,477,479</sup> In addition, these agents are teratogenic and must be used with extreme caution in individuals of child-bearing potential.<sup>480</sup>

The NCCN guidelines do *not* recommend topical retinoids as prophylactic treatment for patients at high risk for multiple AKs or CSCCs. Results of a large randomized trial in patients with a history of  $\geq 2$  BCCs/SCCs showed that prophylactic topical tretinoin (0.1%) did not reduce the development of new cutaneous BCCs or SCCs compared with vehicle control.<sup>481</sup> A double-blind randomized study showed that topical tazarotene had a chemopreventative effect in only 6% of patients with basal cell nevus syndrome, a condition associated with frequent development of primary BCCs.<sup>482</sup>

Results from a recent randomized controlled study suggest that prophylactic nicotinamide may be effective at preventing the development of CSCC recurrence or metastases in patients at high risk.<sup>483</sup> Nicotinamide was associated with a 30% reduction in the 12-month rate of new SCCs ( $P = 0.05$ ), and a 20% reduction in development of new BCCs ( $P = 0.12$ )

compared to placebo. During the subsequent 6 months off treatment, there was a trend toward increased rates of new SCCs for the nicotinamide arm compared with placebo (59% relative difference;  $P = .07$ ). Although there are currently no clinical trial data directly comparing nicotinamide with oral retinoids for CSCC prophylaxis, nicotinamide has a much better safety profile. Further clinical research is needed to determine whether nicotinamide provides long-term clinical benefit for patients at risk of developing multiple NMSCs and AK lesions.

### Patient Education for Patients at High-Risk

Patient education is especially important for those at high risk for CSCC progression or recurrence. Treatment delay is associated with larger tumor size, larger defect size from surgical removal, and more Mohs layers taken to obtain clear margins.<sup>130,484-487</sup> Significant prognostic factors for patient delay in seeking care include serious comorbidity, low education level, non-recognition of the seriousness of symptoms, and SCC arising on pre-existing chronic lesions.<sup>488,489</sup> Low education level is also associated with large NMSC tumor area at presentation.<sup>490</sup> Educational interventions and physician advice have been shown to increase the likelihood of patients undergoing a complete skin exam, and patients with more knowledge of skin cancer are more likely to get regular complete skin exams.<sup>282,491,492</sup>

Patient education should begin, in the case of organ transplant recipients, at transplantation and in the case of xeroderma pigmentosum, at birth or diagnosis. Education should include discussion of individual risk assessment and the need for stringent sun avoidance and protection methods. Regular sunscreen use can significantly reduce the rate of development of new AKs and CSCCs, and increases remission rates of AKs.<sup>493-496</sup> Knowledge of more than one method for UV protection is associated with higher rates of using some form of protection,<sup>497</sup> as is awareness of susceptibility/risk and overall education level.<sup>498,499</sup>



# NCCN Guidelines Version 1.2024

## Squamous Cell Skin Cancer

Having a prior NMSC has proved to be insufficient motivation for altering patient behavior regarding UV protection and avoidance. Although those with prior NMSC are more likely to use sunscreen and to avoid sun exposure, adoption of preventative measures was low: only 54% used sunscreen, and 20% to 45% used other avoidance/protective methods.<sup>500</sup> Another cross-sectional study showed that tanning bed use was similar among those with and without prior NMSC.<sup>501</sup>

Randomized trials have shown that educational interventions can effect significant changes in use of solar protection in outdoor workers and patients with transplants.<sup>492,502-507</sup> While both extensive and repetitive education improve patient knowledge, repetitive education is needed to effect long-term change in patient behavior.<sup>508</sup> This is especially important for patients with transplants, as preoccupation with other medical concerns may make them unreceptive to skin cancer education.<sup>509</sup> For patients with transplants, an intervention including text messaging reminders was shown to be more effective at improving patient knowledge and changing sun protective behaviors compared with more traditional approaches.<sup>510</sup>

Monthly self-examination is recommended and should include all skin surfaces and LNs. Patients should be taught the proper method for systematic self-examination of the skin and lymph nodes. A randomized controlled trial has shown that educational intervention increased the frequency and sensitivity of self-examination of the skin among patients with transplants.<sup>511</sup> In addition to more frequent and thorough self-examination, follow-up schedules for patients at high risk should be titrated to the frequency of tumor development, and in rare cases may be as frequently as weekly.





# NCCN Guidelines Version 1.2024

## Squamous Cell Skin Cancer

### References

- Rubio-Casadevall J, Hernandez-Pujol AM, Ferreira-Santos MC, et al. Trends in incidence and survival analysis in non-melanoma skin cancer from 1994 to 2012 in Girona, Spain: A population-based study. *Cancer Epidemiol* 2016;45:6-10. Available at: <https://www.ncbi.nlm.nih.gov/pubmed/27639035>.
- Sella T, Goren I, Shalev V, et al. Incidence trends of keratinocytic skin cancers and melanoma in Israel 2006-11. *Br J Dermatol* 2015;172:202-207. Available at: <https://www.ncbi.nlm.nih.gov/pubmed/24976239>.
- Rudolph C, Schnoor M, Eisemann N, Katalinic A. Incidence trends of nonmelanoma skin cancer in Germany from 1998 to 2010. *J Dtsch Dermatol Ges* 2015;13:788-797. Available at: <http://www.ncbi.nlm.nih.gov/pubmed/26213814>.
- Goon PK, Greenberg DC, Igali L, Levell NJ. Squamous Cell Carcinoma of the Skin has More Than Doubled Over the Last Decade in the UK. *Acta Derm Venereol* 2016;96:820-821. Available at: <https://www.ncbi.nlm.nih.gov/pubmed/26631391>.
- Robsahm TE, Helsing P, Veierod MB. Cutaneous squamous cell carcinoma in Norway 1963-2011: increasing incidence and stable mortality. *Cancer Med* 2015;4:472-480. Available at: <http://www.ncbi.nlm.nih.gov/pubmed/25620456>.
- Rogers HW, Weinstock MA, Feldman SR, Coldiron BM. Incidence estimate of nonmelanoma skin cancer (keratinocyte carcinomas) in the U.S. population, 2012. *JAMA Dermatol* 2015;151:1081-1086. Available at: <http://www.ncbi.nlm.nih.gov/pubmed/25928283>.
- Callens J, Van Eycken L, Henau K, Garmyn M. Epidemiology of basal and squamous cell carcinoma in Belgium: the need for a uniform and compulsory registration. *J Eur Acad Dermatol Venereol* 2016;30:1912-1918. Available at: <https://www.ncbi.nlm.nih.gov/pubmed/27256411>.
- Muzic JG, Schmitt AR, Wright AC, et al. Incidence and Trends of Basal Cell Carcinoma and Cutaneous Squamous Cell Carcinoma: A Population-Based Study in Olmsted County, Minnesota, 2000 to 2010. *Mayo Clin Proc* 2017;92:890-898. Available at: <https://www.ncbi.nlm.nih.gov/pubmed/28522111>.
- Perera E, Gnaneswaran N, Staines C, et al. Incidence and prevalence of non-melanoma skin cancer in Australia: A systematic review. *Australas J Dermatol* 2015;56:258-267. Available at: <http://www.ncbi.nlm.nih.gov/pubmed/25716064>.
- Schmults CD, Karia PS, Carter JB, et al. Factors predictive of recurrence and death from cutaneous squamous cell carcinoma: a 10-year, single-institution cohort study. *JAMA Dermatol* 2013;149:541-547. Available at: <http://www.ncbi.nlm.nih.gov/pubmed/23677079>.
- Eisemann N, Jansen L, Castro FA, et al. Survival with nonmelanoma skin cancer in Germany. *Br J Dermatol* 2016;174:778-785. Available at: <https://www.ncbi.nlm.nih.gov/pubmed/26676514>.
- Eigentler TK, Leiter U, Hafner HM, et al. Survival of Patients with Cutaneous Squamous Cell Carcinoma: Results of a Prospective Cohort Study. *J Invest Dermatol* 2017;137:2309-2315. Available at: <https://www.ncbi.nlm.nih.gov/pubmed/28736229>.
- PubMed Overview. Available at: <https://pubmed.ncbi.nlm.nih.gov/about/>. Accessed November 15th, 2021.
- Zanetti R, Rosso S, Martinez C, et al. Comparison of risk patterns in carcinoma and melanoma of the skin in men: a multi-centre case-control study. *Br J Cancer* 2006;94:743-751. Available at: <http://www.ncbi.nlm.nih.gov/pubmed/16495934>.
- Ramsay HM, Fryer AA, Hawley CM, et al. Factors associated with nonmelanoma skin cancer following renal transplantation in Queensland, Australia. *J Am Acad Dermatol* 2003;49:397-406. Available at: <http://www.ncbi.nlm.nih.gov/pubmed/12963901>.
- Wassberg C, Thorn M, Johansson AM, et al. Increasing incidence rates of squamous cell carcinoma of the skin in Sweden. *Acta Derm*



# NCCN Guidelines Version 1.2024

## Squamous Cell Skin Cancer

Venereol 2001;81:268-272. Available at:

<http://www.ncbi.nlm.nih.gov/pubmed/11720174>.

17. Xiang F, Lucas R, Hales S, Neale R. Incidence of nonmelanoma skin cancer in relation to ambient UV radiation in white populations, 1978-2012: empirical relationships. *JAMA Dermatol* 2014;150:1063-1071.

Available at: <http://www.ncbi.nlm.nih.gov/pubmed/25103031>.

18. Juzeniene A, Grigalavicius M, Baturaite Z, Moan J. Minimal and maximal incidence rates of skin cancer in Caucasians estimated by use of sigmoidal UV dose-incidence curves. *Int J Hyg Environ Health* 2014;217:839-844. Available at:

<http://www.ncbi.nlm.nih.gov/pubmed/25023193>.

19. Trakatelli M, Barkitzi K, Apap C, et al. Skin cancer risk in outdoor workers: a European multicenter case-control study. *J Eur Acad Dermatol Venereol* 2016;30 Suppl 3:5-11. Available at:

<http://www.ncbi.nlm.nih.gov/pubmed/26995016>.

20. Xiong MY, Rizzo AE, Cohen TS, et al. Predictors of squamous cell carcinoma in high-risk patients in the VATTC trial. *J Invest Dermatol* 2013;133:1521-1532. Available at:

<https://www.ncbi.nlm.nih.gov/pubmed/23348836>.

21. Suarez B, Lopez-Abente G, Martinez C, et al. Occupation and skin cancer: the results of the HELIOS-I multicenter case-control study. *BMC Public Health* 2007;7:180. Available at:

<http://www.ncbi.nlm.nih.gov/pubmed/17655745>.

22. Hemminki K, Zhang H, Czene K. Time trends and familial risks in squamous cell carcinoma of the skin. *Arch Dermatol* 2003;139:885-889.

Available at: <https://www.ncbi.nlm.nih.gov/pubmed/12873883>.

23. Wehner MR, Shive ML, Chren MM, et al. Indoor tanning and non-melanoma skin cancer: systematic review and meta-analysis. *BMJ* 2012;345:e5909. Available at:

<https://www.ncbi.nlm.nih.gov/pubmed/23033409>.

24. Wehner MR, Chren MM, Nameth D, et al. International prevalence of indoor tanning: a systematic review and meta-analysis. *JAMA Dermatol* 2014;150:390-400. Available at:

<http://www.ncbi.nlm.nih.gov/pubmed/24477278>.

25. Green A, Battistutta D, Hart V, et al. Skin cancer in a subtropical Australian population: incidence and lack of association with occupation. The Nambour Study Group. *Am J Epidemiol* 1996;144:1034-1040.

Available at: <https://www.ncbi.nlm.nih.gov/pubmed/8942434>.

26. English DR, Armstrong BK, Kricger A, et al. Demographic characteristics, pigmentary and cutaneous risk factors for squamous cell carcinoma of the skin: a case-control study. *Int J Cancer* 1998;76:628-634. Available at:

<http://www.ncbi.nlm.nih.gov/pubmed/9610717>.

27. Gallagher RP, Hill GB, Bajdik CD, et al. Sunlight exposure, pigmentation factors, and risk of nonmelanocytic skin cancer. II. Squamous cell carcinoma. *Arch Dermatol* 1995;131:164-169. Available at:

<http://www.ncbi.nlm.nih.gov/pubmed/7857112>.

28. Sitek A, Rosset I, Zadzińska E, et al. Skin color parameters and Fitzpatrick phototypes in estimating the risk of skin cancer: A case-control study in the Polish population. *J Am Acad Dermatol* 2016;74:716-723. Available at:

<https://www.ncbi.nlm.nih.gov/pubmed/26777103>.

29. Box NF, Duffy DL, Irving RE, et al. Melanocortin-1 receptor genotype is a risk factor for basal and squamous cell carcinoma. *J Invest Dermatol* 2001;116:224-229. Available at:

<http://www.ncbi.nlm.nih.gov/pubmed/11179997>.

30. Subramaniam P, Olsen CM, Thompson BS, et al. Anatomical Distributions of Basal Cell Carcinoma and Squamous Cell Carcinoma in a Population-Based Study in Queensland, Australia. *JAMA Dermatol* 2016;153:175-182. Available at:

<https://www.ncbi.nlm.nih.gov/pubmed/27892984>.

31. Athas WF, Hunt WC, Key CR. Changes in nonmelanoma skin cancer incidence between 1977-1978 and 1998-1999 in Northcentral New



# NCCN Guidelines Version 1.2024

## Squamous Cell Skin Cancer

Mexico. *Cancer Epidemiol Biomarkers Prev* 2003;12:1105-1108. Available at: <http://www.ncbi.nlm.nih.gov/pubmed/14578151>.

32. Choi SH, Kim KH, Song KH. Clinical Features of Cutaneous Premalignant Lesions in Busan City and the Eastern Gyeongnam Province, Korea: A Retrospective Review of 1,292 Cases over 19 Years (1995~2013). *Ann Dermatol* 2016;28:172-178. Available at: <http://www.ncbi.nlm.nih.gov/pubmed/27081263>.

33. Dika E, Fanti PA, Misciali C, et al. Risk of skin cancer development in 672 patients affected by actinic keratosis. *G Ital Dermatol Venereol* 2016;151:628-633. Available at: <https://www.ncbi.nlm.nih.gov/pubmed/26381460>.

34. van Rijsingen M, Seubring I, Maessen-Visch B, et al. Insight into the number of pre-malignancies and malignancies of the skin in a hospital population in the Netherlands. *Eur J Dermatol* 2015;25:261-265. Available at: <http://www.ncbi.nlm.nih.gov/pubmed/25786488>.

35. Criscione VD, Weinstock MA, Naylor MF, et al. Actinic keratoses: Natural history and risk of malignant transformation in the Veterans Affairs Topical Tretinoin Chemoprevention Trial. *Cancer* 2009;115:2523-2530. Available at: <https://www.ncbi.nlm.nih.gov/pubmed/19382202>.

36. Marks R, Foley P, Goodman G, et al. Spontaneous remission of solar keratoses: the case for conservative management. *Br J Dermatol* 1986;115:649-655. Available at: <https://www.ncbi.nlm.nih.gov/pubmed/3801305>.

37. Eimpunth S, Goldenberg A, Hamman MS, et al. Squamous Cell Carcinoma In Situ Upstaged to Invasive Squamous Cell Carcinoma: A 5-Year, Single Institution Retrospective Review. *Dermatol Surg* 2017;43:698-703. Available at: <https://www.ncbi.nlm.nih.gov/pubmed/28060173>.

38. Das KK, Chakarabarty A, Rahman A, Khandkar S. Incidences of malignancy in chronic burn scar ulcers: experience from Bangladesh. *Burns* 2015;41:1315-1321. Available at: <http://www.ncbi.nlm.nih.gov/pubmed/25716761>.

39. Senet P, Combemale P, Debure C, et al. Malignancy and chronic leg ulcers: the value of systematic wound biopsies: a prospective, multicenter, cross-sectional study. *Arch Dermatol* 2012;148:704-708. Available at: <https://www.ncbi.nlm.nih.gov/pubmed/22772403>.

40. Adigun IA, Buhari MO, Ayorinde RO. Malignant skin tumor in Blacks: experience in a teaching hospital. *West Afr J Med* 2006;25:276-278. Available at: <https://www.ncbi.nlm.nih.gov/pubmed/17402515>.

41. Khullar G, Saikia UN, De D, et al. Predisposing factors and histopathological variants of cutaneous squamous cell carcinoma: Experience from a North Indian teaching hospital. *Indian J Dermatol Venereol Leprol* 2016;82:273-278. Available at: <http://www.ncbi.nlm.nih.gov/pubmed/27088928>.

42. Nthumba PM. Marjolin's ulcers in sub-Saharan Africa. *World J Surg* 2010;34:2272-2277. Available at: <https://www.ncbi.nlm.nih.gov/pubmed/20645092>.

43. Yakubu A, Mabogunje OA. Skin cancer in Zaria, Nigeria. *Trop Doct* 1995;25 Suppl 1:63-67. Available at: <http://www.ncbi.nlm.nih.gov/pubmed/7879275>.

44. Combemale P, Bousquet M, Kanitakis J, et al. Malignant transformation of leg ulcers: a retrospective study of 85 cases. *J Eur Acad Dermatol Venereol* 2007;21:935-941. Available at: <https://www.ncbi.nlm.nih.gov/pubmed/17659003>.

45. Rowe DE, Carroll RJ, Day CL, Jr. Prognostic factors for local recurrence, metastasis, and survival rates in squamous cell carcinoma of the skin, ear, and lip. Implications for treatment modality selection. *J Am Acad Dermatol* 1992;26:976-990. Available at: <http://www.ncbi.nlm.nih.gov/pubmed/1607418>.

46. Eroglu A, Berberoglu U, Berreroglu S. Risk factors related to locoregional recurrence in squamous cell carcinoma of the skin. *J Surg Oncol* 1996;61:124-130. Available at: <http://www.ncbi.nlm.nih.gov/pubmed/8606543>.





## NCCN Guidelines Version 1.2024 Squamous Cell Skin Cancer

47. Mullen JT, Feng L, Xing Y, et al. Invasive squamous cell carcinoma of the skin: defining a high-risk group. *Ann Surg Oncol* 2006;13:902-909. Available at: <http://www.ncbi.nlm.nih.gov/pubmed/16788750>.
48. Kromberg JG, Castle D, Zwane EM, Jenkins T. Albinism and skin cancer in Southern Africa. *Clin Genet* 1989;36:43-52. Available at: <http://www.ncbi.nlm.nih.gov/pubmed/2766562>.
49. Mabula JB, Chalya PL, McHembe MD, et al. Skin cancers among Albinos at a University teaching hospital in Northwestern Tanzania: a retrospective review of 64 cases. *BMC Dermatol* 2012;12:5. Available at: <https://www.ncbi.nlm.nih.gov/pubmed/22681652>.
50. Yakubu A, Mabogunje OA. Skin cancer in African albinos. *Acta Oncol* 1993;32:621-622. Available at: <http://www.ncbi.nlm.nih.gov/pubmed/8260178>.
51. Opara KO, Jiburum BC. Skin cancers in albinos in a teaching Hospital in eastern Nigeria - presentation and challenges of care. *World J Surg Oncol* 2010;8:73. Available at: <https://www.ncbi.nlm.nih.gov/pubmed/20738853>.
52. Asuquo ME, Ebughe G. Major dermatological malignancies encountered in the University of Calabar Teaching Hospital, Calabar, southern Nigeria. *Int J Dermatol* 2012;51 Suppl 1:32-40. Available at: <https://www.ncbi.nlm.nih.gov/pubmed/23210953>.
53. Halkud R, Shenoy AM, Naik SM, et al. Xeroderma pigmentosum: clinicopathological review of the multiple oculocutaneous malignancies and complications. *Indian J Surg Oncol* 2014;5:120-124. Available at: <http://www.ncbi.nlm.nih.gov/pubmed/25114464>.
54. Kraemer KH, Lee MM, Scotto J. Xeroderma pigmentosum. Cutaneous, ocular, and neurologic abnormalities in 830 published cases. *Arch Dermatol* 1987;123:241-250. Available at: <http://www.ncbi.nlm.nih.gov/pubmed/3545087>.
55. Bradford PT, Goldstein AM, Tamura D, et al. Cancer and neurologic degeneration in xeroderma pigmentosum: long term follow-up characterises the role of DNA repair. *J Med Genet* 2011;48:168-176. Available at: <http://www.ncbi.nlm.nih.gov/pubmed/21097776>.
56. Kraemer KH, Lee MM, Andrews AD, Lambert WC. The role of sunlight and DNA repair in melanoma and nonmelanoma skin cancer. The xeroderma pigmentosum paradigm. *Arch Dermatol* 1994;130:1018-1021. Available at: <http://www.ncbi.nlm.nih.gov/pubmed/8053698>.
57. Kraemer KH, Lee MM, Scotto J. DNA repair protects against cutaneous and internal neoplasia: evidence from xeroderma pigmentosum. *Carcinogenesis* 1984;5:511-514. Available at: <http://www.ncbi.nlm.nih.gov/pubmed/6705149>.
58. Miranda MB, Lauseker M, Kraus MP, et al. Secondary malignancies in chronic myeloid leukemia patients after imatinib-based treatment: long-term observation in CML Study IV. *Leukemia* 2016;30:1255-1262. Available at: <https://www.ncbi.nlm.nih.gov/pubmed/26859076>.
59. Kolaitis NA, Duffy E, Zhang A, et al. Voriconazole increases the risk for cutaneous squamous cell carcinoma after lung transplantation. *Transpl Int* 2017;30:41-48. Available at: <https://www.ncbi.nlm.nih.gov/pubmed/27678492>.
60. Jensen AO, Svaerke C, Farkas D, et al. Skin cancer risk among solid organ recipients: a nationwide cohort study in Denmark. *Acta Derm Venereol* 2010;90:474-479. Available at: <http://www.ncbi.nlm.nih.gov/pubmed/20814621>.
61. Jensen P, Hansen S, Moller B, et al. Skin cancer in kidney and heart transplant recipients and different long-term immunosuppressive therapy regimens. *J Am Acad Dermatol* 1999;40:177-186. Available at: <http://www.ncbi.nlm.nih.gov/pubmed/10025742>.
62. Shang W, Ning Y, Xu X, et al. Incidence of Cancer in ANCA-Associated Vasculitis: A Meta-Analysis of Observational Studies. *PLoS One* 2015;10:e0126016. Available at: <https://www.ncbi.nlm.nih.gov/pubmed/25973882>.



# NCCN Guidelines Version 1.2024

## Squamous Cell Skin Cancer

63. Shah BK, Khanal A. Second Primary Malignancies in Mantle Cell Lymphoma: A US Population-based Study. *Anticancer Res* 2015;35:3437-3440. Available at: <https://www.ncbi.nlm.nih.gov/pubmed/26026107>.

64. Brewer JD, Shanafelt TD, Khezri F, et al. Increased incidence and recurrence rates of nonmelanoma skin cancer in patients with non-Hodgkin lymphoma: a Rochester Epidemiology Project population-based study in Minnesota. *J Am Acad Dermatol* 2015;72:302-309. Available at: <https://www.ncbi.nlm.nih.gov/pubmed/25479909>.

65. Gerber SR, Seifert B, Inci I, et al. Exposure to moxifloxacin and cytomegalovirus replication is associated with skin squamous cell carcinoma development in lung transplant recipients. *J Eur Acad Dermatol Venereol* 2015;29:2451-2457. Available at: <http://www.ncbi.nlm.nih.gov/pubmed/26403508>.

66. Patel RV, Clark LN, Lebwohl M, Weinberg JM. Treatments for psoriasis and the risk of malignancy. *J Am Acad Dermatol* 2009;60:1001-1017. Available at: <http://www.ncbi.nlm.nih.gov/pubmed/19344980>.

67. Zilinska Z, Sersenova M, Chrastina M, et al. Occurrence of malignancies after kidney transplantation in adults: Slovak multicenter experience. *Neoplasma* 2017;64:311-317. Available at: <https://www.ncbi.nlm.nih.gov/pubmed/28052685>.

68. Garritsen FM, van der Schaft J, van den Reek JM, et al. Risk of Non-melanoma Skin Cancer in Patients with Atopic Dermatitis Treated with Oral Immunosuppressive Drugs. *Acta Derm Venereol* 2017;97:724-730. Available at: <https://www.ncbi.nlm.nih.gov/pubmed/28218345>.

69. van den Heuvel TR, Wintjens DS, Jeuring SF, et al. Inflammatory bowel disease, cancer and medication: Cancer risk in the Dutch population-based IBDL cohort. *Int J Cancer* 2016;139:1270-1280. Available at: <https://www.ncbi.nlm.nih.gov/pubmed/27170593>.

70. Diffey BL, Norval M, Albers PN, Wright CY. The influence of HIV infection on the age dependence of squamous cell carcinoma of the skin

in South Africa. *S Afr Med J* 2017;107:127-129. Available at: <https://www.ncbi.nlm.nih.gov/pubmed/28220738>.

71. Hock BD, McIntosh ND, McKenzie JL, et al. Incidence of cutaneous squamous cell carcinoma in a New Zealand population of chronic lymphocytic leukaemia patients. *Intern Med J* 2016;46:1414-1421. Available at: <https://www.ncbi.nlm.nih.gov/pubmed/27664975>.

72. Gupta AK, Cardella CJ, Haberman HF. Cutaneous malignant neoplasms in patients with renal transplants. *Arch Dermatol* 1986;122:1288-1293. Available at: <http://www.ncbi.nlm.nih.gov/pubmed/3535683>.

73. Thompson AK, Kelley BF, Prokop LJ, et al. Risk Factors for Cutaneous Squamous Cell Carcinoma Recurrence, Metastasis, and Disease-Specific Death: A Systematic Review and Meta-analysis. *JAMA Dermatol* 2016;152:419-428. Available at: <http://www.ncbi.nlm.nih.gov/pubmed/26762219>.

74. Brantsch KD, Meisner C, Schonfisch B, et al. Analysis of risk factors determining prognosis of cutaneous squamous-cell carcinoma: a prospective study. *Lancet Oncol* 2008;9:713-720. Available at: <http://www.ncbi.nlm.nih.gov/pubmed/18617440>.

75. Jambusaria-Pahlajani A, Kanetsky PA, Karia PS, et al. Evaluation of AJCC tumor staging for cutaneous squamous cell carcinoma and a proposed alternative tumor staging system. *JAMA Dermatol* 2013;149:402-410. Available at: <http://www.ncbi.nlm.nih.gov/pubmed/23325457>.

76. Schmidt C, Martin JM, Khoo E, et al. Outcomes of nodal metastatic cutaneous squamous cell carcinoma of the head and neck treated in a regional center. *Head Neck* 2015;37:1808-1815. Available at: <https://www.ncbi.nlm.nih.gov/pubmed/24995842>.

77. Shao A, Wong DK, Mclvor NP, et al. Parotid metastatic disease from cutaneous squamous cell carcinoma: prognostic role of facial nerve sacrifice, lateral temporal bone resection, immune status and P-stage.



# NCCN Guidelines Version 1.2024

## Squamous Cell Skin Cancer

Head Neck 2014;36:545-550. Available at:

<https://www.ncbi.nlm.nih.gov/pubmed/23780509>.

78. Manyam BV, Gastman B, Zhang AY, et al. Inferior outcomes in immunosuppressed patients with high-risk cutaneous squamous cell carcinoma of the head and neck treated with surgery and radiation therapy. *J Am Acad Dermatol* 2015;73:221-227. Available at:

<https://www.ncbi.nlm.nih.gov/pubmed/26028524>.

79. Lott DG, Manz R, Koch C, Lorenz RR. Aggressive behavior of nonmelanotic skin cancers in solid organ transplant recipients.

*Transplantation* 2010;90:683-687. Available at:

<http://www.ncbi.nlm.nih.gov/pubmed/20808266>.

80. Manyam BV, Garsa AA, Chin RI, et al. A multi-institutional comparison of outcomes of immunosuppressed and immunocompetent patients treated with surgery and radiation therapy for cutaneous squamous cell carcinoma of the head and neck. *Cancer* 2017;123:2054-2060. Available at: <https://www.ncbi.nlm.nih.gov/pubmed/28171708>.

81. Levine DE, Karia PS, Schmults CD. Outcomes of Patients With Multiple Cutaneous Squamous Cell Carcinomas: A 10-Year Single-Institution Cohort Study. *JAMA Dermatol* 2015;151:1220-1225. Available at: <http://www.ncbi.nlm.nih.gov/pubmed/26177278>.

82. Hortlund M, Arroyo Muhr LS, Storm H, et al. Cancer risks after solid organ transplantation and after long-term dialysis. *Int J Cancer* 2017;140:1091-1101. Available at:

<https://www.ncbi.nlm.nih.gov/pubmed/27870055>.

83. Clowry J, Sheridan J, Healy R, et al. Increased non-melanoma skin cancer risk in young patients with inflammatory bowel disease on immunomodulatory therapy: a retrospective single-centre cohort study. *J Eur Acad Dermatol Venereol* 2017;31:978-985. Available at:

<https://www.ncbi.nlm.nih.gov/pubmed/28045204>.

84. Thielmann HW, Popanda O, Edler L, Jung EG. Clinical symptoms and DNA repair characteristics of xeroderma pigmentosum patients from

Germany. *Cancer Res* 1991;51:3456-3470. Available at:

<http://www.ncbi.nlm.nih.gov/pubmed/2054785>.

85. Miller KL, Karagas MR, Kraft P, et al. XPA, haplotypes, and risk of basal and squamous cell carcinoma. *Carcinogenesis* 2006;27:1670-1675. Available at: <http://www.ncbi.nlm.nih.gov/pubmed/16513681>.

86. Sibar S, Findikcioglu K, Erdal AI, et al. Technical Aspects and Difficulties in the Management of Head and Neck Cutaneous Malignancies in Xeroderma Pigmentosum. *Arch Plast Surg* 2016;43:344-351. Available at: <https://www.ncbi.nlm.nih.gov/pubmed/27462567>.

87. Chen J, Ruczinski I, Jorgensen TJ, et al. Nonmelanoma skin cancer and risk for subsequent malignancy. *J Natl Cancer Inst* 2008;100:1215-1222. Available at: <http://www.ncbi.nlm.nih.gov/pubmed/18728282>.

88. Banan P, Marvi SK, McMeniman E, De'Ambrosis B. An Australian cohort of 210 patients with multiple invasive squamous cell carcinomas: risk factors and associated increased risk of melanoma and internal malignancies. *Australas J Dermatol* 2016;57:29-32. Available at: <https://www.ncbi.nlm.nih.gov/pubmed/25970074>.

89. Maloney ME, Miller SJ. Aggressive vs nonaggressive subtypes (basal cell carcinoma). In: Miller SJ, Maloney ME, eds. *Cutaneous Oncology Pathophysiology, diagnosis, and management*. Malden, MA: Blackwell Science; 1998:609-613.

90. Salasche SJ. Features associated with recurrence (squamous cell carcinoma). In: Miller SJ, Maloney ME, eds. *Cutaneous Oncology Pathophysiology, diagnosis, and management*. Malden, MA: Blackwell Science; 1998:494-499.

91. Akay BN, Saral S, Heper AO, et al. Basosquamous carcinoma: Dermoscopic clues to diagnosis. *J Dermatol* 2017;44:127-134. Available at: <https://www.ncbi.nlm.nih.gov/pubmed/27570202>.

92. Wermker K, Roknic N, Goessling K, et al. Basosquamous carcinoma of the head and neck: clinical and histologic characteristics and their





# NCCN Guidelines Version 1.2024

## Squamous Cell Skin Cancer

impact on disease progression. *Neoplasia* 2015;17:301-305. Available at: <https://www.ncbi.nlm.nih.gov/pubmed/25810014>.

93. Tan CZ, Rieger KE, Sarin KY. Basosquamous Carcinoma: Controversy, Advances, and Future Directions. *Dermatol Surg* 2017;43:23-31. Available at: <https://www.ncbi.nlm.nih.gov/pubmed/27340741>.

94. Marrazzo G, Thorpe R, Condie D, et al. Clinical and Pathologic Factors Predictive of Positive Radiologic Findings in High-Risk Cutaneous Squamous Cell Carcinoma. *Dermatol Surg* 2015;41:1405-1410. Available at: <http://www.ncbi.nlm.nih.gov/pubmed/26517320>.

95. Ruiz ES, Karia PS, Morgan FC, Schmults CD. The positive impact of radiologic imaging on high-stage cutaneous squamous cell carcinoma management. *J Am Acad Dermatol* 2017;76:217-225. Available at: <https://www.ncbi.nlm.nih.gov/pubmed/27707594>.

96. Gandhi MR, Panizza B, Kennedy D. Detecting and defining the anatomic extent of large nerve perineural spread of malignancy: comparing "targeted" MRI with the histologic findings following surgery. *Head Neck* 2011;33:469-475. Available at: <http://www.ncbi.nlm.nih.gov/pubmed/20645285>.

97. Williams LS, Mancuso AA, Mendenhall WM. Perineural spread of cutaneous squamous and basal cell carcinoma: CT and MR detection and its impact on patient management and prognosis. *Int J Radiat Oncol Biol Phys* 2001;49:1061-1069. Available at: <http://www.ncbi.nlm.nih.gov/pubmed/11240248>.

98. Nemzek WR, Hecht S, Gandour-Edwards R, et al. Perineural spread of head and neck tumors: how accurate is MR imaging? *AJNR Am J Neuroradiol* 1998;19:701-706. Available at: <http://www.ncbi.nlm.nih.gov/pubmed/9576658>.

99. Karia PS, Jambusaria-Pahlajani A, Harrington DP, et al. Evaluation of American Joint Committee on Cancer, International Union Against Cancer, and Brigham and Women's Hospital tumor staging for cutaneous

squamous cell carcinoma. *J Clin Oncol* 2014;32:327-334. Available at: <https://www.ncbi.nlm.nih.gov/pubmed/24366933>.

100. Schmitt AR, Brewer JD, Bordeaux JS, Baum CL. Staging for cutaneous squamous cell carcinoma as a predictor of sentinel lymph node biopsy results: meta-analysis of American Joint Committee on Cancer criteria and a proposed alternative system. *JAMA Dermatol* 2014;150:19-24. Available at: <http://www.ncbi.nlm.nih.gov/pubmed/24226651>.

101. Gonzalez JL, Cunningham K, Silverman R, et al. Comparison of the American Joint Committee on Cancer Seventh Edition and Brigham and Women's Hospital Cutaneous Squamous Cell Carcinoma Tumor Staging in Immunosuppressed Patients. *Dermatol Surg* 2017;43:784-791. Available at: <https://www.ncbi.nlm.nih.gov/pubmed/28079640>.

102. Roozeboom MH, Lohman BG, Westers-Attema A, et al. Clinical and histological prognostic factors for local recurrence and metastasis of cutaneous squamous cell carcinoma: analysis of a defined population. *Acta Derm Venereol* 2013;93:417-421. Available at: <https://www.ncbi.nlm.nih.gov/pubmed/23138613>.

103. Carter JB, Johnson MM, Chua TL, et al. Outcomes of primary cutaneous squamous cell carcinoma with perineural invasion: an 11-year cohort study. *JAMA Dermatol* 2013;149:35-41. Available at: <http://www.ncbi.nlm.nih.gov/pubmed/23324754>.

104. Ruiz ES, Karia PS, Besaw R, Schmults CD. Performance of the American Joint Committee on Cancer Staging Manual, 8th Edition vs the Brigham and Women's Hospital Tumor Classification System for Cutaneous Squamous Cell Carcinoma. *JAMA Dermatol* 2019. Available at: <https://www.ncbi.nlm.nih.gov/pubmed/30969315>.

105. Karia PS, Morgan FC, Califano JA, Schmults CD. Comparison of Tumor Classifications for Cutaneous Squamous Cell Carcinoma of the Head and Neck in the 7th vs 8th Edition of the AJCC Cancer Staging Manual. *JAMA Dermatol* 2018;154:175-181. Available at: <https://www.ncbi.nlm.nih.gov/pubmed/29261835>.



# NCCN Guidelines Version 1.2024

## Squamous Cell Skin Cancer

106. Brougham ND, Dennett ER, Cameron R, Tan ST. The incidence of metastasis from cutaneous squamous cell carcinoma and the impact of its risk factors. *J Surg Oncol* 2012;106:811-815. Available at: <https://www.ncbi.nlm.nih.gov/pubmed/22592943>.

107. Harris BN, Bayoumi A, Rao S, et al. Factors Associated with Recurrence and Regional Adenopathy for Head and Neck Cutaneous Squamous Cell Carcinoma. *Otolaryngol Head Neck Surg* 2017;156:863-869. Available at: <https://www.ncbi.nlm.nih.gov/pubmed/28322123>.

108. Hollestein LM, de Vries E, Nijsten T. Trends of cutaneous squamous cell carcinoma in the Netherlands: increased incidence rates, but stable relative survival and mortality 1989-2008. *Eur J Cancer* 2012;48:2046-2053. Available at: <https://www.ncbi.nlm.nih.gov/pubmed/22342554>.

109. Haisma MS, Plaat BE, Bijl HP, et al. Multivariate analysis of potential risk factors for lymph node metastasis in patients with cutaneous squamous cell carcinoma of the head and neck. *J Am Acad Dermatol* 2016;75:722-730. Available at: <https://www.ncbi.nlm.nih.gov/pubmed/27473455>.

110. Ross AS, Schmults CD. Sentinel lymph node biopsy in cutaneous squamous cell carcinoma: a systematic review of the English literature. *Dermatol Surg* 2006;32:1309-1321. Available at: <http://www.ncbi.nlm.nih.gov/pubmed/17083582>.

111. Lewis KG, Weinstock MA. Nonmelanoma skin cancer mortality (1988-2000): the Rhode Island follow-back study. *Arch Dermatol* 2004;140:837-842. Available at: <http://www.ncbi.nlm.nih.gov/pubmed/15262694>.

112. Clayman GL, Lee JJ, Holsinger FC, et al. Mortality risk from squamous cell skin cancer. *J Clin Oncol* 2005;23:759-765. Available at: <http://www.ncbi.nlm.nih.gov/pubmed/15681519>.

113. Quaedvlieg PJ, Creytens DH, Epping GG, et al. Histopathological characteristics of metastasizing squamous cell carcinoma of the skin and

lips. *Histopathology* 2006;49:256-264. Available at: <https://www.ncbi.nlm.nih.gov/pubmed/16918972>.

114. Cherpelis BS, Marcusen C, Lang PG. Prognostic factors for metastasis in squamous cell carcinoma of the skin. *Dermatol Surg* 2002;28:268-273. Available at: <http://www.ncbi.nlm.nih.gov/pubmed/11896781>.

115. Maciburko SJ, Townley WA, Hollowood K, Giele HP. Skin cancers of the hand: a series of 541 malignancies. *Plast Reconstr Surg* 2012;129:1329-1336. Available at: <https://www.ncbi.nlm.nih.gov/pubmed/22327895>.

116. Moore BA, Weber RS, Prieto V, et al. Lymph node metastases from cutaneous squamous cell carcinoma of the head and neck. *Laryngoscope* 2005;115:1561-1567. Available at: <http://www.ncbi.nlm.nih.gov/pubmed/16148695>.

117. Dixon AY, Lee SH, McGregor DH. Histologic features predictive of basal cell carcinoma recurrence: results of a multivariate analysis. *J Cutan Pathol* 1993;20:137-142. Available at: <http://www.ncbi.nlm.nih.gov/pubmed/8320358>.

118. Jacobs GH, Rippey JJ, Altini M. Prediction of aggressive behavior in basal cell carcinoma. *Cancer* 1982;49:533-537. Available at: <http://www.ncbi.nlm.nih.gov/pubmed/7059912>.

119. de Rosa G, Vetrani A, Zeppa P, et al. Comparative morphometric analysis of aggressive and ordinary basal cell carcinoma of the skin. *Cancer* 1990;65:544-549. Available at: <http://www.ncbi.nlm.nih.gov/pubmed/2297645>.

120. de Lima Vazquez V, Sachetto T, Perpetuo NM, Carvalho AL. Prognostic factors for lymph node metastasis from advanced squamous cell carcinoma of the skin of the trunk and extremities. *World J Surg Oncol* 2008;6:73. Available at: <https://www.ncbi.nlm.nih.gov/pubmed/18601735>.



# NCCN Guidelines Version 1.2024

## Squamous Cell Skin Cancer

121. Wermker K, Kluwig J, Schipmann S, et al. Prediction score for lymph node metastasis from cutaneous squamous cell carcinoma of the external ear. *Eur J Surg Oncol* 2015;41:128-135. Available at: <https://www.ncbi.nlm.nih.gov/pubmed/25182221>.

122. Tam S, Yao C, Amit M, et al. Association of Immunosuppression With Outcomes of Patients With Cutaneous Squamous Cell Carcinoma of the Head and Neck. *JAMA Otolaryngol Head Neck Surg* 2020;146:128-135. Available at: <https://www.ncbi.nlm.nih.gov/pubmed/31804658>.

123. Harwood CA, Proby CM, McGregor JM, et al. Clinicopathologic features of skin cancer in organ transplant recipients: a retrospective case-control series. *J Am Acad Dermatol* 2006;54:290-300. Available at: <http://www.ncbi.nlm.nih.gov/pubmed/16443060>.

124. Rabinovics N, Mizrahi A, Hadar T, et al. Cancer of the head and neck region in solid organ transplant recipients. *Head Neck* 2014;36:181-186. Available at: <http://www.ncbi.nlm.nih.gov/pubmed/23554129>.

125. Goldenberg A, Ortiz A, Kim SS, Jiang SB. Squamous cell carcinoma with aggressive subclinical extension: 5-year retrospective review of diagnostic predictors. *J Am Acad Dermatol* 2015;73:120-126. Available at: <http://www.ncbi.nlm.nih.gov/pubmed/25840729>.

126. Edwards MJ, Hirsch RM, Broadwater JR, et al. Squamous cell carcinoma arising in previously burned or irradiated skin. *Arch Surg* 1989;124:115-117. Available at: <http://www.ncbi.nlm.nih.gov/pubmed/2910238>.

127. Gul U, Kilic A. Squamous cell carcinoma developing on burn scar. *Ann Plast Surg* 2006;56:406-408. Available at: <http://www.ncbi.nlm.nih.gov/pubmed/16557073>.

128. Kowal-Vern A, Criswell BK. Burn scar neoplasms: a literature review and statistical analysis. *Burns* 2005;31:403-413. Available at: <http://www.ncbi.nlm.nih.gov/pubmed/15896501>.

129. Kyrgidis A, Tzellos TG, Kechagias N, et al. Cutaneous squamous cell carcinoma (SCC) of the head and neck: risk factors of overall and recurrence-free survival. *Eur J Cancer* 2010;46:1563-1572. Available at: <http://www.ncbi.nlm.nih.gov/pubmed/20338745>.

130. Endo Y, Tanioka M, Miyachi Y. Prognostic factors in cutaneous squamous cell carcinoma: is patient delay in hospital visit a predictor of survival? *ISRN Dermatol* 2011;2011:285289. Available at: <https://www.ncbi.nlm.nih.gov/pubmed/22363846>.

131. Canueto J, Martin-Vallejo J, Cardenoso-Alvarez E, et al. Rapid growth rate is associated with poor prognosis in cutaneous squamous cell carcinoma. *Clin Exp Dermatol* 2018;43:876-882. Available at: <https://www.ncbi.nlm.nih.gov/pubmed/29756221>.

132. Nguyen P, Vin-Christian K, Ming ME, Berger T. Aggressive squamous cell carcinomas in persons infected with the human immunodeficiency virus. *Arch Dermatol* 2002;138:758-763. Available at: <https://pubmed.ncbi.nlm.nih.gov/12056956/>.

133. Winkelhorst JT, Brokelman WJ, Tiggeler RG, Wobbes T. Incidence and clinical course of de-novo malignancies in renal allograft recipients. *Eur J Surg Oncol* 2001;27:409-413. Available at: <https://www.ncbi.nlm.nih.gov/pubmed/11417989>.

134. Han A, Ratner D. What is the role of adjuvant radiotherapy in the treatment of cutaneous squamous cell carcinoma with perineural invasion? *Cancer* 2007;109:1053-1059. Available at: <http://www.ncbi.nlm.nih.gov/pubmed/17279578>.

135. Galloway TJ, Morris CG, Mancuso AA, et al. Impact of radiographic findings on prognosis for skin carcinoma with clinical perineural invasion. *Cancer* 2005;103:1254-1257. Available at: <http://www.ncbi.nlm.nih.gov/pubmed/15693020>.

136. Goepfert H, Dichtel WJ, Medina JE, et al. Perineural invasion in squamous cell skin carcinoma of the head and neck. *Am J Surg* 1984;148:542-547. Available at: <http://www.ncbi.nlm.nih.gov/pubmed/6486325>.





# NCCN Guidelines Version 1.2024

## Squamous Cell Skin Cancer

137. Durham AB, Lowe L, Malloy KM, et al. Sentinel Lymph Node Biopsy for Cutaneous Squamous Cell Carcinoma on the Head and Neck. *JAMA Otolaryngol Head Neck Surg* 2016;142:1171-1176. Available at: <https://www.ncbi.nlm.nih.gov/pubmed/27438434>.

138. Gore SM, Shaw D, Martin RC, et al. Prospective study of sentinel node biopsy for high-risk cutaneous squamous cell carcinoma of the head and neck. *Head Neck* 2016;38 Suppl 1:E884-889. Available at: <https://www.ncbi.nlm.nih.gov/pubmed/25965008>.

139. Sapir E, Tolpadi A, McHugh J, et al. Skin cancer of the head and neck with gross or microscopic perineural involvement: Patterns of failure. *Radiother Oncol* 2016;120:81-86. Available at: <https://www.ncbi.nlm.nih.gov/pubmed/27475277>.

140. Lin C, Tripcony L, Keller J, et al. Perineural infiltration of cutaneous squamous cell carcinoma and basal cell carcinoma without clinical features. *Int J Radiat Oncol Biol Phys* 2012;82:334-340. Available at: <http://www.ncbi.nlm.nih.gov/pubmed/21093171>.

141. Jackson JE, Dickie GJ, Wiltshire KL, et al. Radiotherapy for perineural invasion in cutaneous head and neck carcinomas: toward a risk-adapted treatment approach. *Head Neck* 2009;31:604-610. Available at: <http://www.ncbi.nlm.nih.gov/pubmed/19132719>.

142. Warren TA, Panizza B, Porceddu SV, et al. Outcomes after surgery and postoperative radiotherapy for perineural spread of head and neck cutaneous squamous cell carcinoma. *Head Neck* 2016;38:824-831. Available at: <https://www.ncbi.nlm.nih.gov/pubmed/25546817>.

143. Farasat S, Yu SS, Neel VA, et al. A new American Joint Committee on Cancer staging system for cutaneous squamous cell carcinoma: Creation and rationale for inclusion of tumor (T) characteristics. *J Am Acad Dermatol* 2011;64:1051-1059. Available at: <http://www.ncbi.nlm.nih.gov/pubmed/21255868>.

144. Brinkman JN, Hajder E, van der Holt B, et al. The Effect of Differentiation Grade of Cutaneous Squamous Cell Carcinoma on Excision Margins, Local Recurrence, Metastasis, and Patient Survival: A

Retrospective Follow-Up Study. *Ann Plast Surg* 2015;75:323-326. Available at: <https://www.ncbi.nlm.nih.gov/pubmed/24401812>.

145. Cassarino DS, Derienzo DP, Barr RJ. Cutaneous squamous cell carcinoma: a comprehensive clinicopathologic classification--part two. *J Cutan Pathol* 2006;33:261-279. Available at: <http://www.ncbi.nlm.nih.gov/pubmed/16630176>.

146. Banks ER, Cooper PH. Adenosquamous carcinoma of the skin: a report of 10 cases. *J Cutan Pathol* 1991;18:227-234. Available at: <http://www.ncbi.nlm.nih.gov/pubmed/1719048>.

147. Nappi O, Pettinato G, Wick MR. Adenoid (acantholytic) squamous cell carcinoma of the skin. *J Cutan Pathol* 1989;16:114-121. Available at: <http://www.ncbi.nlm.nih.gov/pubmed/2768593>.

148. Patel NK, McKee PH, Smith NP, Fletcher CD. Primary metaplastic carcinoma (carcinosarcoma) of the skin. A clinicopathologic study of four cases and review of the literature. *Am J Dermatopathol* 1997;19:363-372. Available at: <https://www.ncbi.nlm.nih.gov/pubmed/9261471>.

149. Ogawa T, Kiuru M, Konia TH, Fung MA. Acantholytic squamous cell carcinoma is usually associated with hair follicles, not acantholytic actinic keratosis, and is not "high risk": Diagnosis, management, and clinical outcomes in a series of 115 cases. *J Am Acad Dermatol* 2017;76:327-333. Available at: <https://www.ncbi.nlm.nih.gov/pubmed/27889291>.

150. Garcia C, Crowson AN. Acantholytic squamous cell carcinoma: is it really a more-aggressive tumor? *Dermatol Surg* 2011;37:353-356. Available at: <https://www.ncbi.nlm.nih.gov/pubmed/21410819>.

151. Patel V, Squires SM, Liu DY, Fraga GR. Cutaneous adenosquamous carcinoma: a rare neoplasm with biphasic differentiation. *Cutis* 2014;94:231-233. Available at: <https://www.ncbi.nlm.nih.gov/pubmed/25474451>.

152. Breuninger H, Schaumburg-Lever G, Holzschuh J, Horny HP. Desmoplastic squamous cell carcinoma of skin and vermilion surface: a



# NCCN Guidelines Version 1.2024

## Squamous Cell Skin Cancer

highly malignant subtype of skin cancer. *Cancer* 1997;79:915-919. Available at: <https://www.ncbi.nlm.nih.gov/pubmed/9041153>.

153. Salmon PJ, Hussain W, Geisse JK, et al. Sclerosing squamous cell carcinoma of the skin, an underemphasized locally aggressive variant: a 20-year experience. *Dermatol Surg* 2011;37:664-670. Available at: <http://www.ncbi.nlm.nih.gov/pubmed/21269350>.

154. Griffiths RW, Feeley K, Suvarna SK. Audit of clinical and histological prognostic factors in primary invasive squamous cell carcinoma of the skin: assessment in a minimum 5 year follow-up study after conventional excisional surgery. *Br J Plast Surg* 2002;55:287-292. Available at: <http://www.ncbi.nlm.nih.gov/pubmed/12160533>.

155. College of American Pathologists. Protocol for the Examination of Specimens from Patients with Squamous Cell Carcinoma of the Skin. 2013. Available at: <http://www.cap.org/ShowProperty?nodePath=/UCMCon/Contribution%20Folders/WebContent/pdf/skinsquamous-13protocol-3102.pdf>. Accessed May 12, 2017.

156. Amin MB, Edge S, Greene F, et al., eds. *AJCC Cancer Staging Manual* (ed 8th). New York: Springer International Publishing; 2017.

157. Garcia-Serra A, Hinerman RW, Mendenhall WM, et al. Carcinoma of the skin with perineural invasion. *Head Neck* 2003;25:1027-1033. Available at: <http://www.ncbi.nlm.nih.gov/pubmed/14648861>.

158. Lin C, Tripcony L, Keller J, et al. Cutaneous carcinoma of the head and neck with clinical features of perineural infiltration treated with radiotherapy. *Clin Oncol (R Coll Radiol)* 2013;25:362-367. Available at: <http://www.ncbi.nlm.nih.gov/pubmed/23489870>.

159. Lawrence N, Cottel WI. Squamous cell carcinoma of skin with perineural invasion. *J Am Acad Dermatol* 1994;31:30-33. Available at: <https://www.ncbi.nlm.nih.gov/pubmed/8021368>.

160. Kadakia S, Ducic Y, Marra D, Saman M. The role of elective superficial parotidectomy in the treatment of temporal region squamous

cell carcinoma. *Oral Maxillofac Surg* 2016;20:143-147. Available at: <http://www.ncbi.nlm.nih.gov/pubmed/26685892>.

161. Leibovitch I, Huilgol SC, Selva D, et al. Cutaneous squamous cell carcinoma treated with Mohs micrographic surgery in Australia II. Perineural invasion. *J Am Acad Dermatol* 2005;53:261-266. Available at: <https://www.ncbi.nlm.nih.gov/pubmed/16021121>.

162. Campoli M, Brodland DG, Zitelli J. A prospective evaluation of the clinical, histologic, and therapeutic variables associated with incidental perineural invasion in cutaneous squamous cell carcinoma. *J Am Acad Dermatol* 2014;70:630-636. Available at: <https://www.ncbi.nlm.nih.gov/pubmed/24433872>.

163. Balamucki CJ, DeJesus R, Galloway TJ, et al. Impact of radiographic findings on for prognosis skin cancer with perineural invasion. *Am J Clin Oncol* 2015;38:248-251. Available at: <http://www.ncbi.nlm.nih.gov/pubmed/23648439>.

164. Lansbury L, Bath-Hextall F, Perkins W, et al. Interventions for non-metastatic squamous cell carcinoma of the skin: systematic review and pooled analysis of observational studies. *BMJ* 2013;347:f6153. Available at: <https://www.ncbi.nlm.nih.gov/pubmed/24191270>.

165. Chren MM, Linos E, Torres JS, et al. Tumor recurrence 5 years after treatment of cutaneous basal cell carcinoma and squamous cell carcinoma. *J Invest Dermatol* 2013;133:1188-1196. Available at: <http://www.ncbi.nlm.nih.gov/pubmed/23190903>.

166. Freeman RG, Knox JM, Heaton CL. The treatment of skin cancer: a statistical study of 1,341 skin tumors comparing results obtained with irradiation, surgery, and curettage followed by electrodesiccation. *Cancer* 1964;17:535-538. Available at: <http://www.ncbi.nlm.nih.gov/pubmed/14136537>.

167. Honeycutt WM, Jansen GT. Treatment of squamous cell carcinoma of the skin. *Arch Dermatol* 1973;108:670-672. Available at: <http://www.ncbi.nlm.nih.gov/pubmed/4750203>.



# NCCN Guidelines Version 1.2024

## Squamous Cell Skin Cancer

168. Shiffman NJ. Squamous cell carcinomas of the skin of the pinna. *Can J Surg* 1975;18:279-283. Available at: <http://www.ncbi.nlm.nih.gov/pubmed/1125865>.

169. Xiong DD, Beal BT, Varra V, et al. Outcomes in intermediate-risk squamous cell carcinomas treated with Mohs micrographic surgery compared with wide local excision. *J Am Acad Dermatol* 2020;82:1195-1204. Available at: <https://www.ncbi.nlm.nih.gov/pubmed/31887322>.

170. van Lee CB, Roorda BM, Wakkee M, et al. Recurrence rates of cutaneous squamous cell carcinoma of the head and neck after Mohs micrographic surgery vs. standard excision: a retrospective cohort study. *Br J Dermatol* 2018. Available at: <https://www.ncbi.nlm.nih.gov/pubmed/30199574>.

171. Turner RJ, Leonard N, Malcolm AJ, et al. A retrospective study of outcome of Mohs' micrographic surgery for cutaneous squamous cell carcinoma using formalin fixed sections. *Br J Dermatol* 2000;142:752-757. Available at: <http://www.ncbi.nlm.nih.gov/pubmed/10792227>.

172. Malhotra R, Huilgol SC, Huynh NT, Selva D. The Australian Mohs database: periocular squamous cell carcinoma. *Ophthalmology* 2004;111:617-623. Available at: <http://www.ncbi.nlm.nih.gov/pubmed/15051191>.

173. Leibovitch I, Huilgol SC, Selva D, et al. Cutaneous squamous cell carcinoma treated with Mohs micrographic surgery in Australia I. Experience over 10 years. *J Am Acad Dermatol* 2005;53:253-260. Available at: <http://www.ncbi.nlm.nih.gov/pubmed/16021120>.

174. Leibovitch I, Huilgol SC, Richards S, et al. Scalp tumors treated with Mohs micrographic surgery: clinical features and surgical outcome. *Dermatol Surg* 2006;32:1369-1374. Available at: <http://www.ncbi.nlm.nih.gov/pubmed/17083590>.

175. Silapunt S, Peterson SR, Goldberg LH. Squamous cell carcinoma of the auricle and Mohs micrographic surgery. *Dermatol Surg* 2005;31:1423-1427. Available at: <http://www.ncbi.nlm.nih.gov/pubmed/16416611>.

176. van der Eerden PA, Prins ME, Lohuis PJ, et al. Eighteen years of experience in Mohs micrographic surgery and conventional excision for nonmelanoma skin cancer treated by a single facial plastic surgeon and pathologist. *Laryngoscope* 2010;120:2378-2384. Available at: <http://www.ncbi.nlm.nih.gov/pubmed/21046543>.

177. Pugliano-Mauro M, Goldman G. Mohs surgery is effective for high-risk cutaneous squamous cell carcinoma. *Dermatol Surg* 2010;36:1544-1553. Available at: <http://www.ncbi.nlm.nih.gov/pubmed/21053415>.

178. Skaria AM. Recurrence of basosquamous carcinoma after Mohs micrographic surgery. *Dermatology* 2010;221:352-355. Available at: <http://www.ncbi.nlm.nih.gov/pubmed/20924160>.

179. Breuninger H, Schaumburg-Lever G. Control of excisional margins by conventional histopathological techniques in the treatment of skin tumours. An alternative to Mohs' technique. *J Pathol* 1988;154:167-171. Available at: <https://www.ncbi.nlm.nih.gov/pubmed/2832578>.

180. Vuyk HD, Lohuis PJ. Mohs micrographic surgery for facial skin cancer. *Clin Otolaryngol Allied Sci* 2001;26:265-273. Available at: <http://www.ncbi.nlm.nih.gov/pubmed/11559334>.

181. Mourouzis C, Boynton A, Grant J, et al. Cutaneous head and neck SCCs and risk of nodal metastasis - UK experience. *J Craniomaxillofac Surg* 2009;37:443-447. Available at: <http://www.ncbi.nlm.nih.gov/pubmed/19713116>.

182. Matsumoto A, Li JN, Matsumoto M, et al. Factors predicting outcomes of patients with high-risk squamous cell carcinoma treated with Mohs micrographic surgery. *J Am Acad Dermatol* 2021;85:588-595. Available at: <https://www.ncbi.nlm.nih.gov/pubmed/33524409>.

183. Tschetter AJ, Campoli MR, Zitelli JA, Brodland DG. Long-term clinical outcomes of patients with invasive cutaneous squamous cell carcinoma treated with Mohs micrographic surgery: A 5-year, multicenter, prospective cohort study. *J Am Acad Dermatol* 2020;82:139-148. Available at: <https://www.ncbi.nlm.nih.gov/pubmed/31279037>.





# NCCN Guidelines Version 1.2024

## Squamous Cell Skin Cancer

184. Marrazzo G, Zitelli JA, Brodland D. Clinical outcomes in high-risk squamous cell carcinoma patients treated with Mohs micrographic surgery alone. *J Am Acad Dermatol* 2019;80:633-638. Available at: <https://www.ncbi.nlm.nih.gov/pubmed/30244064>.

185. Kropp L, Balamucki CJ, Morris CG, et al. Mohs resection and postoperative radiotherapy for head and neck cancers with incidental perineural invasion. *Am J Otolaryngol* 2013;34:373-377. Available at: <http://www.ncbi.nlm.nih.gov/pubmed/23415573>.

186. Ruiz ES, Koyfman SA, Que SKT, et al. Evaluation of the utility of localized adjuvant radiation for node-negative primary cutaneous squamous cell carcinoma with clear histologic margins. *J Am Acad Dermatol* 2020;82:420-429. Available at: <https://www.ncbi.nlm.nih.gov/pubmed/31349042>.

187. Miller J, Chang T, Schwartz D, et al. Outcomes of Adjuvant Radiotherapy Following Negative Surgical Margins for Cutaneous Squamous Cell Carcinoma. *Dermatol Surg* 2019;45:1111-1116. Available at: <https://www.ncbi.nlm.nih.gov/pubmed/30893176>.

188. Koslosky CL, El Tal AK, Workman B, et al. Reliability of skin biopsies in determining accurate tumor margins: a retrospective study after Mohs micrographic surgery. *Dermatol Surg* 2014;40:964-970. Available at: <http://www.ncbi.nlm.nih.gov/pubmed/25099294>.

189. Chambers KJ, Kraft S, Emerick K. Evaluation of frozen section margins in high-risk cutaneous squamous cell carcinomas of the head and neck. *Laryngoscope* 2015;125:636-639. Available at: <https://www.ncbi.nlm.nih.gov/pubmed/25230253>.

190. Castley AJ, Theile DR, Lambie D. The use of frozen section in the excision of cutaneous malignancy: a Queensland experience. *Ann Plast Surg* 2013;71:386-389. Available at: <https://www.ncbi.nlm.nih.gov/pubmed/24025654>.

191. Massey PR, Gupta S, Rothstein BE, et al. Total Margin-Controlled Excision is Superior to Standard Excision for Keratinocyte Carcinoma on the Nose: A Veterans Affairs Nested Cohort Study. *Ann Surg Oncol*

2021;28:3656-3663. Available at: <https://www.ncbi.nlm.nih.gov/pubmed/33742233>.

192. Gayre GS, Hybarger CP, Mannor G, et al. Outcomes of excision of 1750 eyelid and periorcular skin basal cell and squamous cell carcinomas by modified en face frozen section margin-controlled technique. *Int Ophthalmol Clin* 2009;49:97-110. Available at: <https://www.ncbi.nlm.nih.gov/pubmed/20348860>.

193. de Visscher JG, Gooris PJ, Vermey A, Roodenburg JL. Surgical margins for resection of squamous cell carcinoma of the lower lip. *Int J Oral Maxillofac Surg* 2002;31:154-157. Available at: <https://www.ncbi.nlm.nih.gov/pubmed/12102412>.

194. Bogdanov-Berezovsky A, Rosenberg L, Cagniano E, Silberstein E. The role of frozen section histological analysis in the treatment of head and neck skin basal and squamous cell carcinomas. *Isr Med Assoc J* 2008;10:344-345. Available at: <https://www.ncbi.nlm.nih.gov/pubmed/18605355>.

195. Moncrieff MD, Shah AK, Igali L, Garioch JJ. False-negative rate of intraoperative frozen section margin analysis for complex head and neck nonmelanoma skin cancer excisions. *Clin Exp Dermatol* 2015;40:834-838. Available at: <http://www.ncbi.nlm.nih.gov/pubmed/26290360>.

196. Baker NJ, Webb AA, Macpherson D. Surgical management of cutaneous squamous cell carcinoma of the head and neck. *Br J Oral Maxillofac Surg* 2001;39:87-90. Available at: <http://www.ncbi.nlm.nih.gov/pubmed/11286440>.

197. Ang P, Tan AW, Goh CL. Comparison of completely versus incompletely excised cutaneous squamous cell carcinomas. *Ann Acad Med Singapore* 2004;33:68-70. Available at: <http://www.ncbi.nlm.nih.gov/pubmed/15008566>.

198. Nemet AY, Deckel Y, Martin PA, et al. Management of periorcular basal and squamous cell carcinoma: a series of 485 cases. *Am J Ophthalmol* 2006;142:293-297. Available at: <http://www.ncbi.nlm.nih.gov/pubmed/16876511>.



# NCCN Guidelines Version 1.2024

## Squamous Cell Skin Cancer

199. Seretis K, Thomaidis V, Karpouzis A, et al. Epidemiology of surgical treatment of nonmelanoma skin cancer of the head and neck in Greece. *Dermatol Surg* 2010;36:15-22. Available at: <https://www.ncbi.nlm.nih.gov/pubmed/19912277>.

200. Jenkins G, Smith AB, Kanatas AN, et al. Anatomical restrictions in the surgical excision of scalp squamous cell carcinomas: does this affect local recurrence and regional nodal metastases? *Int J Oral Maxillofac Surg* 2014;43:142-146. Available at: <https://www.ncbi.nlm.nih.gov/pubmed/24128939>.

201. Thomas SS, Matthews RN. Squamous cell carcinoma of the pinna: a 6-year study. *Br J Plast Surg* 1994;47:81-85. Available at: <http://www.ncbi.nlm.nih.gov/pubmed/8149063>.

202. Batra RS, Kelley LC. Predictors of extensive subclinical spread in nonmelanoma skin cancer treated with Mohs micrographic surgery. *Arch Dermatol* 2002;138:1043-1051. Available at: <http://www.ncbi.nlm.nih.gov/pubmed/12164742>.

203. Stewart TJ, Saunders A. Risk factors for positive margins after wide local excision of cutaneous squamous cell carcinoma. *J Dermatolog Treat* 2018:1-3. Available at: <https://www.ncbi.nlm.nih.gov/pubmed/29448853>.

204. Genders RE, Marsidi N, Michi M, et al. Incomplete Excision of Cutaneous Squamous Cell Carcinoma; Systematic Review of the Literature. *Acta Derm Venereol* 2020;100:adv00084. Available at: <https://www.ncbi.nlm.nih.gov/pubmed/32128598>.

205. Bogdanov-Berezovsky A, Cohen AD, Glesinger R, et al. Risk factors for incomplete excision of squamous cell carcinomas. *J Dermatolog Treat* 2005;16:341-344. Available at: <https://www.ncbi.nlm.nih.gov/pubmed/16428157>.

206. Tan PY, Ek E, Su S, et al. Incomplete excision of squamous cell carcinoma of the skin: a prospective observational study. *Plast Reconstr Surg* 2007;120:910-916. Available at: <https://www.ncbi.nlm.nih.gov/pubmed/17805118>.

207. Hansen C, Wilkinson D, Hansen M, Soyer HP. Factors contributing to incomplete excision of nonmelanoma skin cancer by Australian general practitioners. *Arch Dermatol* 2009;145:1253-1260. Available at: <https://www.ncbi.nlm.nih.gov/pubmed/19917954>.

208. Mirshams M, Razzaghi M, Noormohammadpour P, et al. Incidence of incomplete excision in surgically treated cutaneous squamous cell carcinoma and identification of the related risk factors. *Acta Med Iran* 2011;49:806-809. Available at: <https://www.ncbi.nlm.nih.gov/pubmed/22174169>.

209. Khan AA, Potter M, Cubitt JJ, et al. Guidelines for the excision of cutaneous squamous cell cancers in the United Kingdom: the best cut is the deepest. *J Plast Reconstr Aesthet Surg* 2013;66:467-471. Available at: <https://www.ncbi.nlm.nih.gov/pubmed/23352886>.

210. Carducci M, Bozzetti M, de Marco G, et al. Preoperative margin detection by digital dermoscopy in the traditional surgical excision of cutaneous squamous cell carcinomas. *J Dermatolog Treat* 2013;24:221-226. Available at: <https://www.ncbi.nlm.nih.gov/pubmed/22390630>.

211. Ribero S, Osella Abate S, Di Capua C, et al. Squamocellular Carcinoma of the Skin: Clinicopathological Features Predicting the Involvement of the Surgical Margins and Review of the Literature. *Dermatology* 2016;232:279-284. Available at: <https://www.ncbi.nlm.nih.gov/pubmed/27028227>.

212. Riml S, Larcher L, Kompatscher P. Complete excision of nonmelanotic skin cancer: a matter of surgical experience. *Ann Plast Surg* 2013;70:66-69. Available at: <https://www.ncbi.nlm.nih.gov/pubmed/21712697>.

213. Brodland DG, Zitelli JA. Surgical margins for excision of primary cutaneous squamous cell carcinoma. *J Am Acad Dermatol* 1992;27:241-248. Available at: <http://www.ncbi.nlm.nih.gov/pubmed/1430364>.

214. Schell AE, Russell MA, Park SS. Suggested excisional margins for cutaneous malignant lesions based on Mohs micrographic surgery.





# NCCN Guidelines Version 1.2024

## Squamous Cell Skin Cancer

JAMA Facial Plast Surg 2013;15:337-343. Available at:  
<https://www.ncbi.nlm.nih.gov/pubmed/23744451>.

215. Stratigos AJ, Garbe C, Dessinioti C, et al. European interdisciplinary guideline on invasive squamous cell carcinoma of the skin: Part 1. epidemiology, diagnostics and prevention. Eur J Cancer 2020;128:60-82. Available at: <https://www.ncbi.nlm.nih.gov/pubmed/32113941>.

216. Stratigos AJ, Garbe C, Dessinioti C, et al. European interdisciplinary guideline on invasive squamous cell carcinoma of the skin: Part 2. Treatment. Eur J Cancer 2020;128:83-102. Available at: <https://www.ncbi.nlm.nih.gov/pubmed/32113942>.

217. Keohane SG, Botting J, Budny PG, et al. British Association of Dermatologists guidelines for the management of people with cutaneous squamous cell carcinoma 2020\*. British Journal of Dermatology 2021;184:401-414. Available at: <https://onlinelibrary.wiley.com/doi/abs/10.1111/bjd.19621>.

218. Newlands C, Currie R, Memon A, et al. Non-melanoma skin cancer: United Kingdom National Multidisciplinary Guidelines. J Laryngol Otol 2016;130:S125-S132. Available at: <https://www.ncbi.nlm.nih.gov/pubmed/27841126>.

219. Bovill ES, Cullen KW, Barrett W, Banwell PE. Clinical and histological findings in re-excision of incompletely excised cutaneous squamous cell carcinoma. J Plast Reconstr Aesthet Surg 2009;62:457-461. Available at: <https://www.ncbi.nlm.nih.gov/pubmed/18218349>.

220. Yuan Y, Duff ML, Sammons DL, Wu S. Retrospective chart review of skin cancer presence in the wide excisions. World J Clin Cases 2014;2:52-56. Available at: <http://www.ncbi.nlm.nih.gov/pubmed/24653985>.

221. Stewart CM, Garlick J, McMullin J, et al. Surgical Excision of Non-Melanoma Skin Cancer in an Elderly Veteran's Affairs Population. Plast Reconstr Surg Glob Open 2014;2:e277. Available at: <https://www.ncbi.nlm.nih.gov/pubmed/25587511>.

222. Abbatucci JS, Boulier N, Laforge T, Lozier JC. Radiation therapy of skin carcinomas: results of a hypofractionated irradiation schedule in 675 cases followed more than 2 years. Radiother Oncol 1989;14:113-119. Available at: <https://www.ncbi.nlm.nih.gov/pubmed/2710943>.

223. Kwan W, Wilson D, Moravan V. Radiotherapy for locally advanced basal cell and squamous cell carcinomas of the skin. Int J Radiat Oncol Biol Phys 2004;60:406-411. Available at: <https://www.ncbi.nlm.nih.gov/pubmed/15380573>.

224. Hernandez-Machin B, Borrego L, Gil-Garcia M, Hernandez BH. Office-based radiation therapy for cutaneous carcinoma: evaluation of 710 treatments. Int J Dermatol 2007;46:453-459. Available at: <http://www.ncbi.nlm.nih.gov/pubmed/17472670>.

225. Barysch MJ, Eggmann N, Beyeler M, et al. Long-term recurrence rate of large and difficult to treat cutaneous squamous cell carcinomas after superficial radiotherapy. Dermatology 2012;224:59-65. Available at: <https://www.ncbi.nlm.nih.gov/pubmed/22433440>.

226. Cognetta AB, Howard BM, Heaton HP, et al. Superficial x-ray in the treatment of basal and squamous cell carcinomas: a viable option in select patients. J Am Acad Dermatol 2012;67:1235-1241. Available at: <http://www.ncbi.nlm.nih.gov/pubmed/22818756>.

227. Schulte KW, Lippold A, Auras C, et al. Soft x-ray therapy for cutaneous basal cell and squamous cell carcinomas. J Am Acad Dermatol 2005;53:993-1001. Available at: <http://www.ncbi.nlm.nih.gov/pubmed/16310060>.

228. Krausz AE, Ji-Xu A, Smile T, et al. A Systematic Review of Primary, Adjuvant, and Salvage Radiation Therapy for Cutaneous Squamous Cell Carcinoma. Dermatol Surg 2021;47:587-592. Available at: <https://www.ncbi.nlm.nih.gov/pubmed/33577212>.

229. Lovett RD, Perez CA, Shapiro SJ, Garcia DM. External irradiation of epithelial skin cancer. Int J Radiat Oncol Biol Phys 1990;19:235-242. Available at: <http://www.ncbi.nlm.nih.gov/pubmed/2394605>.



# NCCN Guidelines Version 1.2024

## Squamous Cell Skin Cancer

230. Cox NH, Dyson P. Wound healing on the lower leg after radiotherapy or cryotherapy of Bowen's disease and other malignant skin lesions. *Br J Dermatol* 1995;133:60-65. Available at: <https://www.ncbi.nlm.nih.gov/pubmed/7669642>.

231. Dupree MT, Kiteley RA, Weismantle K, et al. Radiation therapy for Bowen's disease: lessons for lesions of the lower extremity. *J Am Acad Dermatol* 2001;45:401-404. Available at: <https://www.ncbi.nlm.nih.gov/pubmed/11511838>.

232. Lukas VanderSpek LA, Pond GR, Wells W, Tsang RW. Radiation therapy for Bowen's disease of the skin. *Int J Radiat Oncol Biol Phys* 2005;63:505-510. Available at: <http://www.ncbi.nlm.nih.gov/pubmed/16168842>.

233. Herman JM, Pierce LJ, Sandler HM, et al. Radiotherapy using a water bath in the treatment of Bowen's disease of the digit. *Radiother Oncol* 2008;88:398-402. Available at: <https://www.ncbi.nlm.nih.gov/pubmed/18571754>.

234. Najim M, Cross S, Gebiski V, et al. Early-stage squamous cell carcinoma of the lip: the Australian experience and the benefits of radiotherapy in improving outcome in high-risk patients after resection. *Head Neck* 2013;35:1426-1430. Available at: <https://www.ncbi.nlm.nih.gov/pubmed/22965889>.

235. Babington S, Veness MJ, Cakir B, et al. Squamous cell carcinoma of the lip: is there a role for adjuvant radiotherapy in improving local control following incomplete or inadequate excision? *ANZ J Surg* 2003;73:621-625. Available at: <https://www.ncbi.nlm.nih.gov/pubmed/12887533>.

236. Raza SM, Ramakrishna R, Weber RS, et al. Nonmelanoma cutaneous cancers involving the skull base: outcomes of aggressive multimodal management. *J Neurosurg* 2015;1-8. Available at: <http://www.ncbi.nlm.nih.gov/pubmed/25909577>.

237. Harris BN, Pipkorn P, Nguyen KNB, et al. Association of Adjuvant Radiation Therapy With Survival in Patients With Advanced Cutaneous

Squamous Cell Carcinoma of the Head and Neck. *JAMA Otolaryngol Head Neck Surg* 2018. Available at: <https://www.ncbi.nlm.nih.gov/pubmed/30570645>.

238. Canueto J, Jaka A, Corchete LA, et al. Postoperative radiotherapy provides better local control and long-term outcome in selective cases of cutaneous squamous cell carcinoma with perineural invasion. *J Eur Acad Dermatol Venereol* 2020;34:1080-1091. Available at: <https://www.ncbi.nlm.nih.gov/pubmed/31587379>.

239. Zhang J, Wang Y, Wijaya WA, et al. Efficacy and prognostic factors of adjuvant radiotherapy for cutaneous squamous cell carcinoma: A systematic review and meta-analysis. *J Eur Acad Dermatol Venereol* 2021;35:1777-1787. Available at: <https://www.ncbi.nlm.nih.gov/pubmed/33930213>.

240. Ruiz ES, Kus KJB, Smile TD, et al. Adjuvant radiation following clear margin resection of high T-stage cutaneous squamous cell carcinoma halves the risk of local and locoregional recurrence: A dual center retrospective study. *J Am Acad Dermatol* 2022. Available at: <https://www.ncbi.nlm.nih.gov/pubmed/35364211>.

241. Jambusaria-Pahlajani A, Miller CJ, Quon H, et al. Surgical monotherapy versus surgery plus adjuvant radiotherapy in high-risk cutaneous squamous cell carcinoma: a systematic review of outcomes. *Dermatol Surg* 2009;35:574-585. Available at: <https://www.ncbi.nlm.nih.gov/pubmed/19415791>.

242. Kim Y, Lehrer EJ, Wirth PJ, et al. Adjuvant radiotherapy may not significantly change outcomes in high-risk cutaneous squamous cell carcinomas with clear surgical margins: A systematic review and meta-analysis. *J Am Acad Dermatol* 2021. Available at: <https://pubmed.ncbi.nlm.nih.gov/34890701/>.

243. Cotel WI. Perineural invasion by squamous-cell carcinoma. *J Dermatol Surg Oncol* 1982;8:589-600. Available at: <https://www.ncbi.nlm.nih.gov/pubmed/6749931>.



# NCCN Guidelines Version 1.2024

## Squamous Cell Skin Cancer

244. Ampil FL, Hardin JC, Peskind SP, Stucker FJ. Perineural invasion in skin cancer of the head and neck: a review of nine cases. *J Oral Maxillofac Surg* 1995;53:34-38. Available at: <https://www.ncbi.nlm.nih.gov/pubmed/7799119>.

245. Balamucki CJ, Mancuso AA, Amdur RJ, et al. Skin carcinoma of the head and neck with perineural invasion. *Am J Otolaryngol* 2012;33:447-454. Available at: <https://www.ncbi.nlm.nih.gov/pubmed/22185685>.

246. Perkins JL, Liu Y, Mitby PA, et al. Nonmelanoma skin cancer in survivors of childhood and adolescent cancer: a report from the childhood cancer survivor study. *J Clin Oncol* 2005;23:3733-3741. Available at: <http://www.ncbi.nlm.nih.gov/pubmed/15923570>.

247. Lichter MD, Karagas MR, Mott LA, et al. Therapeutic ionizing radiation and the incidence of basal cell carcinoma and squamous cell carcinoma. The New Hampshire Skin Cancer Study Group. *Arch Dermatol* 2000;136:1007-1011. Available at: <http://www.ncbi.nlm.nih.gov/pubmed/10926736>.

248. Karagas MR, Nelson HH, Zens MS, et al. Squamous cell and basal cell carcinoma of the skin in relation to radiation therapy and potential modification of risk by sun exposure. *Epidemiology* 2007;18:776-784. Available at: <https://www.ncbi.nlm.nih.gov/pubmed/17917604>.

249. Karagas MR, McDonald JA, Greenberg ER, et al. Risk of basal cell and squamous cell skin cancers after ionizing radiation therapy. For The Skin Cancer Prevention Study Group. *J Natl Cancer Inst* 1996;88:1848-1853. Available at: <http://www.ncbi.nlm.nih.gov/pubmed/8961975>.

250. Silva JJ, Tsang RW, Panzarella T, et al. Results of radiotherapy for epithelial skin cancer of the pinna: the Princess Margaret Hospital experience, 1982-1993. *Int J Radiat Oncol Biol Phys* 2000;47:451-459. Available at: <https://www.ncbi.nlm.nih.gov/pubmed/10802373>.

251. Locke J, Karimpour S, Young G, et al. Radiotherapy for epithelial skin cancer. *Int J Radiat Oncol Biol Phys* 2001;51:748-755. Available at: <https://www.ncbi.nlm.nih.gov/pubmed/11697321>.

252. Tsao MN, Tsang RW, Liu FF, et al. Radiotherapy management for squamous cell carcinoma of the nasal skin: the Princess Margaret Hospital experience. *Int J Radiat Oncol Biol Phys* 2002;52:973-979. Available at: <https://www.ncbi.nlm.nih.gov/pubmed/11958891>.

253. Evans DG, Farndon PA, Burnell LD, et al. The incidence of Gorlin syndrome in 173 consecutive cases of medulloblastoma. *Br J Cancer* 1991;64:959-961. Available at: <https://www.ncbi.nlm.nih.gov/pubmed/1931625>.

254. Stavrou T, Bromley CM, Nicholson HS, et al. Prognostic factors and secondary malignancies in childhood medulloblastoma. *J Pediatr Hematol Oncol* 2001;23:431-436. Available at: <https://www.ncbi.nlm.nih.gov/pubmed/11878577>.

255. Kimonis VE, Goldstein AM, Pastakia B, et al. Clinical manifestations in 105 persons with nevoid basal cell carcinoma syndrome. *Am J Med Genet* 1997;69:299-308. Available at: <https://www.ncbi.nlm.nih.gov/pubmed/9096761>.

256. Dinehart SM, Anthony JL, Pollack SV. Basal cell carcinoma in young patients after irradiation for childhood malignancy. *Med Pediatr Oncol* 1991;19:508-510. Available at: <https://www.ncbi.nlm.nih.gov/pubmed/1961139>.

257. Goldstein AM, Bale SJ, Peck GL, DiGiovanna JJ. Sun exposure and basal cell carcinomas in the nevoid basal cell carcinoma syndrome. *J Am Acad Dermatol* 1993;29:34-41. Available at: <https://www.ncbi.nlm.nih.gov/pubmed/8315076>.

258. Spalek M, Jonska-Gmyrek J, Galecki J. Radiation-induced morphea - a literature review. *J Eur Acad Dermatol Venereol* 2015;29:197-202. Available at: <https://www.ncbi.nlm.nih.gov/pubmed/25174551>.

259. Lin A, Abu-Isa E, Griffith KA, Ben-Josef E. Toxicity of radiotherapy in patients with collagen vascular disease. *Cancer* 2008;113:648-653. Available at: <https://www.ncbi.nlm.nih.gov/pubmed/18506734>.





# NCCN Guidelines Version 1.2024

## Squamous Cell Skin Cancer

260. Morris MM, Powell SN. Irradiation in the setting of collagen vascular disease: acute and late complications. *J Clin Oncol* 1997;15:2728-2735. Available at: <https://www.ncbi.nlm.nih.gov/pubmed/9215847>.

261. Chao CK, Gerber RM, Perez CA. Reirradiation of recurrent skin cancer of the face. A successful salvage modality. *Cancer* 1995;75:2351-2355. Available at: <http://www.ncbi.nlm.nih.gov/pubmed/7712447>.

262. Griep C, Davelaar J, Scholten AN, et al. Electron beam therapy is not inferior to superficial x-ray therapy in the treatment of skin carcinoma. *Int J Radiat Oncol Biol Phys* 1995;32:1347-1350. Available at: <https://www.ncbi.nlm.nih.gov/pubmed/7635774>.

263. McNab AA, Francis IC, Bengner R, Crompton JL. Perineural spread of cutaneous squamous cell carcinoma via the orbit. Clinical features and outcome in 21 cases. *Ophthalmology* 1997;104:1457-1462. Available at: <https://www.ncbi.nlm.nih.gov/pubmed/9307641>.

264. Gluck I, Ibrahim M, Popovtzer A, et al. Skin cancer of the head and neck with perineural invasion: defining the clinical target volumes based on the pattern of failure. *Int J Radiat Oncol Biol Phys* 2009;74:38-46. Available at: <https://www.ncbi.nlm.nih.gov/pubmed/18938044>.

265. Holmes ME, Bomford CK. The use of a short distance cobalt unit in the treatment of primary skin tumours. *Br J Radiol* 1982;55:225-228. Available at: <https://www.ncbi.nlm.nih.gov/pubmed/7066625>.

266. Caccialanza M, Piccinno R, Beretta M, Gneccchi L. Results and side effects of dermatologic radiotherapy: a retrospective study of irradiated cutaneous epithelial neoplasms. *J Am Acad Dermatol* 1999;41:589-594. Available at: <http://www.ncbi.nlm.nih.gov/pubmed/10495382>.

267. Zablow AI, Eanelli TR, Sanfilippo LJ. Electron beam therapy for skin cancer of the head and neck. *Head Neck* 1992;14:188-195. Available at: <https://www.ncbi.nlm.nih.gov/pubmed/1587735>.

268. Baris G, Visser AG, van Andel JG. The treatment of squamous cell carcinoma of the nasal vestibule with interstitial iridium implantation.

*Radiother Oncol* 1985;4:121-125. Available at: <https://www.ncbi.nlm.nih.gov/pubmed/4070678>.

269. Crook JM, Mazon JJ, Marinello G, et al. Interstitial iridium 192 for cutaneous carcinoma of the external nose. *Int J Radiat Oncol Biol Phys* 1990;18:243-248. Available at: <http://www.ncbi.nlm.nih.gov/pubmed/2298627>.

270. McCollough WM, Mendenhall NP, Parsons JT, et al. Radiotherapy alone for squamous cell carcinoma of the nasal vestibule: management of the primary site and regional lymphatics. *Int J Radiat Oncol Biol Phys* 1993;26:73-79. Available at: <https://www.ncbi.nlm.nih.gov/pubmed/8482633>.

271. Mendenhall NP, Parsons JT, Cassisi NJ, Million RR. Carcinoma of the nasal vestibule. *Int J Radiat Oncol Biol Phys* 1984;10:627-637. Available at: <https://www.ncbi.nlm.nih.gov/pubmed/6429094>.

272. Guix B, Finestres F, Tello J, et al. Treatment of skin carcinomas of the face by high-dose-rate brachytherapy and custom-made surface molds. *Int J Radiat Oncol Biol Phys* 2000;47:95-102. Available at: <http://www.ncbi.nlm.nih.gov/pubmed/10758310>.

273. Mazon JJ, Chassagne D, Crook J, et al. Radiation therapy of carcinomas of the skin of nose and nasal vestibule: a report of 1676 cases by the Groupe Europeen de Curietherapie. *Radiother Oncol* 1988;13:165-173. Available at: <http://www.ncbi.nlm.nih.gov/pubmed/3146781>.

274. Mazon JJ, Ghalie R, Zeller J, et al. Radiation therapy for carcinoma of the pinna using iridium 192 wires: a series of 70 patients. *Int J Radiat Oncol Biol Phys* 1986;12:1757-1763. Available at: <https://www.ncbi.nlm.nih.gov/pubmed/3759527>.

275. Renzi C, Caggiati A, Mannoaranparampil TJ, et al. Sentinel lymph node biopsy for high risk cutaneous squamous cell carcinoma: case series and review of the literature. *Eur J Surg Oncol* 2007;33:364-369. Available at: <https://www.ncbi.nlm.nih.gov/pubmed/17129703>.



# NCCN Guidelines Version 1.2024

## Squamous Cell Skin Cancer

276. Kwon S, Dong ZM, Wu PC. Sentinel lymph node biopsy for high-risk cutaneous squamous cell carcinoma: clinical experience and review of literature. *World J Surg Oncol* 2011;9:80. Available at: <https://www.ncbi.nlm.nih.gov/pubmed/21771334>.

277. Ahmed MM, Moore BA, Schmalbach CE. Utility of head and neck cutaneous squamous cell carcinoma sentinel node biopsy: a systematic review. *Otolaryngol Head Neck Surg* 2014;150:180-187. Available at: <http://www.ncbi.nlm.nih.gov/pubmed/24201060>.

278. Fukushima S, Masuguchi S, Igata T, et al. Evaluation of sentinel node biopsy for cutaneous squamous cell carcinoma. *J Dermatol* 2014;41:539-541. Available at: <https://www.ncbi.nlm.nih.gov/pubmed/24909214>.

279. Takahashi A, Imafuku S, Nakayama J, et al. Sentinel node biopsy for high-risk cutaneous squamous cell carcinoma. *Eur J Surg Oncol* 2014;40:1256-1262. Available at: <https://www.ncbi.nlm.nih.gov/pubmed/24953417>.

280. Maruyama H, Tanaka R, Fujisawa Y, et al. Availability of sentinel lymph node biopsy for cutaneous squamous cell carcinoma. *J Dermatol* 2017;44:431-437. Available at: <https://www.ncbi.nlm.nih.gov/pubmed/27666747>.

281. Tejera-Vaquero A, Garcia-Doval I, Lombart B, et al. Systematic review of the prevalence of nodal metastases and the prognostic utility of sentinel lymph node biopsy in cutaneous squamous cell carcinoma. *J Dermatol* 2018;45:781-790. Available at: <https://www.ncbi.nlm.nih.gov/pubmed/29701281>.

282. Renzi C, Mastroeni S, Mannooranparampil TJ, et al. Skin cancer knowledge and preventive behaviors among patients with a recent history of cutaneous squamous cell carcinoma. *Dermatology* 2008;217:74-80. Available at: <https://www.ncbi.nlm.nih.gov/pubmed/18424897>.

283. Allen JE, Stolle LB. Utility of sentinel node biopsy in patients with high-risk cutaneous squamous cell carcinoma. *Eur J Surg Oncol*

2015;41:197-200. Available at: <https://www.ncbi.nlm.nih.gov/pubmed/25468745>.

284. Cooper JS, Pajak TF, Forastiere AA, et al. Postoperative concurrent radiotherapy and chemotherapy for high-risk squamous-cell carcinoma of the head and neck. *N Engl J Med* 2004;350:1937-1944. Available at: <https://www.ncbi.nlm.nih.gov/pubmed/15128893>.

285. Bonner JA, Harari PM, Giralt J, et al. Radiotherapy plus cetuximab for squamous-cell carcinoma of the head and neck. *N Engl J Med* 2006;354:567-578. Available at: <https://www.ncbi.nlm.nih.gov/pubmed/16467544>.

286. Suntharalingam M, Haas ML, Conley BA, et al. The use of carboplatin and paclitaxel with daily radiotherapy in patients with locally advanced squamous cell carcinomas of the head and neck. *Int J Radiat Oncol Biol Phys* 2000;47:49-56. Available at: <https://www.ncbi.nlm.nih.gov/pubmed/10758304>.

287. Saito Y, Fujikawa H, Takatsuka S, et al. Risk factors for lymph node metastasis in cutaneous squamous cell carcinoma: a long-term retrospective study of Japanese patients. *Int J Clin Oncol* 2021;26:606-612. Available at: <https://www.ncbi.nlm.nih.gov/pubmed/33175299>.

288. Gurudutt VV, Genden EM. Cutaneous squamous cell carcinoma of the head and neck. *J Skin Cancer* 2011;2011:502723. Available at: <http://www.ncbi.nlm.nih.gov/pubmed/21461387>.

289. Forest VI, Clark JJ, Veness MJ, Milross C. N1S3: a revised staging system for head and neck cutaneous squamous cell carcinoma with lymph node metastases: results of 2 Australian Cancer Centers. *Cancer* 2010;116:1298-1304. Available at: <https://www.ncbi.nlm.nih.gov/pubmed/20052712>.

290. Wang JT, Palme CE, Wang AY, et al. In patients with metastatic cutaneous head and neck squamous cell carcinoma to cervical lymph nodes, the extent of neck dissection does not influence outcome. *J Laryngol Otol* 2013;127 Suppl 1:S2-7. Available at: <https://www.ncbi.nlm.nih.gov/pubmed/23046820>.





# NCCN Guidelines Version 1.2024

## Squamous Cell Skin Cancer

291. Goh RY, Bova R, Fogarty GB. Cutaneous squamous cell carcinoma metastatic to parotid - analysis of prognostic factors and treatment outcome. *World J Surg Oncol* 2012;10:117. Available at: <http://www.ncbi.nlm.nih.gov/pubmed/22731750>.

292. McDowell LJ, Tan TJ, Bressel M, et al. Outcomes of cutaneous squamous cell carcinoma of the head and neck with parotid metastases. *J Med Imaging Radiat Oncol* 2016;60:668-676. Available at: <https://www.ncbi.nlm.nih.gov/pubmed/27324298>.

293. Hirshoren N, Danne J, Dixon BJ, et al. Prognostic markers in metastatic cutaneous squamous cell carcinoma of the head and neck. *Head Neck* 2017;39:772-778. Available at: <https://www.ncbi.nlm.nih.gov/pubmed/28199044>.

294. Czerwonka L, De Santis RJ, Horowitz G, et al. Staging cutaneous squamous cell carcinoma metastases to the parotid gland. *Laryngoscope* 2017;127:2063-2069. Available at: <https://www.ncbi.nlm.nih.gov/pubmed/28295401>.

295. Thom JJ, Moore EJ, Price DL, et al. The Role of Total Parotidectomy for Metastatic Cutaneous Squamous Cell Carcinoma and Malignant Melanoma. *JAMA Otolaryngol Head Neck Surg* 2014;140:548-554. Available at: <https://www.ncbi.nlm.nih.gov/pubmed/24722863>.

296. Palme CE, O'Brien CJ, Veness MJ, et al. Extent of parotid disease influences outcome in patients with metastatic cutaneous squamous cell carcinoma. *Arch Otolaryngol Head Neck Surg* 2003;129:750-753. Available at: <http://www.ncbi.nlm.nih.gov/pubmed/12874077>.

297. Audet N, Palme CE, Gullane PJ, et al. Cutaneous metastatic squamous cell carcinoma to the parotid gland: analysis and outcome. *Head Neck* 2004;26:727-732. Available at: <http://www.ncbi.nlm.nih.gov/pubmed/15287040>.

298. Hinerman RW, Indelicato DJ, Amdur RJ, et al. Cutaneous squamous cell carcinoma metastatic to parotid-area lymph nodes. *Laryngoscope* 2008;118:1989-1996. Available at: <https://www.ncbi.nlm.nih.gov/pubmed/18849863>.

299. Veness MJ, Morgan GJ, Palme CE, Gebiski V. Surgery and adjuvant radiotherapy in patients with cutaneous head and neck squamous cell carcinoma metastatic to lymph nodes: combined treatment should be considered best practice. *Laryngoscope* 2005;115:870-875. Available at: <http://www.ncbi.nlm.nih.gov/pubmed/15867656>.

300. Oddone N, Morgan GJ, Palme CE, et al. Metastatic cutaneous squamous cell carcinoma of the head and neck: the Immunosuppression, Treatment, Extranodal spread, and Margin status (ITEM) prognostic score to predict outcome and the need to improve survival. *Cancer* 2009;115:1883-1891. Available at: <https://www.ncbi.nlm.nih.gov/pubmed/19224549>.

301. Sweeny L, Zimmerman T, Carroll WR, et al. Head and neck cutaneous squamous cell carcinoma requiring parotidectomy: prognostic indicators and treatment selection. *Otolaryngol Head Neck Surg* 2014;150:610-617. Available at: <https://www.ncbi.nlm.nih.gov/pubmed/24474713>.

302. Chen MM, Roman SA, Sosa JA, Judson BL. Prognostic factors for squamous cell cancer of the parotid gland: an analysis of 2104 patients. *Head Neck* 2015;37:1-7. Available at: <https://www.ncbi.nlm.nih.gov/pubmed/24339135>.

303. Ch'ng S, Maitra A, Allison RS, et al. Parotid and cervical nodal status predict prognosis for patients with head and neck metastatic cutaneous squamous cell carcinoma. *J Surg Oncol* 2008;98:101-105. Available at: <http://www.ncbi.nlm.nih.gov/pubmed/18523982>.

304. Sahovaler A, Krishnan RJ, Yeh DH, et al. Outcomes of Cutaneous Squamous Cell Carcinoma in the Head and Neck Region With Regional Lymph Node Metastasis: A Systematic Review and Meta-analysis. *JAMA Otolaryngol Head Neck Surg* 2019. Available at: <https://www.ncbi.nlm.nih.gov/pubmed/30844021>.

305. O'Brien CJ, McNeil EB, McMahon JD, et al. Significance of clinical stage, extent of surgery, and pathologic findings in metastatic cutaneous squamous carcinoma of the parotid gland. *Head Neck* 2002;24:417-422. Available at: <http://www.ncbi.nlm.nih.gov/pubmed/12001070>.



# NCCN Guidelines Version 1.2024

## Squamous Cell Skin Cancer

306. Lam JKS, Sundaresan P, GebSKI V, Veness MJ. Immunocompromised patients with metastatic cutaneous nodal squamous cell carcinoma of the head and neck: Poor outcome unrelated to the index lesion. *Head Neck* 2018. Available at: <https://pubmed.ncbi.nlm.nih.gov/29360262/>.

307. Cutaneous squamous cell carcinoma and other cutaneous carcinomas. In: Edge SB, Carducci M, Byrd DR, eds. *AJCC Cancer Staging Manual* (ed 7). New York: Springer-Verlag New York, LLC; 2009.

308. Pramana A, Browne L, Graham PH. Metastatic cutaneous squamous cell carcinoma to parotid nodes: the role of bolus with adjuvant radiotherapy. *J Med Imaging Radiat Oncol* 2012;56:100-108. Available at: <https://www.ncbi.nlm.nih.gov/pubmed/22339753>.

309. Amoils M, Lee CS, Sunwoo J, et al. Node-positive cutaneous squamous cell carcinoma of the head and neck: Survival, high-risk features, and adjuvant chemoradiotherapy outcomes. *Head Neck* 2017;39:881-885. Available at: <https://www.ncbi.nlm.nih.gov/pubmed/28252823>.

310. Khansur T, Kennedy A. Cisplatin and 5-fluorouracil for advanced locoregional and metastatic squamous cell carcinoma of the skin. *Cancer* 1991;67:2030-2032. Available at: <https://www.ncbi.nlm.nih.gov/pubmed/2004320>.

311. Reigneau M, Robert C, Routier E, et al. Efficacy of neoadjuvant cetuximab alone or with platinum salt for the treatment of unresectable advanced nonmetastatic cutaneous squamous cell carcinomas. *Br J Dermatol* 2015;173:527-534. Available at: <http://www.ncbi.nlm.nih.gov/pubmed/25704233>.

312. Jarkowski A, 3rd, Hare R, Loud P, et al. Systemic Therapy in Advanced Cutaneous Squamous Cell Carcinoma (CSCC): The Roswell Park Experience and a Review of the Literature. *Am J Clin Oncol* 2016;39:545-548. Available at: <https://www.ncbi.nlm.nih.gov/pubmed/24879468>.

313. Maubec E, Petrow P, Scheer-Senjarich I, et al. Phase II Study of Cetuximab As First-Line Single-Drug Therapy in Patients With Unresectable Squamous Cell Carcinoma of the Skin. *J Clin Oncol* 2011;29:3419-3426. Available at: <http://www.ncbi.nlm.nih.gov/pubmed/21810686>.

314. Lewis CM, Glisson BS, Feng L, et al. A phase II study of gefitinib for aggressive cutaneous squamous cell carcinoma of the head and neck. *Clin Cancer Res* 2012;18:1435-1446. Available at: <https://www.ncbi.nlm.nih.gov/pubmed/22261807>.

315. Porceddu SV, Bressel M, Poulsen MG, et al. Postoperative Concurrent Chemoradiotherapy Versus Postoperative Radiotherapy in High-Risk Cutaneous Squamous Cell Carcinoma of the Head and Neck: The Randomized Phase III TROG 05.01 Trial. *J Clin Oncol* 2018;JCO2017770941. Available at: <https://www.ncbi.nlm.nih.gov/pubmed/29537906>.

316. Goyal U, Prabhakar NK, Davuluri R, et al. Role of Concurrent Systemic Therapy with Adjuvant Radiation Therapy for Locally Advanced Cutaneous Head and Neck Squamous Cell Carcinoma. *Cureus* 2017;9:e1784. Available at: <https://www.ncbi.nlm.nih.gov/pubmed/29279810>.

317. Trosman SJ, Zhu A, Nicolli EA, et al. High-Risk Cutaneous Squamous Cell Cancer of the Head and Neck: Risk Factors for Recurrence and Impact of Adjuvant Treatment. *Laryngoscope* 2021;131:E136-E143. Available at: <https://www.ncbi.nlm.nih.gov/pubmed/32065413>.

318. Tanvetyanon T, Padhya T, McCaffrey J, et al. Postoperative concurrent chemotherapy and radiotherapy for high-risk cutaneous squamous cell carcinoma of the head and neck. *Head Neck* 2015;37:840-845. Available at: <https://www.ncbi.nlm.nih.gov/pubmed/24623654>.

319. Nottage MK, Lin C, Hughes BG, et al. Prospective study of definitive chemoradiation in locally or regionally advanced squamous cell



# NCCN Guidelines Version 1.2024

## Squamous Cell Skin Cancer

carcinoma of the skin. *Head Neck* 2017;39:679-683. Available at: <https://www.ncbi.nlm.nih.gov/pubmed/28032670>.

320. Guthrie TH, Jr., Porubsky ES, Luxenberg MN, et al. Cisplatin-based chemotherapy in advanced basal and squamous cell carcinomas of the skin: results in 28 patients including 13 patients receiving multimodality therapy. *J Clin Oncol* 1990;8:342-346. Available at: <http://www.ncbi.nlm.nih.gov/pubmed/2405109>.

321. Lu SM, Lien WW. Concurrent Radiotherapy With Cetuximab or Platinum-based Chemotherapy for Locally Advanced Cutaneous Squamous Cell Carcinoma of the Head and Neck. *Am J Clin Oncol* 2018;41:95-99. Available at: <https://www.ncbi.nlm.nih.gov/pubmed/26353121>.

322. Amaral T, Osewold M, Presser D, et al. Advanced cutaneous squamous cell carcinoma: real world data of patient profiles and treatment patterns. *J Eur Acad Dermatol Venereol* 2019;33 Suppl 8:44-51. Available at: <https://www.ncbi.nlm.nih.gov/pubmed/31658392>.

323. Preneau S, Rio E, Brocard A, et al. Efficacy of cetuximab in the treatment of squamous cell carcinoma. *J Dermatolog Treat* 2014;25:424-427. Available at: <http://www.ncbi.nlm.nih.gov/pubmed/23167307>.

324. Samstein RM, Ho AL, Lee NY, Barker CA. Locally advanced and unresectable cutaneous squamous cell carcinoma: outcomes of concurrent cetuximab and radiotherapy. *J Skin Cancer* 2014;2014:284582. Available at: <https://www.ncbi.nlm.nih.gov/pubmed/25136458>.

325. O'Bryan K, Sherman W, Niedt GW, et al. An evolving paradigm for the workup and management of high-risk cutaneous squamous cell carcinoma. *J Am Acad Dermatol* 2013;69:595-602 e591. Available at: <https://www.ncbi.nlm.nih.gov/pubmed/23871719>.

326. Joseph K, Alkaabi K, Warkentin H, et al. Cetuximab-radiotherapy combination in the management of locally advanced cutaneous squamous cell carcinoma. *J Med Imaging Radiat Oncol* 2019;63:257-263. Available at: <https://www.ncbi.nlm.nih.gov/pubmed/30549229>.

327. Berliner JG, Schulman JM, Lazarova Z, et al. Response of Cutaneous Squamous Cell Carcinoma to Treatment With Cetuximab. *Dermatol Surg* 2019;45:313-316. Available at: <https://www.ncbi.nlm.nih.gov/pubmed/29957662>.

328. Ogata D, Namikawa K, Otsuka M, et al. Systemic treatment of patients with advanced cutaneous squamous cell carcinoma: response rates and outcomes of the regimes used. *Eur J Cancer* 2020;127:108-117. Available at: <https://www.ncbi.nlm.nih.gov/pubmed/32004792>.

329. Trodello C, Pepper JP, Wong M, Wysong A. Cisplatin and Cetuximab Treatment for Metastatic Cutaneous Squamous Cell Carcinoma: A Systematic Review. *Dermatol Surg* 2017;43:40-49. Available at: <https://www.ncbi.nlm.nih.gov/pubmed/27618393>.

330. Heath CH, Deep NL, Nabell L, et al. Phase 1 study of erlotinib plus radiation therapy in patients with advanced cutaneous squamous cell carcinoma. *Int J Radiat Oncol Biol Phys* 2013;85:1275-1281. Available at: <https://www.ncbi.nlm.nih.gov/pubmed/23182701>.

331. Hourbeigt K, Ehret M, Visseaux L, et al. Efficacy and safety of panitumumab alone or in association with radiotherapy in unresectable cutaneous squamous cell carcinoma. *J Eur Acad Dermatol Venereol* 2020;34:2789-2794. Available at: <https://www.ncbi.nlm.nih.gov/pubmed/32294281>.

332. Fujisawa Y, Umebayashi Y, Ichikawa E, et al. Chemoradiation using low-dose cisplatin and 5-fluorouracil in locally advanced squamous cell carcinoma of the skin: a report of two cases. *J Am Acad Dermatol* 2006;55:S81-85. Available at: <https://www.ncbi.nlm.nih.gov/pubmed/17052540>.

333. Migden MR, Khushalani NI, Chang ALS, et al. Cemiplimab in locally advanced cutaneous squamous cell carcinoma: results from an open-label, phase 2, single-arm trial. *Lancet Oncol* 2020;21:294-305. Available at: <https://www.ncbi.nlm.nih.gov/pubmed/31952975>.

334. Migden MR, Rischin D, Schmults CD, et al. PD-1 Blockade with Cemiplimab in Advanced Cutaneous Squamous-Cell Carcinoma. *N Engl*





# NCCN Guidelines Version 1.2024

## Squamous Cell Skin Cancer

J Med 2018;379:341-351. Available at:

<https://www.ncbi.nlm.nih.gov/pubmed/29863979>.

335. Rischin D, Khushalani NI, Schmults CD, et al. Phase II study of cemiplimab in patients (pts) with advanced cutaneous squamous cell carcinoma (CSCC): Longer follow-up. Journal of Clinical Oncology 2020;38:10018-10018. Available at:

[https://ascopubs.org/doi/abs/10.1200/JCO.2020.38.15\\_suppl.10018](https://ascopubs.org/doi/abs/10.1200/JCO.2020.38.15_suppl.10018).

336. Rischin D, Migden MR, Lim AM, et al. Phase 2 study of cemiplimab in patients with metastatic cutaneous squamous cell carcinoma: primary analysis of fixed-dosing, long-term outcome of weight-based dosing. J Immunother Cancer 2020;8. Available at:

<https://www.ncbi.nlm.nih.gov/pubmed/32554615>.

337. Hughes BGM, Munoz-Couselo E, Mortier L, et al. Pembrolizumab for locally advanced and recurrent/metastatic cutaneous squamous cell carcinoma (KEYNOTE-629 study): an open-label, nonrandomized, multicenter, phase II trial. Ann Oncol 2021. Available at:

<https://www.ncbi.nlm.nih.gov/pubmed/34293460>.

338. Grob JJ, Gonzalez R, Basset-Seguín N, et al. Pembrolizumab Monotherapy for Recurrent or Metastatic Cutaneous Squamous Cell Carcinoma: A Single-Arm Phase II Trial (KEYNOTE-629). J Clin Oncol 2020;38:2916-2925. Available at:

<https://www.ncbi.nlm.nih.gov/pubmed/32673170>.

339. Cowey CL, Robert NJ, Espirito JL, et al. Clinical outcomes among unresectable, locally advanced, and metastatic cutaneous squamous cell carcinoma patients treated with systemic therapy. Cancer Med 2020;9:7381-7387. Available at:

<https://www.ncbi.nlm.nih.gov/pubmed/32578965>.

340. Conen KL, Fischer N, Hofbauer GF, et al. Cetuximab in metastatic squamous cell cancer of the skin: a Swiss case series. Dermatology 2014;229:97-101. Available at:

<https://www.ncbi.nlm.nih.gov/pubmed/24923455>.

341. Foote MC, McGrath M, Guminski A, et al. Phase II study of single-agent panitumumab in patients with incurable cutaneous squamous cell carcinoma. Ann Oncol 2014;25:2047-2052. Available at:

<https://www.ncbi.nlm.nih.gov/pubmed/25091317>.

342. William WN, Jr., Feng L, Ferrarotto R, et al. Gefitinib for patients with incurable cutaneous squamous cell carcinoma: A single-arm phase II clinical trial. J Am Acad Dermatol 2017;77:1110-1113 e1112. Available at:

<https://www.ncbi.nlm.nih.gov/pubmed/28964539>.

343. Cavalieri S, Perrone F, Miceli R, et al. Efficacy and safety of single-agent pan-human epidermal growth factor receptor (HER) inhibitor dacomitinib in locally advanced unresectable or metastatic skin squamous cell cancer. Eur J Cancer 2018;97:7-15. Available at:

<https://www.ncbi.nlm.nih.gov/pubmed/29734047>.

344. Gold KA, Kies MS, William WN, Jr., et al. Erlotinib in the treatment of recurrent or metastatic cutaneous squamous cell carcinoma: A single-arm phase 2 clinical trial. Cancer 2018. Available at:

<https://www.ncbi.nlm.nih.gov/pubmed/29579331>.

345. Ferrarotto R, Amit M, Nagarajan P, et al. Pilot Phase II Trial of Neoadjuvant Immunotherapy in Locoregionally Advanced, Resectable Cutaneous Squamous Cell Carcinoma of the Head and Neck. Clin Cancer Res 2021;27:4557-4565. Available at:

<https://www.ncbi.nlm.nih.gov/pubmed/34187851>.

346. Lavaud J, Blom A, Longvert C, et al. Pembrolizumab and concurrent hypo-fractionated radiotherapy for advanced non-resectable cutaneous squamous cell carcinoma. Eur J Dermatol 2019;29:636-640. Available at:

<https://www.ncbi.nlm.nih.gov/pubmed/31903954>.

347. Karagas MR, Stukel TA, Greenberg ER, et al. Risk of subsequent basal cell carcinoma and squamous cell carcinoma of the skin among patients with prior skin cancer. Skin Cancer Prevention Study Group. JAMA 1992;267:3305-3310. Available at:

<http://www.ncbi.nlm.nih.gov/pubmed/1597912>.



# NCCN Guidelines Version 1.2024

## Squamous Cell Skin Cancer

348. Flohil SC, van der Leest RJ, Arends LR, et al. Risk of subsequent cutaneous malignancy in patients with prior keratinocyte carcinoma: a systematic review and meta-analysis. *Eur J Cancer* 2013;49:2365-2375. Available at: <http://www.ncbi.nlm.nih.gov/pubmed/23608733>.

349. Marcil I, Stern RS. Risk of developing a subsequent nonmelanoma skin cancer in patients with a history of nonmelanoma skin cancer: a critical review of the literature and meta-analysis. *Arch Dermatol* 2000;136:1524-1530. Available at: <http://www.ncbi.nlm.nih.gov/pubmed/11115165>.

350. Ahmed I, Berth-Jones J, Charles-Holmes S, et al. Comparison of cryotherapy with curettage in the treatment of Bowen's disease: a prospective study. *Br J Dermatol* 2000;143:759-766. Available at: <https://www.ncbi.nlm.nih.gov/pubmed/11069453>.

351. Hansen JP, Drake AL, Walling HW. Bowen's Disease: a four-year retrospective review of epidemiology and treatment at a university center. *Dermatol Surg* 2008;34:878-883. Available at: <https://www.ncbi.nlm.nih.gov/pubmed/18363722>.

352. Overmark M, Koskenmies S, Pitkanen S. A Retrospective Study of Treatment of Squamous Cell Carcinoma In situ. *Acta Derm Venereol* 2016;96:64-67. Available at: <http://www.ncbi.nlm.nih.gov/pubmed/26073523>.

353. Stewart JR, Lang ME, Brewer JD. Efficacy of nonexcisional treatment modalities for superficially invasive and in situ squamous cell carcinoma: A systematic review and meta-analysis. *J Am Acad Dermatol* 2021. Available at: <https://www.ncbi.nlm.nih.gov/pubmed/34375669>.

354. Warshauer E, Warshauer BL. Clearance of basal cell and superficial squamous cell carcinomas after imiquimod therapy. *J Drugs Dermatol* 2008;7:447-451. Available at: <https://www.ncbi.nlm.nih.gov/pubmed/18505136>.

355. Love WE, Bernhard JD, Bordeaux JS. Topical imiquimod or fluorouracil therapy for basal and squamous cell carcinoma: a systematic

review. *Arch Dermatol* 2009;145:1431-1438. Available at: <https://www.ncbi.nlm.nih.gov/pubmed/20026854>.

356. Rosen T, Harting M, Gibson M. Treatment of Bowen's disease with topical 5% imiquimod cream: retrospective study. *Dermatol Surg* 2007;33:427-432. Available at: <https://www.ncbi.nlm.nih.gov/pubmed/17430376>.

357. Mackenzie-Wood A, Kossard S, de Launey J, et al. Imiquimod 5% cream in the treatment of Bowen's disease. *J Am Acad Dermatol* 2001;44:462-470. Available at: <https://www.ncbi.nlm.nih.gov/pubmed/11209116>.

358. Chitwood K, Etkorn J, Cohen G. Topical and intralesional treatment of nonmelanoma skin cancer: efficacy and cost comparisons. *Dermatol Surg* 2013;39:1306-1316. Available at: <https://www.ncbi.nlm.nih.gov/pubmed/23915332>.

359. Patel GK, Goodwin R, Chawla M, et al. Imiquimod 5% cream monotherapy for cutaneous squamous cell carcinoma in situ (Bowen's disease): a randomized, double-blind, placebo-controlled trial. *J Am Acad Dermatol* 2006;54:1025-1032. Available at: <http://www.ncbi.nlm.nih.gov/pubmed/16713457>.

360. Bargman H, Hochman J. Topical treatment of Bowen's disease with 5-Fluorouracil. *J Cutan Med Surg* 2003;7:101-105. Available at: <https://www.ncbi.nlm.nih.gov/pubmed/12447619>.

361. Salim A, Leman JA, McColl JH, et al. Randomized comparison of photodynamic therapy with topical 5-fluorouracil in Bowen's disease. *Br J Dermatol* 2003;148:539-543. Available at: <https://www.ncbi.nlm.nih.gov/pubmed/12653747>.

362. Morton C, Horn M, Leman J, et al. Comparison of topical methyl aminolevulinate photodynamic therapy with cryotherapy or Fluorouracil for treatment of squamous cell carcinoma in situ: Results of a multicenter randomized trial. *Arch Dermatol* 2006;142:729-735. Available at: <https://www.ncbi.nlm.nih.gov/pubmed/16785375>.





# NCCN Guidelines Version 1.2024

## Squamous Cell Skin Cancer

363. Cairnduff F, Stringer MR, Hudson EJ, et al. Superficial photodynamic therapy with topical 5-aminolaevulinic acid for superficial primary and secondary skin cancer. *Br J Cancer* 1994;69:605-608. Available at: <http://www.ncbi.nlm.nih.gov/pubmed/8123497>.

364. Morton CA, Whitehurst C, Moore JV, MacKie RM. Comparison of red and green light in the treatment of Bowen's disease by photodynamic therapy. *Br J Dermatol* 2000;143:767-772. Available at: <https://www.ncbi.nlm.nih.gov/pubmed/11069454>.

365. Morton CA, Whitehurst C, McColl JH, et al. Photodynamic therapy for large or multiple patches of Bowen disease and basal cell carcinoma. *Arch Dermatol* 2001;137:319-324. Available at: <https://www.ncbi.nlm.nih.gov/pubmed/11255332>.

366. Varma S, Wilson H, Kurwa HA, et al. Bowen's disease, solar keratoses and superficial basal cell carcinomas treated by photodynamic therapy using a large-field incoherent light source. *Br J Dermatol* 2001;144:567-574. Available at: <https://www.ncbi.nlm.nih.gov/pubmed/11260016>.

367. Lui H, Hobbs L, Tope WD, et al. Photodynamic therapy of multiple nonmelanoma skin cancers with verteporfin and red light-emitting diodes: two-year results evaluating tumor response and cosmetic outcomes. *Arch Dermatol* 2004;140:26-32. Available at: <https://www.ncbi.nlm.nih.gov/pubmed/14732656>.

368. Haddad R, Neshar E, Weiss J, et al. Photodynamic therapy for Bowen's disease and squamous cell carcinoma of the skin. *Photodiagnosis Photodyn Ther* 2004;1:225-230. Available at: <https://www.ncbi.nlm.nih.gov/pubmed/25048336>.

369. Calzavara-Pinton PG, Venturini M, Sala R, et al. Methylaminolaevulinate-based photodynamic therapy of Bowen's disease and squamous cell carcinoma. *Br J Dermatol* 2008;159:137-144. Available at: <https://www.ncbi.nlm.nih.gov/pubmed/18489606>.

370. Lopez N, Meyer-Gonzalez T, Herrera-Acosta E, et al. Photodynamic therapy in the treatment of extensive Bowen's disease. *J Dermatolog*

*Treat* 2012;23:428-430. Available at: <https://www.ncbi.nlm.nih.gov/pubmed/21787214>.

371. Truchuelo M, Fernandez-Guarino M, Fleita B, et al. Effectiveness of photodynamic therapy in Bowen's disease: an observational and descriptive study in 51 lesions. *J Eur Acad Dermatol Venereol* 2012;26:868-874. Available at: <https://www.ncbi.nlm.nih.gov/pubmed/21740466>.

372. Ko DY, Kim KH, Song KH. A randomized trial comparing methyl aminolaevulinate photodynamic therapy with and without Er:YAG ablative fractional laser treatment in Asian patients with lower extremity Bowen disease: results from a 12-month follow-up. *Br J Dermatol* 2014;170:165-172. Available at: <https://www.ncbi.nlm.nih.gov/pubmed/24102369>.

373. Choi SH, Kim KH, Song KH. Effect of Methyl Aminolevulinate Photodynamic Therapy With and Without Ablative Fractional Laser Treatment in Patients With Microinvasive Squamous Cell Carcinoma: A Randomized Clinical Trial. *JAMA Dermatol* 2017;153:289-295. Available at: <https://www.ncbi.nlm.nih.gov/pubmed/28199463>.

374. Zaar O, Fouglerberg J, Hermansson A, et al. Effectiveness of photodynamic therapy in Bowen's disease: a retrospective observational study in 423 lesions. *J Eur Acad Dermatol Venereol* 2017;31:1289-1294. Available at: <https://www.ncbi.nlm.nih.gov/pubmed/28190258>.

375. Souza CS, Felicio LB, Ferreira J, et al. Long-term follow-up of topical 5-aminolaevulinic acid photodynamic therapy diode laser single session for non-melanoma skin cancer. *Photodiagnosis Photodyn Ther* 2009;6:207-213. Available at: <https://www.ncbi.nlm.nih.gov/pubmed/19932453>.

376. Morton CA, Whitehurst C, Moseley H, et al. Comparison of photodynamic therapy with cryotherapy in the treatment of Bowen's disease. *Br J Dermatol* 1996;135:766-771. Available at: <https://www.ncbi.nlm.nih.gov/pubmed/8977678>.



# NCCN Guidelines Version 1.2024

## Squamous Cell Skin Cancer

377. Kuflik EG, Gage AA. The five-year cure rate achieved by cryosurgery for skin cancer. *J Am Acad Dermatol* 1991;24:1002-1004. Available at: <http://www.ncbi.nlm.nih.gov/pubmed/1820761>.

378. Fraunfelder FT, Zacarian SA, Limmer BL, Wingfield D. Cryosurgery for malignancies of the eyelid. *Ophthalmology* 1980;87:461-465. Available at: <https://www.ncbi.nlm.nih.gov/pubmed/7413134>.

379. Lindemalm-Lundstam B, Dalenback J. Prospective follow-up after curettage-cryosurgery for scalp and face skin cancers. *Br J Dermatol* 2009;161:568-576. Available at: <https://www.ncbi.nlm.nih.gov/pubmed/19624544>.

380. Holt PJ. Cryotherapy for skin cancer: results over a 5-year period using liquid nitrogen spray cryosurgery. *Br J Dermatol* 1988;119:231-240. Available at: <https://www.ncbi.nlm.nih.gov/pubmed/3166941>.

381. Peikert JM. Prospective trial of curettage and cryosurgery in the management of non-facial, superficial, and minimally invasive basal and squamous cell carcinoma. *Int J Dermatol* 2011;50:1135-1138. Available at: <http://www.ncbi.nlm.nih.gov/pubmed/22126880>.

382. Werner RN, Sammain A, Erdmann R, et al. The natural history of actinic keratosis: a systematic review. *Br J Dermatol* 2013;169:502-518. Available at: <https://www.ncbi.nlm.nih.gov/pubmed/23647091>.

383. Jorizzo J, Weiss J, Furst K, et al. Effect of a 1-week treatment with 0.5% topical fluorouracil on occurrence of actinic keratosis after cryosurgery: a randomized, vehicle-controlled clinical trial. *Arch Dermatol* 2004;140:813-816. Available at: <https://www.ncbi.nlm.nih.gov/pubmed/15262691>.

384. Stockfleth E, von Kiedrowski R, Dominicus R, et al. Efficacy and Safety of 5-Fluorouracil 0.5%/Salicylic Acid 10% in the Field-Directed Treatment of Actinic Keratosis: A Phase III, Randomized, Double-Blind, Vehicle-Controlled Trial. *Dermatol Ther (Heidelb)* 2017;7:81-96. Available at: <https://www.ncbi.nlm.nih.gov/pubmed/27995485>.

385. Pomerantz H, Hogan D, Eilers D, et al. Long-term Efficacy of Topical Fluorouracil Cream, 5%, for Treating Actinic Keratosis: A Randomized Clinical Trial. *JAMA Dermatol* 2015;151:952-960. Available at: <https://www.ncbi.nlm.nih.gov/pubmed/25950503>.

386. Rahvar M, Lamel SA, Maibach HI. Randomized, vehicle-controlled trials of topical 5-fluorouracil therapy for actinic keratosis treatment: an overview. *Immunotherapy* 2012;4:939-945. Available at: <https://www.ncbi.nlm.nih.gov/pubmed/23046237>.

387. Stockfleth E, Zwingers T, Willers C. Recurrence rates and patient assessed outcomes of 0.5% 5-fluorouracil in combination with salicylic acid treating actinic keratoses. *Eur J Dermatol* 2012;22:370-374. Available at: <https://www.ncbi.nlm.nih.gov/pubmed/22494856>.

388. Cunningham TJ, Tabacchi M, Eliane JP, et al. Randomized trial of calcipotriol combined with 5-fluorouracil for skin cancer precursor immunotherapy. *J Clin Invest* 2017;127:106-116. Available at:

389. Hadley G, Derry S, Moore RA. Imiquimod for actinic keratosis: systematic review and meta-analysis. *J Invest Dermatol* 2006;126:1251-1255. Available at: <http://www.ncbi.nlm.nih.gov/pubmed/16557235>.

390. Gebauer K, Shumack S, Cowen PS. Effect of dosing frequency on the safety and efficacy of imiquimod 5% cream for treatment of actinic keratosis on the forearms and hands: a phase II, randomized placebo-controlled trial. *Br J Dermatol* 2009;161:897-903. Available at: <https://www.ncbi.nlm.nih.gov/pubmed/19545297>.

391. Swanson N, Smith CC, Kaur M, Goldenberg G. Imiquimod 2.5% and 3.75% for the treatment of actinic keratoses: two phase 3, multicenter, randomized, double-blind, placebo-controlled studies. *J Drugs Dermatol* 2014;13:166-169. Available at: <https://www.ncbi.nlm.nih.gov/pubmed/24509967>.

392. Alomar A, Stockfleth E, Dirschka T, et al. Efficacy and Safety of Imiquimod 3.75% from Lmax in Actinic Keratosis According to Fitzpatrick Skin Type. *J Drugs Dermatol* 2016;15:285-289. Available at: <https://www.ncbi.nlm.nih.gov/pubmed/26954313>.



# NCCN Guidelines Version 1.2024

## Squamous Cell Skin Cancer

393. Blauvelt A, Kempers S, Lain E, et al. Phase 3 Trials of Tirbanibulin Ointment for Actinic Keratosis. *N Engl J Med* 2021;384:512-520. Available at: <https://www.ncbi.nlm.nih.gov/pubmed/33567191>.

394. Freeman M, Vinciullo C, Francis D, et al. A comparison of photodynamic therapy using topical methyl aminolevulinate (Metvix) with single cycle cryotherapy in patients with actinic keratosis: a prospective, randomized study. *J Dermatolog Treat* 2003;14:99-106. Available at: <https://www.ncbi.nlm.nih.gov/pubmed/12775317>.

395. Piacquadio DJ, Chen DM, Farber HF, et al. Photodynamic therapy with aminolevulinic acid topical solution and visible blue light in the treatment of multiple actinic keratoses of the face and scalp: investigator-blinded, phase 3, multicenter trials. *Arch Dermatol* 2004;140:41-46. Available at: <https://www.ncbi.nlm.nih.gov/pubmed/14732659>.

396. Hauschild A, Stockfleth E, Popp G, et al. Optimization of photodynamic therapy with a novel self-adhesive 5-aminolaevulinic acid patch: results of two randomized controlled phase III studies. *Br J Dermatol* 2009;160:1066-1074. Available at: <https://www.ncbi.nlm.nih.gov/pubmed/19222455>.

397. Szeimies RM, Matheson RT, Davis SA, et al. Topical methyl aminolevulinate photodynamic therapy using red light-emitting diode light for multiple actinic keratoses: a randomized study. *Dermatol Surg* 2009;35:586-592. Available at: <https://www.ncbi.nlm.nih.gov/pubmed/19309347>.

398. Szeimies RM, Radny P, Sebastian M, et al. Photodynamic therapy with BF-200 ALA for the treatment of actinic keratosis: results of a prospective, randomized, double-blind, placebo-controlled phase III study. *Br J Dermatol* 2010;163:386-394. Available at: <https://www.ncbi.nlm.nih.gov/pubmed/20518784>.

399. Szeimies RM, Stockfleth E, Popp G, et al. Long-term follow-up of photodynamic therapy with a self-adhesive 5-aminolaevulinic acid patch: 12 months data. *Br J Dermatol* 2010;162:410-414. Available at: <https://www.ncbi.nlm.nih.gov/pubmed/19804593>.

400. Dirschka T, Radny P, Dominicus R, et al. Long-term (6 and 12 months) follow-up of two prospective, randomized, controlled phase III trials of photodynamic therapy with BF-200 ALA and methyl aminolaevulinate for the treatment of actinic keratosis. *Br J Dermatol* 2013;168:825-836. Available at: <https://www.ncbi.nlm.nih.gov/pubmed/23252768>.

401. Pariser DM, Houlihan A, Ferdon MB, et al. Randomized Vehicle-Controlled Study of Short Drug Incubation Aminolevulinic Acid Photodynamic Therapy for Actinic Keratoses of the Face or Scalp. *Dermatol Surg* 2016;42:296-304. Available at: <https://www.ncbi.nlm.nih.gov/pubmed/26863596>.

402. Pariser DM, Lowe NJ, Stewart DM, et al. Photodynamic therapy with topical methyl aminolevulinate for actinic keratosis: results of a prospective randomized multicenter trial. *J Am Acad Dermatol* 2003;48:227-232. Available at: <http://www.ncbi.nlm.nih.gov/pubmed/12582393>.

403. Szeimies RM, Karrer S, Radakovic-Fijan S, et al. Photodynamic therapy using topical methyl 5-aminolevulinate compared with cryotherapy for actinic keratosis: A prospective, randomized study. *J Am Acad Dermatol* 2002;47:258-262. Available at: <https://www.ncbi.nlm.nih.gov/pubmed/12140473>.

404. Morton C, Campbell S, Gupta G, et al. Intraindividual, right-left comparison of topical methyl aminolaevulinate-photodynamic therapy and cryotherapy in subjects with actinic keratoses: a multicentre, randomized controlled study. *Br J Dermatol* 2006;155:1029-1036. Available at: <https://www.ncbi.nlm.nih.gov/pubmed/17034536>.

405. Kaufmann R, Spelman L, Weightman W, et al. Multicentre intraindividual randomized trial of topical methyl aminolaevulinate-photodynamic therapy vs. cryotherapy for multiple actinic keratoses on the extremities. *Br J Dermatol* 2008;158:994-999. Available at: <https://www.ncbi.nlm.nih.gov/pubmed/18341663>.

406. Serra-Guillen C, Nagore E, Hueso L, et al. A randomized pilot comparative study of topical methyl aminolevulinate photodynamic





# NCCN Guidelines Version 1.2024

## Squamous Cell Skin Cancer

therapy versus imiquimod 5% versus sequential application of both therapies in immunocompetent patients with actinic keratosis: clinical and histologic outcomes. *J Am Acad Dermatol* 2012;66:e131-137. Available at: <https://www.ncbi.nlm.nih.gov/pubmed/22226430>.

407. Hadley J, Tristani-Firouzi P, Hull C, et al. Results of an investigator-initiated single-blind split-face comparison of photodynamic therapy and 5% imiquimod cream for the treatment of actinic keratoses. *Dermatol Surg* 2012;38:722-727. Available at: <https://www.ncbi.nlm.nih.gov/pubmed/22340282>.

408. Smith S, Piacquadio D, Morhenn V, et al. Short incubation PDT versus 5-FU in treating actinic keratoses. *J Drugs Dermatol* 2003;2:629-635. Available at: <https://www.ncbi.nlm.nih.gov/pubmed/14711141>.

409. Kurwa HA, Yong-Gee SA, Seed PT, et al. A randomized paired comparison of photodynamic therapy and topical 5-fluorouracil in the treatment of actinic keratoses. *J Am Acad Dermatol* 1999;41:414-418. Available at: <https://www.ncbi.nlm.nih.gov/pubmed/10459115>.

410. Sotiriou E, Apalla Z, Maliamani F, et al. Intraindividual, right-left comparison of topical 5-aminolevulinic acid photodynamic therapy vs. 5% imiquimod cream for actinic keratoses on the upper extremities. *J Eur Acad Dermatol Venereol* 2009;23:1061-1065. Available at: <http://www.ncbi.nlm.nih.gov/pubmed/19470041>.

411. Moggio E, Arisi M, Zane C, et al. A randomized split-face clinical trial analyzing daylight photodynamic therapy with methyl aminolaevulinate vs ingenol mebutate gel for the treatment of multiple actinic keratoses of the face and the scalp. *Photodiagnosis Photodyn Ther* 2016;16:161-165. Available at: <https://www.ncbi.nlm.nih.gov/pubmed/27530375>.

412. Zane C, Fabiano A, Arisi M, Calzavara-Pinton P. A Randomized Split-Face Clinical Trial of Photodynamic Therapy with Methyl Aminolevulinate versus Ingenol Mebutate Gel for the Treatment of Multiple Actinic Keratoses of the Face and Scalp. *Dermatology* 2016;232:472-477. Available at: <https://www.ncbi.nlm.nih.gov/pubmed/27578305>.

413. Berman B, Nestor MS, Newburger J, et al. Treatment of facial actinic keratoses with aminolevulinic acid photodynamic therapy (ALA-PDT) or ingenol mebutate 0.015% gel with and without prior treatment with ALA-PDT. *J Drugs Dermatol* 2014;13:1353-1356. Available at: <https://www.ncbi.nlm.nih.gov/pubmed/25607702>.

414. Simon JC, Dominicus R, Karl L, et al. A prospective randomized exploratory study comparing the efficacy of once-daily topical 0.5% 5-fluorouracil in combination with 10.0% salicylic acid (5-FU/SA) vs. cryosurgery for the treatment of hyperkeratotic actinic keratosis. *J Eur Acad Dermatol Venereol* 2015;29:881-889. Available at: <https://www.ncbi.nlm.nih.gov/pubmed/25257941>.

415. Krawtchenko N, Roewert-Huber J, Ulrich M, et al. A randomised study of topical 5% imiquimod vs. topical 5-fluorouracil vs. cryosurgery in immunocompetent patients with actinic keratoses: a comparison of clinical and histological outcomes including 1-year follow-up. *Br J Dermatol* 2007;157 Suppl 2:34-40. Available at: <https://www.ncbi.nlm.nih.gov/pubmed/18067630>.

416. Foley P, Merlin K, Cumming S, et al. A comparison of cryotherapy and imiquimod for treatment of actinic keratoses: lesion clearance, safety, and skin quality outcomes. *J Drugs Dermatol* 2011;10:1432-1438. Available at: <https://www.ncbi.nlm.nih.gov/pubmed/22134568>.

417. Tanghetti E, Werschler P. Comparison of 5% 5-fluorouracil cream and 5% imiquimod cream in the management of actinic keratoses on the face and scalp. *J Drugs Dermatol* 2007;6:144-147. Available at: <http://www.ncbi.nlm.nih.gov/pubmed/17373172>.

418. Samorano LP, Torezan LA, Sanches JA. Evaluation of the tolerability and safety of a 0.015% ingenol mebutate gel compared to 5% 5-fluorouracil cream for the treatment of facial actinic keratosis: a prospective randomized trial. *J Eur Acad Dermatol Venereol* 2015;29:1822-1827. Available at: <https://www.ncbi.nlm.nih.gov/pubmed/25727104>.

419. Stockfleth E, Sibbring GC, Alarcon I. New Topical Treatment Options for Actinic Keratosis: A Systematic Review. *Acta Derm Venereol*



# NCCN Guidelines Version 1.2024

## Squamous Cell Skin Cancer

2016;96:17-22. Available at:

<https://www.ncbi.nlm.nih.gov/pubmed/26068001>.

420. Gupta AK, Paquet M. Network meta-analysis of the outcome 'participant complete clearance' in nonimmunosuppressed participants of eight interventions for actinic keratosis: a follow-up on a Cochrane review. *Br J Dermatol* 2013;169:250-259. Available at:

<https://www.ncbi.nlm.nih.gov/pubmed/23550994>.

421. Gupta AK, Davey V, McPhail H. Evaluation of the effectiveness of imiquimod and 5-fluorouracil for the treatment of actinic keratosis: Critical review and meta-analysis of efficacy studies. *J Cutan Med Surg* 2005;9:209-214. Available at:

<http://www.ncbi.nlm.nih.gov/pubmed/16502198>.

422. Steeb T, Wessely A, Petzold A, et al. Evaluation of Long-term Clearance Rates of Interventions for Actinic Keratosis: A Systematic Review and Network Meta-analysis. *JAMA Dermatol* 2021;157:1066-1077. Available at: <https://www.ncbi.nlm.nih.gov/pubmed/34347015>.

423. Steeb T, Wessely A, Schmitz L, et al. Interventions for Actinic Keratosis in Nonscalp and Nonface Localizations: Results from a Systematic Review with Network Meta-Analysis. *J Invest Dermatol* 2021;141:345-354 e348. Available at:

<https://www.ncbi.nlm.nih.gov/pubmed/32645365>.

424. Jansen MHE, Kessels J, Nelemans PJ, et al. Randomized Trial of Four Treatment Approaches for Actinic Keratosis. *N Engl J Med* 2019;380:935-946. Available at:

<https://www.ncbi.nlm.nih.gov/pubmed/30855743>.

425. Rosenberg AR, Tabacchi M, Ngo KH, et al. Skin cancer precursor immunotherapy for squamous cell carcinoma prevention. *JCI Insight* 2019;4. Available at: <https://www.ncbi.nlm.nih.gov/pubmed/30895944>.

426. McEwan LE, Smith JG. Topical diclofenac/hyaluronic acid gel in the treatment of solar keratoses. *Australas J Dermatol* 1997;38:187-189. Available at: <https://www.ncbi.nlm.nih.gov/pubmed/9431711>.

427. Rivers JK, Arlette J, Shear N, et al. Topical treatment of actinic keratoses with 3.0% diclofenac in 2.5% hyaluronan gel. *Br J Dermatol* 2002;146:94-100. Available at:

<https://www.ncbi.nlm.nih.gov/pubmed/11841372>.

428. Gebauer K, Brown P, Varigos G. Topical diclofenac in hyaluronan gel for the treatment of solar keratoses. *Australas J Dermatol* 2003;44:40-43. Available at:

<https://www.ncbi.nlm.nih.gov/pubmed/12581080>.

429. Zane C, Facchinetti E, Rossi MT, et al. A randomized clinical trial of photodynamic therapy with methyl aminolaevulinate vs. diclofenac 3% plus hyaluronic acid gel for the treatment of multiple actinic keratoses of the face and scalp. *Br J Dermatol* 2014;170:1143-1150. Available at:

<https://www.ncbi.nlm.nih.gov/pubmed/24506666>.

430. Stockfleth E, Kerl H, Zwingers T, Willers C. Low-dose 5-fluorouracil in combination with salicylic acid as a new lesion-directed option to treat topically actinic keratoses: histological and clinical study results. *Br J Dermatol* 2011;165:1101-1108. Available at:

<https://www.ncbi.nlm.nih.gov/pubmed/21517801>.

431. Zane C, Facchinetti E, Rossi MT, et al. Cryotherapy is preferable to ablative CO<sub>2</sub> laser for the treatment of isolated actinic keratoses of the face and scalp: a randomized clinical trial. *Br J Dermatol* 2014;170:1114-1121. Available at: <https://www.ncbi.nlm.nih.gov/pubmed/24472087>.

432. Ostertag JU, Quaedvlieg PJ, van der Geer S, et al. A clinical comparison and long-term follow-up of topical 5-fluorouracil versus laser resurfacing in the treatment of widespread actinic keratoses. *Lasers Surg Med* 2006;38:731-739. Available at:

<https://www.ncbi.nlm.nih.gov/pubmed/16912977>.

433. Scola N, Terras S, Georgas D, et al. A randomized, half-side comparative study of aminolaevulinate photodynamic therapy vs. CO<sub>2</sub> laser ablation in immunocompetent patients with multiple actinic keratoses. *Br J Dermatol* 2012;167:1366-1373. Available at:

<https://www.ncbi.nlm.nih.gov/pubmed/22708798>.





# NCCN Guidelines Version 1.2024

## Squamous Cell Skin Cancer

434. Holzer G, Pinkowicz A, Radakovic S, et al. Randomized controlled trial comparing 35% trichloroacetic acid peel and 5-aminolaevulinic acid photodynamic therapy for treating multiple actinic keratosis. *Br J Dermatol* 2017;176:1155-1161. Available at: <https://www.ncbi.nlm.nih.gov/pubmed/28012181>.

435. Di Nuzzo S, Cortelazzi C, Boccaletti V, et al. Comparative study of trichloroacetic acid vs. photodynamic therapy with topical 5-aminolevulinic acid for actinic keratosis of the scalp. *Photodermatol Photoimmunol Photomed* 2015;31:233-238. Available at: <https://www.ncbi.nlm.nih.gov/pubmed/25660106>.

436. Lawrence N, Cox SE, Cockerell CJ, et al. A comparison of the efficacy and safety of Jessner's solution and 35% trichloroacetic acid vs 5% fluorouracil in the treatment of widespread facial actinic keratoses. *Arch Dermatol* 1995;131:176-181. Available at: <https://www.ncbi.nlm.nih.gov/pubmed/7857114>.

437. Witheiler DD, Lawrence N, Cox SE, et al. Long-term efficacy and safety of Jessner's solution and 35% trichloroacetic acid vs 5% fluorouracil in the treatment of widespread facial actinic keratoses. *Dermatol Surg* 1997;23:191-196. Available at: <https://www.ncbi.nlm.nih.gov/pubmed/9145962>.

438. Hantash BM, Stewart DB, Cooper ZA, et al. Facial resurfacing for nonmelanoma skin cancer prophylaxis. *Arch Dermatol* 2006;142:976-982. Available at: <https://www.ncbi.nlm.nih.gov/pubmed/16924046>.

439. Whitaker DC. Microscopically proven cure of actinic cheilitis by CO2 laser. *Lasers Surg Med* 1987;7:520-523. Available at: <https://www.ncbi.nlm.nih.gov/pubmed/3431329>.

440. Robinson JK. Actinic cheilitis. A prospective study comparing four treatment methods. *Arch Otolaryngol Head Neck Surg* 1989;115:848-852. Available at: <https://www.ncbi.nlm.nih.gov/pubmed/2736096>.

441. Laws RA, Wilde JL, Grabski WJ. Comparison of electrodesiccation with CO2 laser for the treatment of actinic cheilitis. *Dermatol Surg*

2000;26:349-353. Available at: <https://www.ncbi.nlm.nih.gov/pubmed/10759824>.

442. Satorres Nieto M, Gargallo Albiol J, Gay Escoda C. Surgical management of actinic cheilitis. *Med Oral* 2001;6:205-217. Available at: <https://www.ncbi.nlm.nih.gov/pubmed/11500638>.

443. Alexiades-Armenakas MR, Geronemus RG. Laser-mediated photodynamic therapy of actinic cheilitis. *J Drugs Dermatol* 2004;3:548-551. Available at: <https://www.ncbi.nlm.nih.gov/pubmed/15552607>.

444. de Godoy Peres FF, Aigotti Haberbeck Brandao A, Rodarte Carvalho Y, et al. A study of actinic cheilitis treatment by two low-morbidity CO2 laser vaporization one-pass protocols. *Lasers Med Sci* 2009;24:375-385. Available at: <https://www.ncbi.nlm.nih.gov/pubmed/18553116>.

445. Sotiriou E, Apalla Z, Chovarda E, et al. Photodynamic therapy with 5-aminolevulinic acid in actinic cheilitis: an 18-month clinical and histological follow-up. *Journal of the European Academy of Dermatology and Venereology* 2009;24:916-920. Available at: <https://www.ncbi.nlm.nih.gov/pubmed/20028448>.

446. Lima Gda S, Silva GF, Gomes AP, et al. Diclofenac in hyaluronic acid gel: an alternative treatment for actinic cheilitis. *J Appl Oral Sci* 2010;18:533-537. Available at: <https://www.ncbi.nlm.nih.gov/pubmed/21085813>.

447. Sotiriou E, Lallas A, Goussi C, et al. Sequential use of photodynamic therapy and imiquimod 5% cream for the treatment of actinic cheilitis: a 12-month follow-up study. *Br J Dermatol* 2011;165:888-892. Available at: <https://www.ncbi.nlm.nih.gov/pubmed/21916880>.

448. Choi SH, Kim KH, Song KH. Efficacy of ablative fractional laser-assisted photodynamic therapy for the treatment of actinic cheilitis: 12-month follow-up results of a prospective, randomized, comparative trial. *Br J Dermatol* 2015;173:184-191. Available at: <https://www.ncbi.nlm.nih.gov/pubmed/25400009>.



# NCCN Guidelines Version 1.2024

## Squamous Cell Skin Cancer

449. Suarez-Perez JA, Lopez-Navarro N, Herrera-Acosta E, et al. Treatment of actinic cheilitis with methyl aminolevulinate photodynamic therapy and light fractionation: a prospective study of 10 patients. *Eur J Dermatol* 2015;25:623-624. Available at: <https://www.ncbi.nlm.nih.gov/pubmed/26677980>.

450. Chaves YN, Torezan LA, Lourenco SV, Neto CF. Evaluation of the efficacy of photodynamic therapy for the treatment of actinic cheilitis. *Photodermatol Photoimmunol Photomed* 2017;33:14-21. Available at: <https://www.ncbi.nlm.nih.gov/pubmed/27864997>.

451. Jambusaria-Pahlajani A, Hess SD, Katz KA, et al. Uncertainty in the perioperative management of high-risk cutaneous squamous cell carcinoma among Mohs surgeons. *Arch Dermatol* 2010;146:1225-1231. Available at: <https://www.ncbi.nlm.nih.gov/pubmed/21079057>.

452. Martinez JC, Otley CC, Stasko T, et al. Defining the clinical course of metastatic skin cancer in organ transplant recipients: a multicenter collaborative study. *Arch Dermatol* 2003;139:301-306. Available at: <https://www.ncbi.nlm.nih.gov/pubmed/12622621>.

453. Carucci JA, Martinez JC, Zeitouni NC, et al. In-transit metastasis from primary cutaneous squamous cell carcinoma in organ transplant recipients and nonimmunosuppressed patients: clinical characteristics, management, and outcome in a series of 21 patients. *Dermatol Surg* 2004;30:651-655. Available at: <https://www.ncbi.nlm.nih.gov/pubmed/15061850>.

454. Bordea C, Wojnarowska F, Millard PR, et al. Skin cancers in renal-transplant recipients occur more frequently than previously recognized in a temperate climate. *Transplantation* 2004;77:574-579. Available at: <http://www.ncbi.nlm.nih.gov/pubmed/15084938>.

455. Fortina AB, Piaserico S, Caforio AL, et al. Immunosuppressive level and other risk factors for basal cell carcinoma and squamous cell carcinoma in heart transplant recipients. *Arch Dermatol* 2004;140:1079-1085. Available at: <http://www.ncbi.nlm.nih.gov/pubmed/15381547>.

456. McGeown MG, Douglas JF, Middleton D. One thousand renal transplants at Belfast City Hospital: post-graft neoplasia 1968-1999, comparing azathioprine only with cyclosporin-based regimes in a single centre. *Clin Transpl* 2000:193-202. Available at: <http://www.ncbi.nlm.nih.gov/pubmed/11512313>.

457. Euvrard S, Morelon E, Rostaing L, et al. Sirolimus and secondary skin-cancer prevention in kidney transplantation. *N Engl J Med* 2012;367:329-339. Available at: <https://www.ncbi.nlm.nih.gov/pubmed/22830463>.

458. Campbell SB, Walker R, Tai SS, et al. Randomized controlled trial of sirolimus for renal transplant recipients at high risk for nonmelanoma skin cancer. *Am J Transplant* 2012;12:1146-1156. Available at: <http://www.ncbi.nlm.nih.gov/pubmed/22420843>.

459. Salgo R, Gossman J, Schofer H, et al. Switch to a sirolimus-based immunosuppression in long-term renal transplant recipients: reduced rate of (pre-)malignancies and nonmelanoma skin cancer in a prospective, randomized, assessor-blinded, controlled clinical trial. *Am J Transplant* 2010;10:1385-1393. Available at: <http://www.ncbi.nlm.nih.gov/pubmed/20121752>.

460. Alberu J, Pascoe MD, Campistol JM, et al. Lower malignancy rates in renal allograft recipients converted to sirolimus-based, calcineurin inhibitor-free immunotherapy: 24-month results from the CONVERT trial. *Transplantation* 2011;92:303-310. Available at: <https://www.ncbi.nlm.nih.gov/pubmed/21792049>.

461. Campistol JM, Eris J, Oberbauer R, et al. Sirolimus therapy after early cyclosporine withdrawal reduces the risk for cancer in adult renal transplantation. *J Am Soc Nephrol* 2006;17:581-589. Available at: <https://www.ncbi.nlm.nih.gov/pubmed/16434506>.

462. Hoogendijk-van den Akker JM, Harden PN, Hoitsma AJ, et al. Two-year randomized controlled prospective trial converting treatment of stable renal transplant recipients with cutaneous invasive squamous cell carcinomas to sirolimus. *J Clin Oncol* 2013;31:1317-1323. Available at: <https://www.ncbi.nlm.nih.gov/pubmed/23358973>.



# NCCN Guidelines Version 1.2024

## Squamous Cell Skin Cancer

463. Tedesco-Silva H, Peddi VR, Sanchez-Fructuoso A, et al. Open-Label, Randomized Study of Transition From Tacrolimus to Sirolimus Immunosuppression in Renal Allograft Recipients. *Transplant Direct* 2016;2:e69. Available at:

<https://www.ncbi.nlm.nih.gov/pubmed/27500260>.

464. Gu YH, Du JX, Ma ML. Sirolimus and non-melanoma skin cancer prevention after kidney transplantation: a meta-analysis. *Asian Pac J Cancer Prev* 2012;13:4335-4339. Available at:

<https://www.ncbi.nlm.nih.gov/pubmed/23167339>.

465. Lim WH, Russ GR, Wong G, et al. The risk of cancer in kidney transplant recipients may be reduced in those maintained on everolimus and reduced cyclosporine. *Kidney Int* 2017;91:954-963. Available at:

<https://www.ncbi.nlm.nih.gov/pubmed/28109543>.

466. Endrizzi B, Ahmed RL, Ray T, et al. Capecitabine to reduce nonmelanoma skin carcinoma burden in solid organ transplant recipients. *Dermatol Surg* 2013;39:634-645. Available at:

<http://www.ncbi.nlm.nih.gov/pubmed/23379978>.

467. Badri O, Schmults CD, Karia PS, Ruiz ES. Efficacy and Cost Analysis for Acitretin for Basal and Squamous Cell Carcinoma Prophylaxis in Renal Transplant Recipients. *Dermatol Surg* 2021;47:125-126. Available at: <https://www.ncbi.nlm.nih.gov/pubmed/32371782>.

468. Shuttleworth D, Marks R, Griffin PJ, Salaman JR. Treatment of cutaneous neoplasia with etretinate in renal transplant recipients. *Q J Med* 1988;68:717-725. Available at:

<https://www.ncbi.nlm.nih.gov/pubmed/3076965>.

469. Bavinck JN, Tieben LM, Van der Woude FJ, et al. Prevention of skin cancer and reduction of keratotic skin lesions during acitretin therapy in renal transplant recipients: a double-blind, placebo-controlled study. *J Clin Oncol* 1995;13:1933-1938. Available at:

<https://www.ncbi.nlm.nih.gov/pubmed/7636533>.

470. Gibson GE, O'Grady A, Kay EW, Murphy GM. Low-dose retinoid therapy for chemoprophylaxis of skin cancer in renal transplant

recipients. *J Eur Acad Dermatol Venereol* 1998;10:42-47. Available at: <https://www.ncbi.nlm.nih.gov/pubmed/9552756>.

471. McKenna DB, Murphy GM. Skin cancer chemoprophylaxis in renal transplant recipients: 5 years of experience using low-dose acitretin. *Br J Dermatol* 1999;140:656-660. Available at:

<https://www.ncbi.nlm.nih.gov/pubmed/10233316>.

472. George R, Weightman W, Russ GR, et al. Acitretin for chemoprevention of non-melanoma skin cancers in renal transplant recipients. *Australas J Dermatol* 2002;43:269-273. Available at:

<http://www.ncbi.nlm.nih.gov/pubmed/12423433>.

473. de Sevaux RG, Smit JV, de Jong EM, et al. Acitretin treatment of premalignant and malignant skin disorders in renal transplant recipients: clinical effects of a randomized trial comparing two doses of acitretin. *J Am Acad Dermatol* 2003;49:407-412. Available at:

<https://www.ncbi.nlm.nih.gov/pubmed/12963902>.

474. Kraemer KH, DiGiovanna JJ, Moshell AN, et al. Prevention of skin cancer in xeroderma pigmentosum with the use of oral isotretinoin. *N Engl J Med* 1988;318:1633-1637. Available at:

<https://www.ncbi.nlm.nih.gov/pubmed/3287161>.

475. Nijsten TE, Stern RS. Oral retinoid use reduces cutaneous squamous cell carcinoma risk in patients with psoriasis treated with psoralen-UVA: a nested cohort study. *J Am Acad Dermatol* 2003;49:644-650. Available at: <http://www.ncbi.nlm.nih.gov/pubmed/14512910>.

476. Moon TE, Levine N, Cartmel B, et al. Effect of retinol in preventing squamous cell skin cancer in moderate-risk subjects: a randomized, double-blind, controlled trial. Southwest Skin Cancer Prevention Study Group. *Cancer Epidemiol Biomarkers Prev* 1997;6:949-956. Available at: <https://www.ncbi.nlm.nih.gov/pubmed/9367069>.

477. Levine N, Moon TE, Cartmel B, et al. Trial of retinol and isotretinoin in skin cancer prevention: a randomized, double-blind, controlled trial. Southwest Skin Cancer Prevention Study Group. *Cancer Epidemiol*





# NCCN Guidelines Version 1.2024

## Squamous Cell Skin Cancer

Biomarkers Prev 1997;6:957-961. Available at:  
<https://www.ncbi.nlm.nih.gov/pubmed/9367070>.

478. Kadakia KC, Barton DL, Loprinzi CL, et al. Randomized controlled trial of acitretin versus placebo in patients at high-risk for basal cell or squamous cell carcinoma of the skin (North Central Cancer Treatment Group Study 969251). *Cancer* 2012;118:2128-2137. Available at:  
<http://www.ncbi.nlm.nih.gov/pubmed/21882176>.

479. Meyskens FL, Jr., Gilmartin E, Alberts DS, et al. Activity of isotretinoin against squamous cell cancers and preneoplastic lesions. *Cancer Treat Rep* 1982;66:1315-1319. Available at:  
<https://www.ncbi.nlm.nih.gov/pubmed/6211233>.

480. Prescribing information for isotretinoin capsules for oral use. 2019. Available at:  
[https://www.accessdata.fda.gov/drugsatfda\\_docs/label/2019/021951s013lbl.pdf](https://www.accessdata.fda.gov/drugsatfda_docs/label/2019/021951s013lbl.pdf). Accessed March 10, 2023.

481. Weinstock MA, Bingham SF, Digiovanna JJ, et al. Tretinoin and the prevention of keratinocyte carcinoma (Basal and squamous cell carcinoma of the skin): a veterans affairs randomized chemoprevention trial. *J Invest Dermatol* 2012;132:1583-1590. Available at:  
<http://www.ncbi.nlm.nih.gov/pubmed/22318383>.

482. Tang JY, Chiou AS, Mackay-Wiggan JM, et al. Tazarotene: randomized, double-blind, vehicle-controlled, and open-label concurrent trials for basal cell carcinoma prevention and therapy in patients with basal cell nevus syndrome. *Cancer Prev Res (Phila)* 2014;7:292-299. Available at: <https://www.ncbi.nlm.nih.gov/pubmed/24441673>.

483. Chen AC, Martin AJ, Choy B, et al. A Phase 3 Randomized Trial of Nicotinamide for Skin-Cancer Chemoprevention. *N Engl J Med* 2015;373:1618-1626. Available at:  
<http://www.ncbi.nlm.nih.gov/pubmed/26488693>.

484. Eide MJ, Weinstock MA, Dufresne RG, Jr., et al. Relationship of treatment delay with surgical defect size from keratinocyte carcinoma (basal cell carcinoma and squamous cell carcinoma of the skin). *J Invest*

*Dermatol* 2005;124:308-314. Available at:  
<https://www.ncbi.nlm.nih.gov/pubmed/15675948>.

485. Renzi C, Mastroeni S, Passarelli F, et al. Factors associated with large cutaneous squamous cell carcinomas. *J Am Acad Dermatol* 2010;63:404-411. Available at:  
<https://www.ncbi.nlm.nih.gov/pubmed/20598396>.

486. Diehl J, Choi YM, Liang LJ, Chiu M. Association Between Mohs Surgery Wait Times and Surgical Defect Size in Patients With Squamous Cell or Basal Cell Carcinoma of the Skin. *Dermatol Surg* 2015;41:768-774. Available at: <http://www.ncbi.nlm.nih.gov/pubmed/26050214>.

487. Wollina U, Bayyoud Y, Kronert C, Nowak A. Giant epithelial malignancies (Basal cell carcinoma, squamous cell carcinoma): a series of 20 tumors from a single center. *J Cutan Aesthet Surg* 2012;5:12-19. Available at: <http://www.ncbi.nlm.nih.gov/pubmed/22557850>.

488. Renzi C, Mastroeni S, Mannooranparampil TJ, et al. Delay in diagnosis and treatment of squamous cell carcinoma of the skin. *Acta Derm Venereol* 2010;90:595-601. Available at:  
<https://www.ncbi.nlm.nih.gov/pubmed/21057742>.

489. Kakagia D, Trypsiannis G, Karanikas M, et al. Patient-related delay in presentation for cutaneous squamous cell carcinoma. A cross-sectional clinical study. *Onkologie* 2013;36:738-744. Available at:  
<https://www.ncbi.nlm.nih.gov/pubmed/24356565>.

490. Amber KT, Bloom R, Abyaneh MY, et al. Patient Factors and Their Association with Nonmelanoma Skin Cancer Morbidity and the Performance of Self-skin Exams: A Cross-Sectional Study. *J Clin Aesthet Dermatol* 2016;9:16-22. Available at:  
<https://www.ncbi.nlm.nih.gov/pubmed/27878058>.

491. Janda M, Youl P, Neale R, et al. Clinical skin examination outcomes after a video-based behavioral intervention: analysis from a randomized clinical trial. *JAMA Dermatol* 2014;150:372-379. Available at:  
<https://www.ncbi.nlm.nih.gov/pubmed/24553807>.





# NCCN Guidelines Version 1.2024

## Squamous Cell Skin Cancer

492. Firooz A, Amin-Nejad R, Bouzari N, et al. Sun protection in Iranian kidney transplant recipients: knowledge, attitude and practice. *J Eur Acad Dermatol Venereol* 2007;21:754-757. Available at: <https://www.ncbi.nlm.nih.gov/pubmed/17567302>.

493. Thompson SC, Jolley D, Marks R. Reduction of solar keratoses by regular sunscreen use. *N Engl J Med* 1993;329:1147-1151. Available at: <https://www.ncbi.nlm.nih.gov/pubmed/8377777>.

494. van der Pols JC, Williams GM, Pandeya N, et al. Prolonged prevention of squamous cell carcinoma of the skin by regular sunscreen use. *Cancer Epidemiol Biomarkers Prev* 2006;15:2546-2548. Available at: <http://www.ncbi.nlm.nih.gov/pubmed/17132769>.

495. Green A, Williams G, Neale R, et al. Daily sunscreen application and betacarotene supplementation in prevention of basal-cell and squamous-cell carcinomas of the skin: a randomised controlled trial. *Lancet* 1999;354:723-729. Available at: <http://www.ncbi.nlm.nih.gov/pubmed/10475183>.

496. Ulrich C, Jurgensen JS, Degen A, et al. Prevention of non-melanoma skin cancer in organ transplant patients by regular use of a sunscreen: a 24 months, prospective, case-control study. *Br J Dermatol* 2009;161 Suppl 3:78-84. Available at: <http://www.ncbi.nlm.nih.gov/pubmed/19775361>.

497. Goldenberg A, Nguyen BT, Jiang SI. Knowledge, understanding, and use of preventive strategies against nonmelanoma skin cancer in healthy and immunosuppressed individuals undergoing Mohs surgery. *Dermatol Surg* 2014;40:93-100. Available at: <http://www.ncbi.nlm.nih.gov/pubmed/24354730>.

498. Borghi A, Corazza M, Battaglia Y, et al. What Is the Key to Improving Renal Transplant Recipients' Awareness of Skin Cancer Risk? *Dermatology* 2016;232:715-720. Available at: <https://www.ncbi.nlm.nih.gov/pubmed/28343227>.

499. Wohik IM, Philipsen PA, Wulf HC. Factors associated with cessation of sunbed use among Danish women. *Photodermatol*

*Photoimmunol Photomed* 2016;32:191-198. Available at: <https://www.ncbi.nlm.nih.gov/pubmed/27084577>.

500. Fischer AH, Wang TS, Yenokyan G, et al. Sunburn and sun-protective behaviors among adults with and without previous nonmelanoma skin cancer (NMSC): A population-based study. *J Am Acad Dermatol* 2016;75:371-379 e375. Available at: <https://www.ncbi.nlm.nih.gov/pubmed/27198078>.

501. Wiznia L, Dai F, Chagpar AB. Do non-melanoma skin cancer survivors use tanning beds less often than the general public? *Dermatol Online J* 2016;22. Available at: <https://www.ncbi.nlm.nih.gov/pubmed/27617935>.

502. Girgis A, Sanson-Fisher RW, Watson A. A workplace intervention for increasing outdoor workers' use of solar protection. *Am J Public Health* 1994;84:77-81. Available at: <https://www.ncbi.nlm.nih.gov/pubmed/8279616>.

503. Robinson JK, Friedewald JJ, Desai A, Gordon EJ. Response Across the Health-Literacy Spectrum of Kidney Transplant Recipients to a Sun-Protection Education Program Delivered on Tablet Computers: Randomized Controlled Trial. *JMIR Cancer* 2015;1:e8. Available at: <https://www.ncbi.nlm.nih.gov/pubmed/28410176>.

504. Loescher LJ, Hansen C, Hepworth JT, et al. A preliminary study of a video intervention to inform solid organ transplant recipients about skin cancer. *Transplant Proc* 2013;45:3187-3189. Available at: <https://www.ncbi.nlm.nih.gov/pubmed/23747188>.

505. Tavadia S, Dawn G, Payne C, et al. Skin-cancer awareness in Scottish cardiac transplant recipients. *Clin Exp Dermatol* 2006;31:354-357. Available at: <https://www.ncbi.nlm.nih.gov/pubmed/16681574>.

506. Ismail F, Mitchell L, Casabonne D, et al. Specialist dermatology clinics for organ transplant recipients significantly improve compliance with photoprotection and levels of skin cancer awareness. *Br J Dermatol* 2006;155:916-925. Available at: <https://www.ncbi.nlm.nih.gov/pubmed/17034519>.



## NCCN Guidelines Version 1.2024 Squamous Cell Skin Cancer

507. Seite S, Del Marmol V, Moyal D, Friedman AJ. Public primary and secondary skin cancer prevention, perceptions and knowledge: an international cross-sectional survey. *J Eur Acad Dermatol Venereol* 2017;31:815-820. Available at: <https://www.ncbi.nlm.nih.gov/pubmed/28045207>.

508. Clowers-Webb HE, Christenson LJ, Phillips PK, et al. Educational outcomes regarding skin cancer in organ transplant recipients: Randomized intervention of intensive vs standard education. *Arch Dermatol* 2006;142:712-718. Available at: <http://www.ncbi.nlm.nih.gov/pubmed/16785373>.

509. Kim NN, Boone SL, Ortiz S, et al. Squamous cell carcinoma in solid organ transplant recipients: influences on perception of risk and optimal time to provide education. *Arch Dermatol* 2009;145:1196-1197. Available at: <https://www.ncbi.nlm.nih.gov/pubmed/19841415>.

510. Robinson JK, Friedewald JJ, Desai A, Gordon EJ. A Randomized Controlled Trial of a Mobile Medical App for Kidney Transplant Recipients: Effect on Use of Sun Protection. *Transplant Direct* 2016;2. Available at: <https://www.ncbi.nlm.nih.gov/pubmed/26900599>.

511. Robinson JK, Turrisi R, Mallett KA, et al. Efficacy of an educational intervention with kidney transplant recipients to promote skin self-examination for squamous cell carcinoma detection. *Arch Dermatol* 2011;147:689-695. Available at: <https://www.ncbi.nlm.nih.gov/pubmed/21339418>.